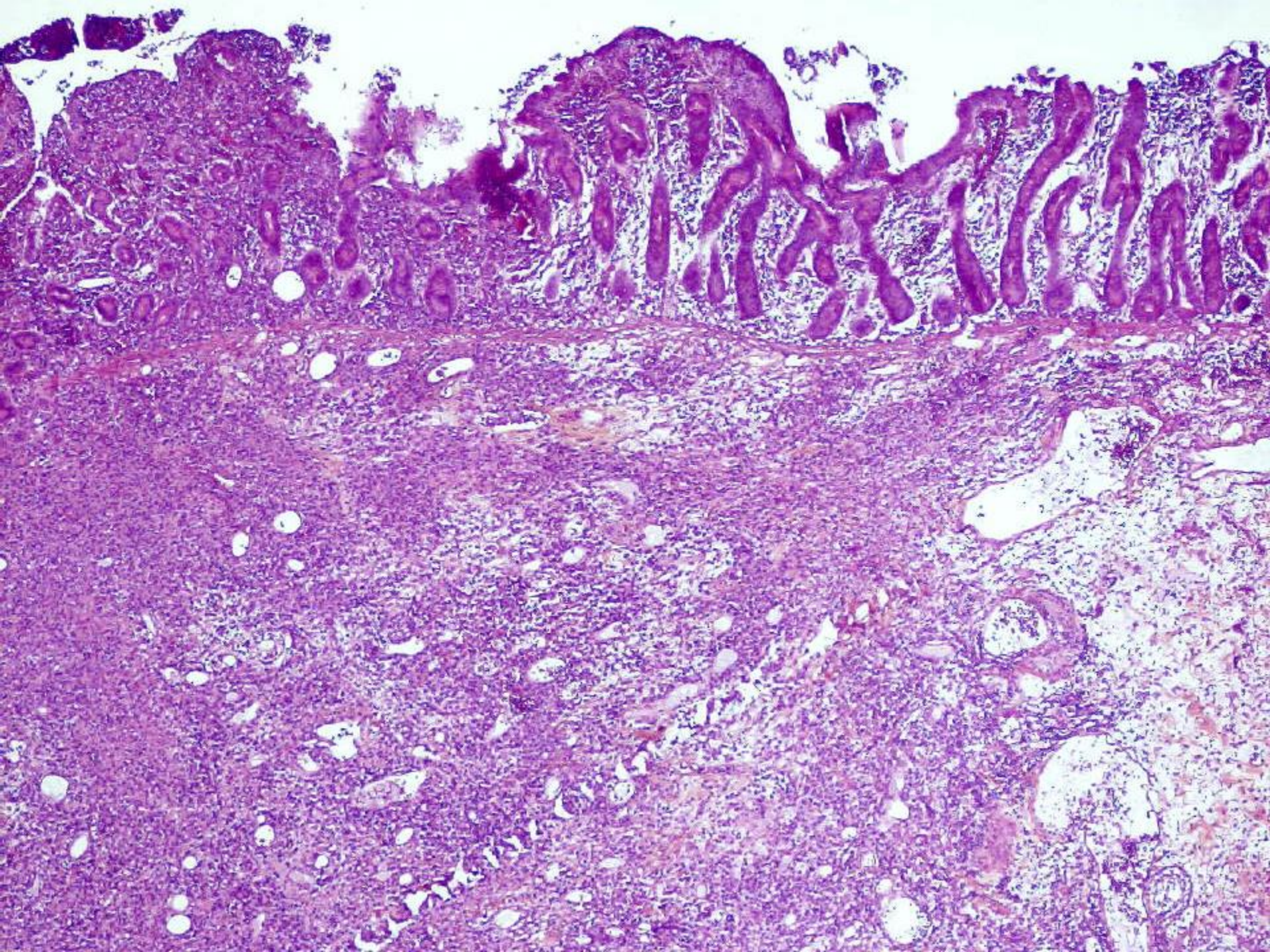
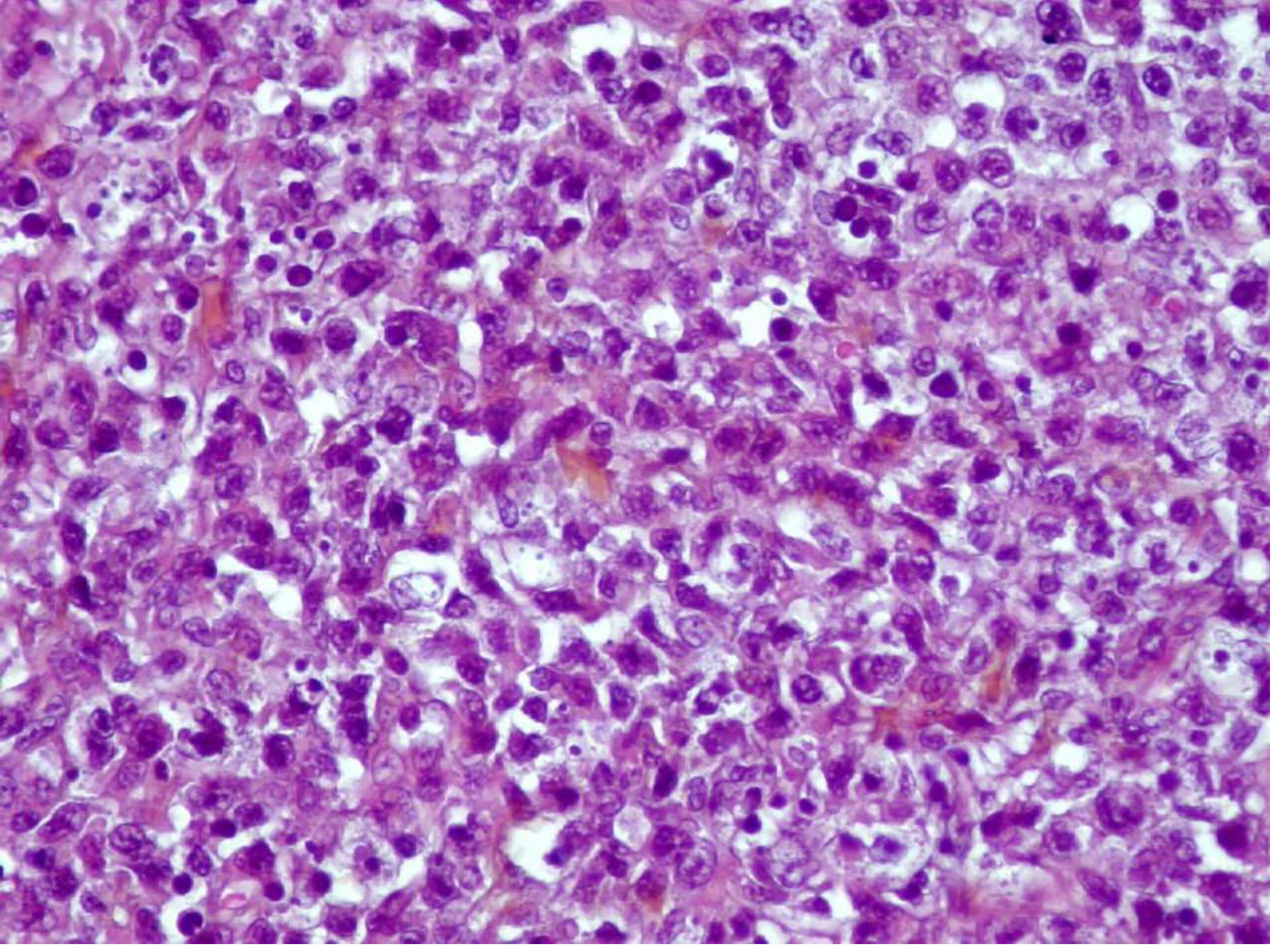
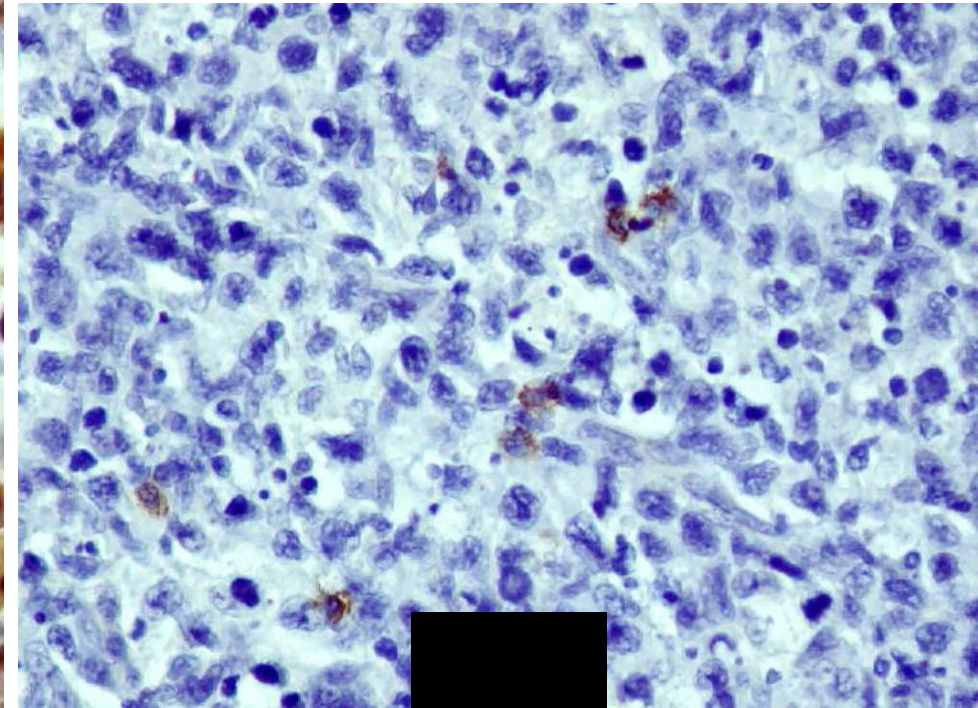
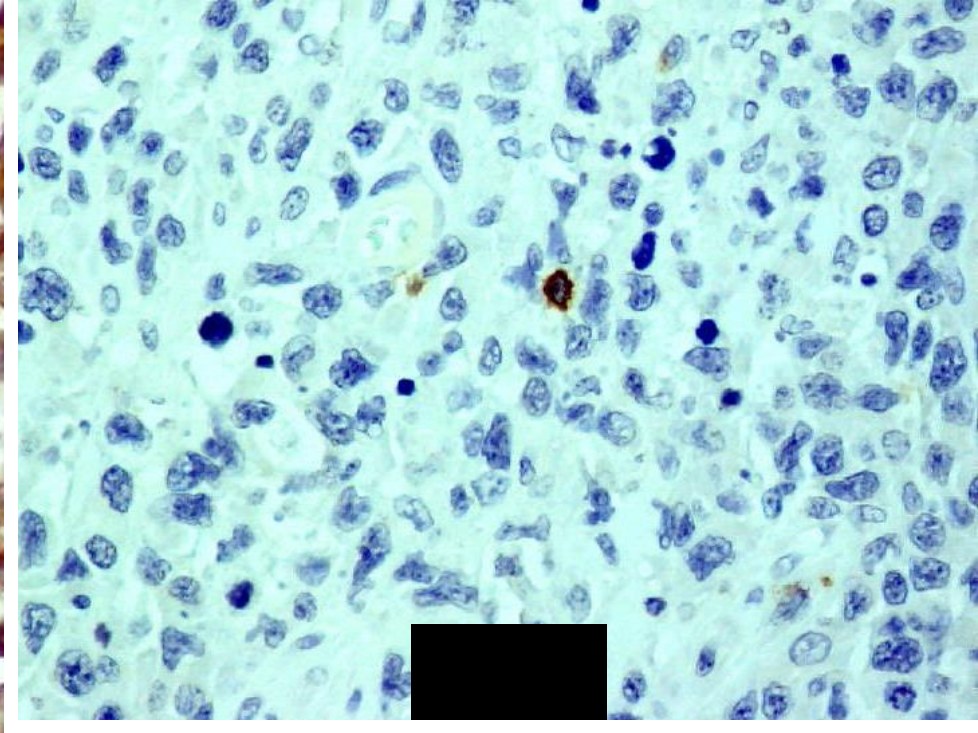
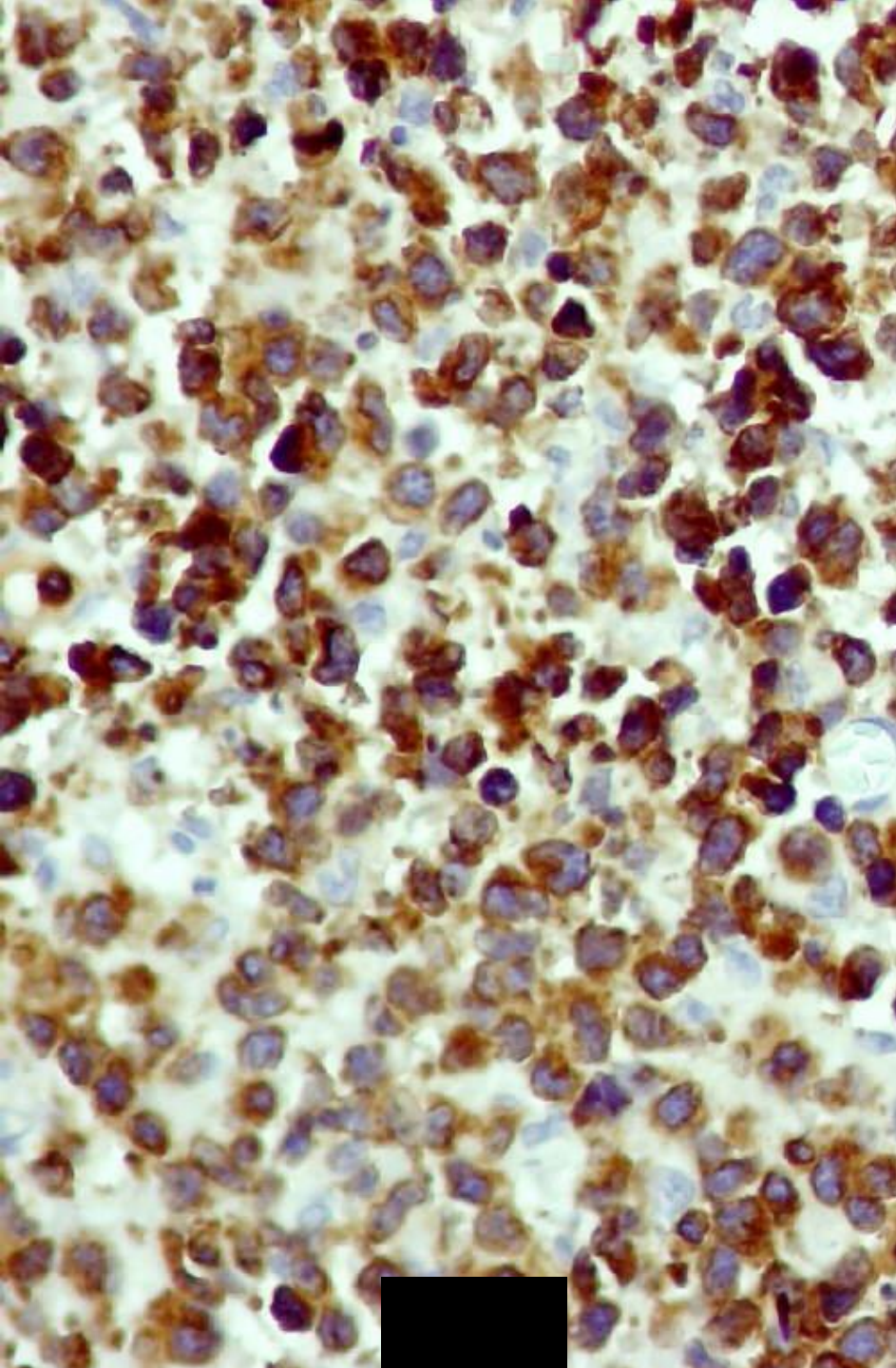


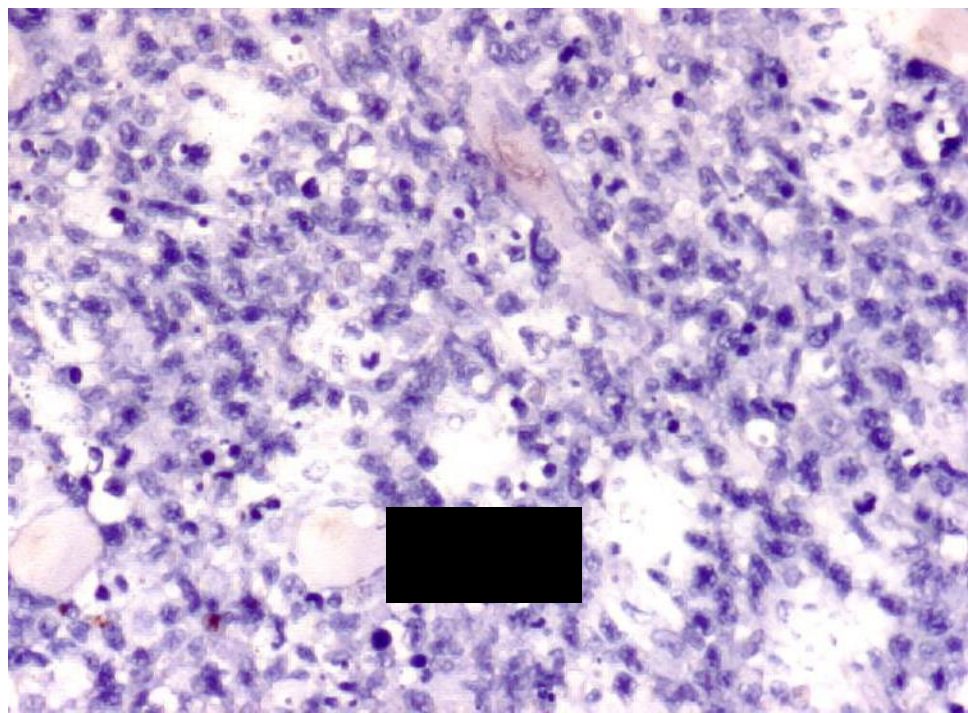
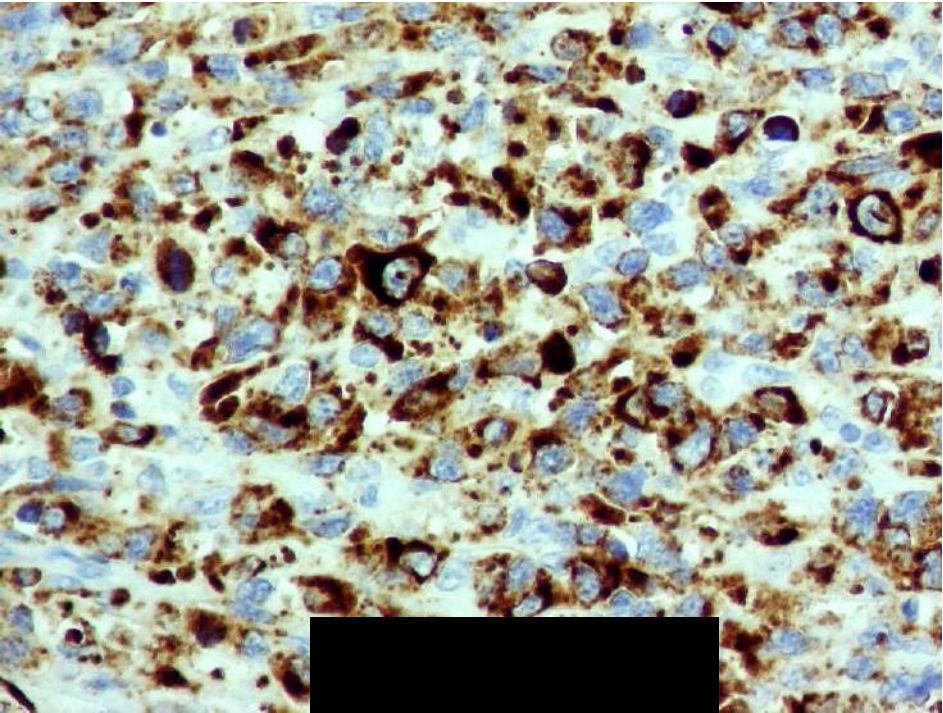
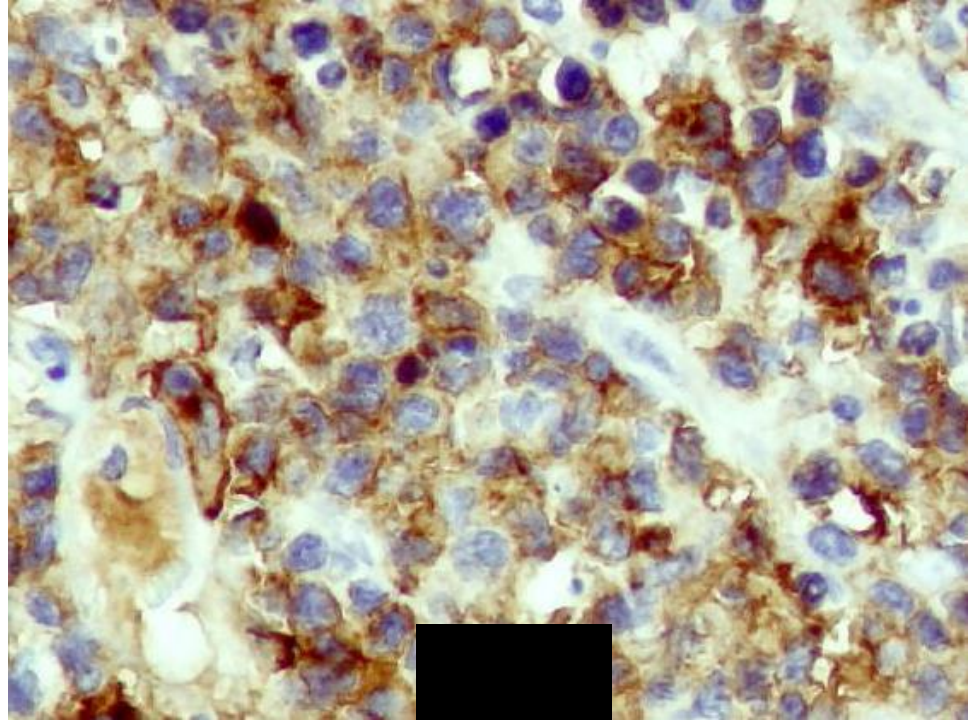
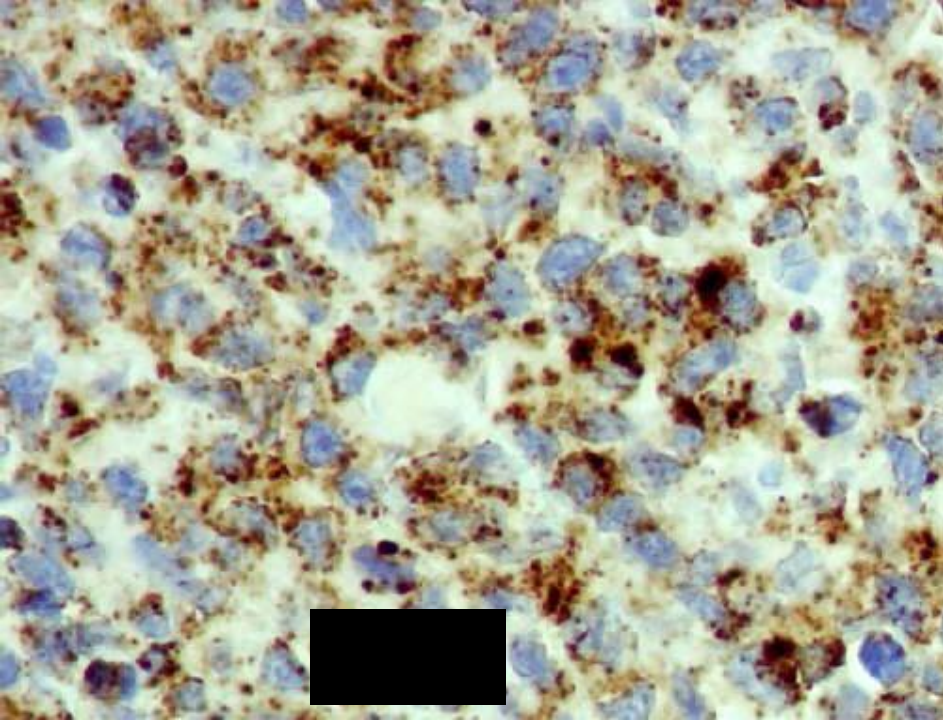
Cas n° 4

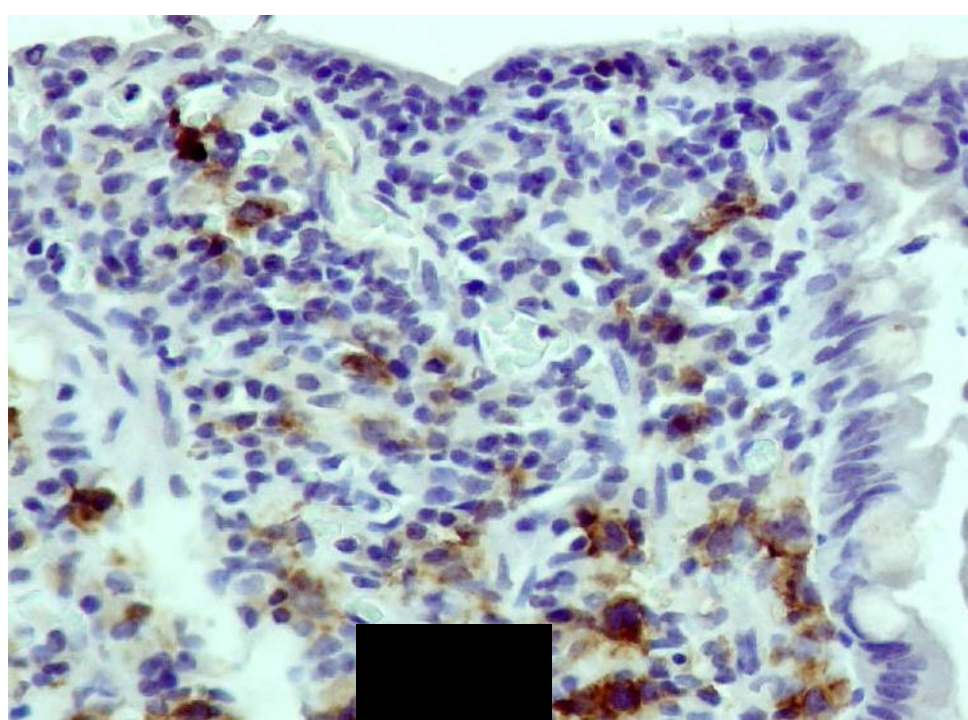
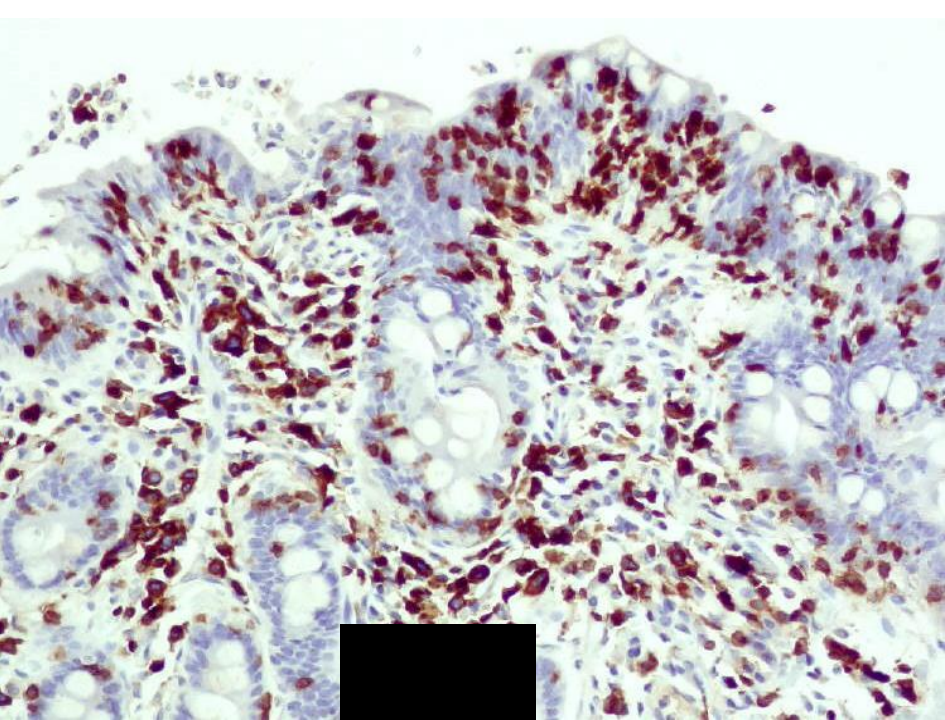
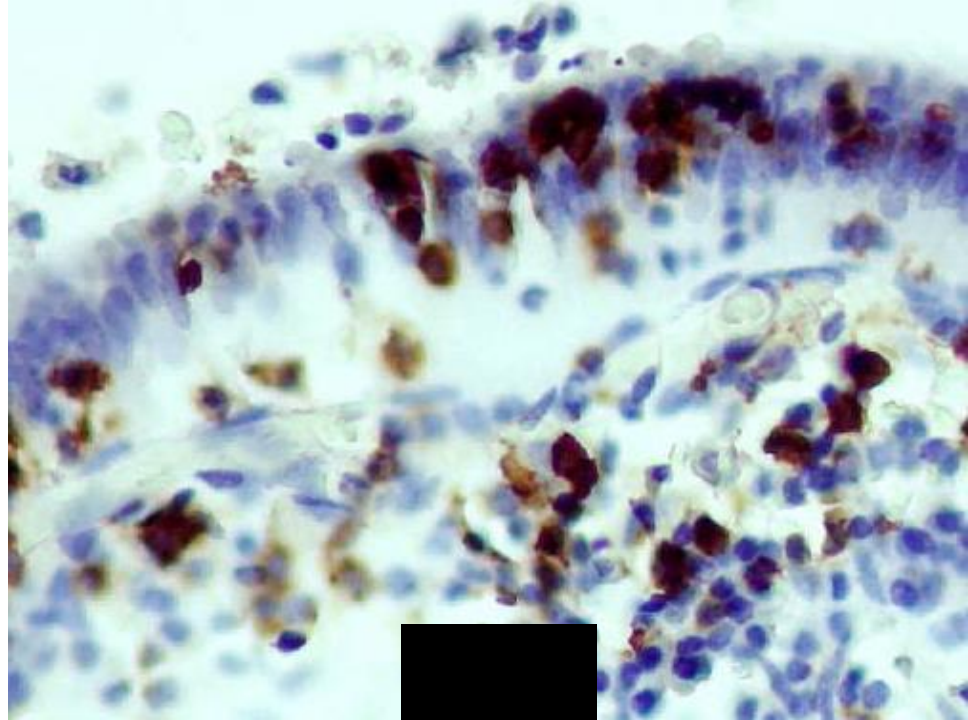
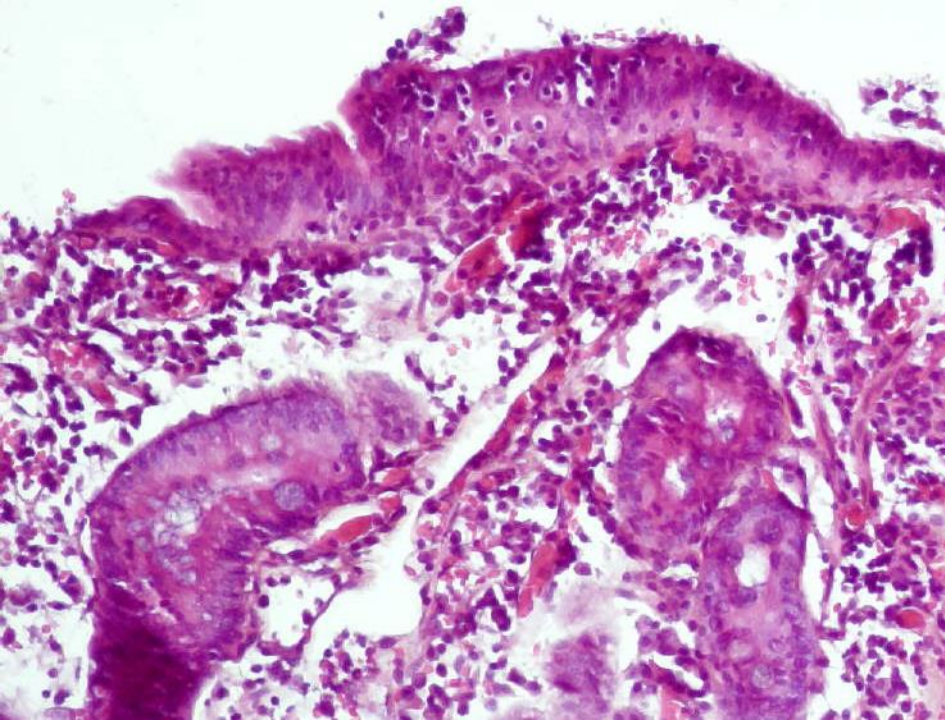
**Lymphome T intestinal développé sur
une maladie cœliaque (ETL)**











Cas n° 4

**Lymphome à cellules T, associé
à une entéropathie (EATL)**