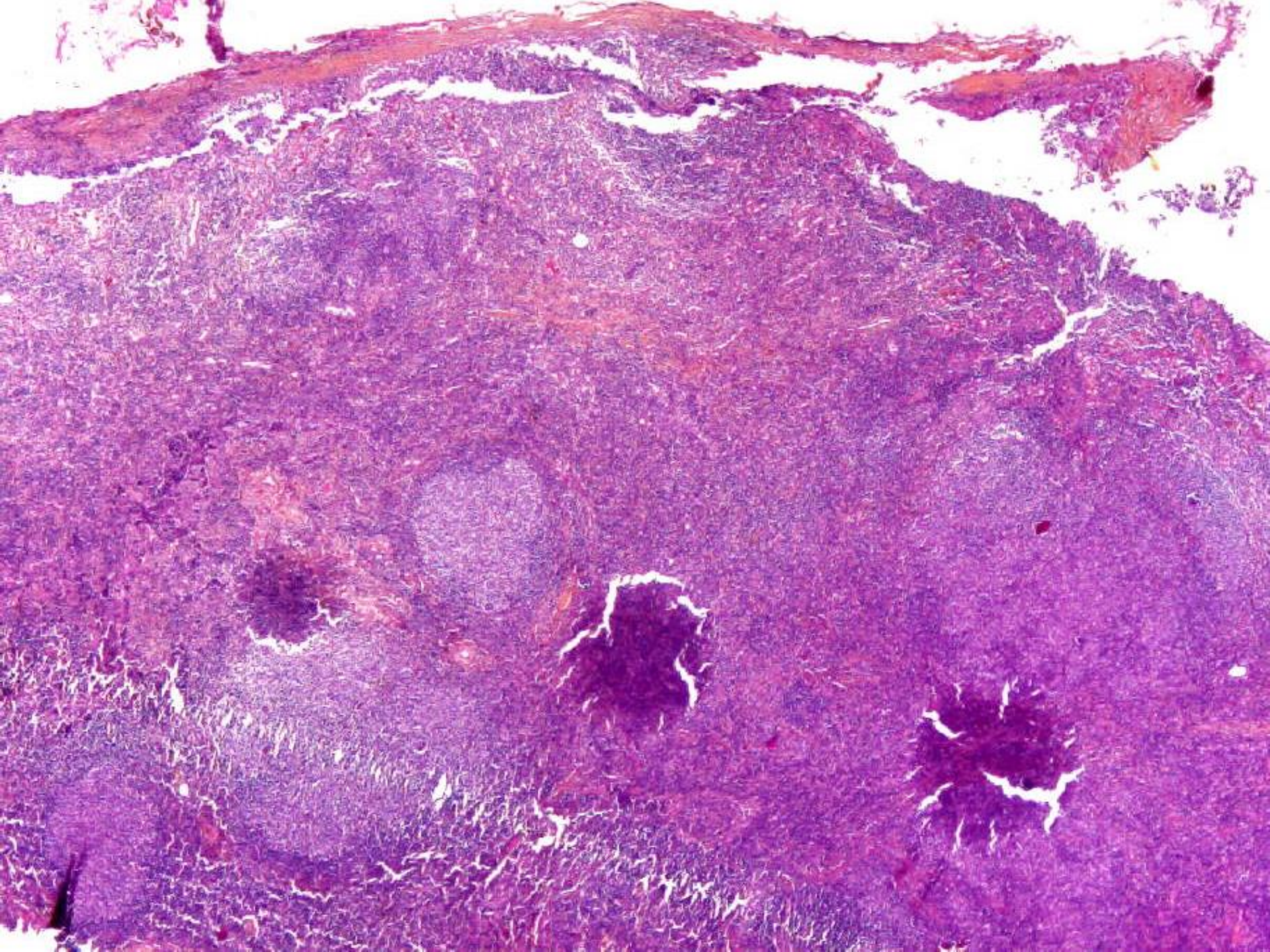
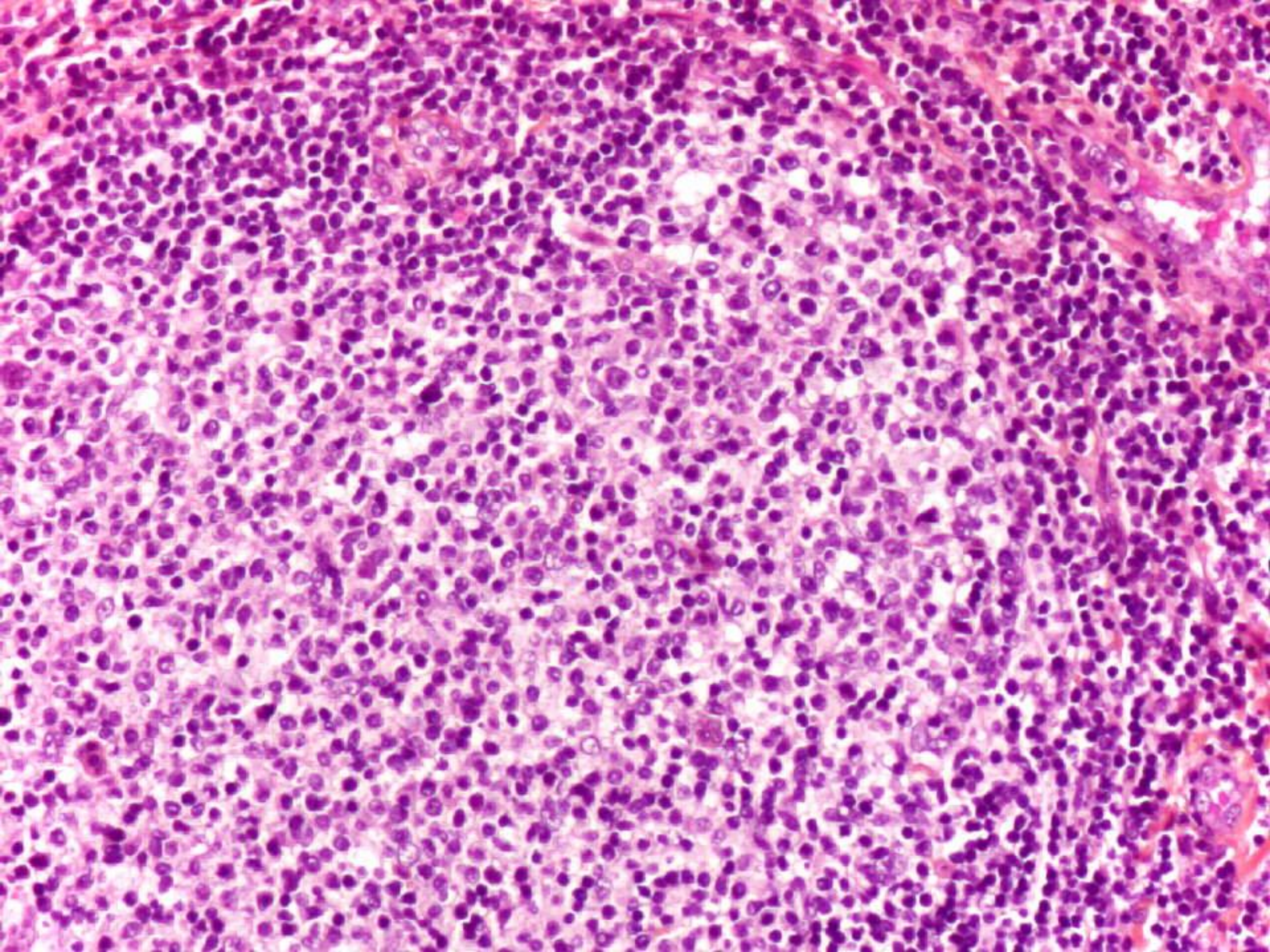
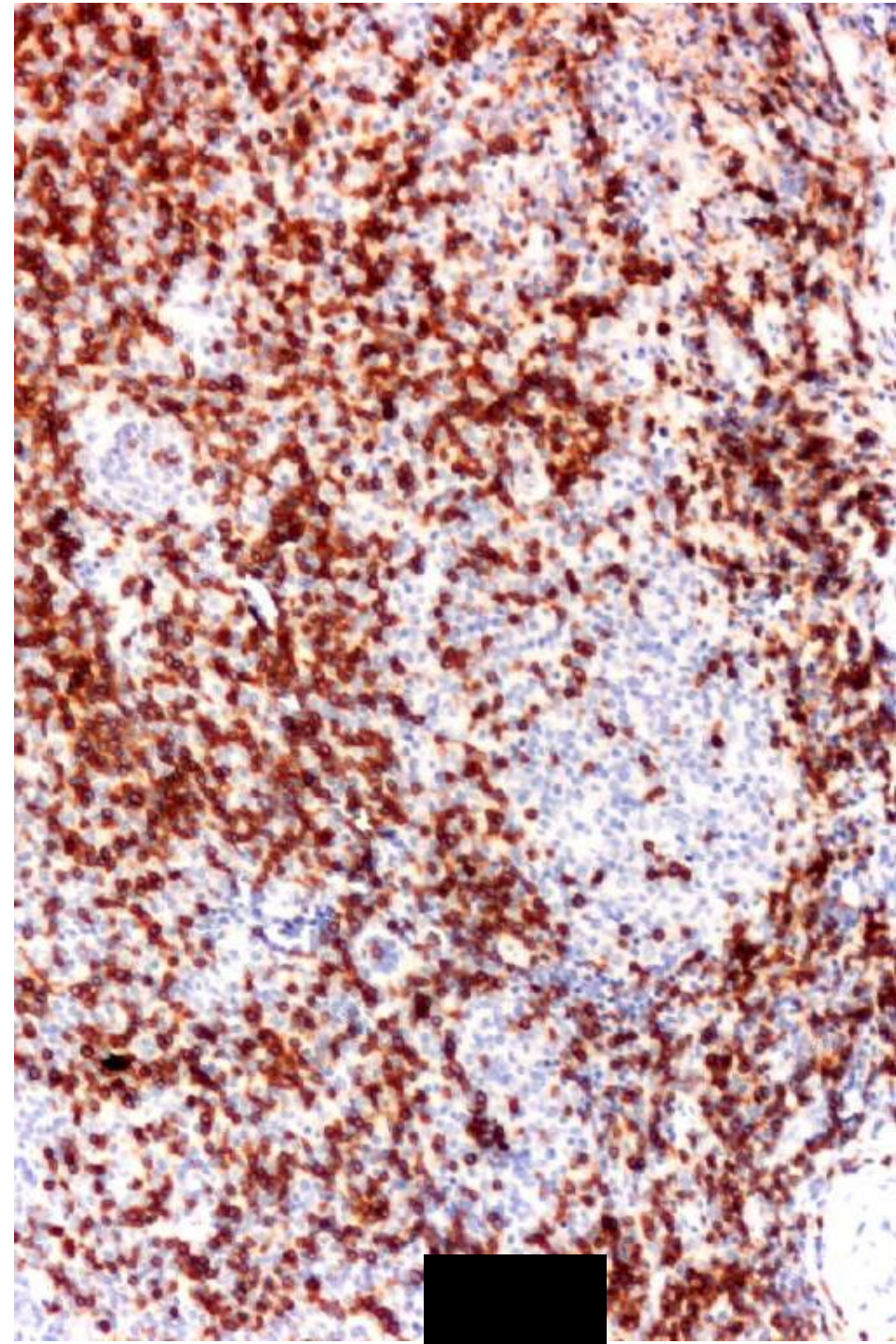


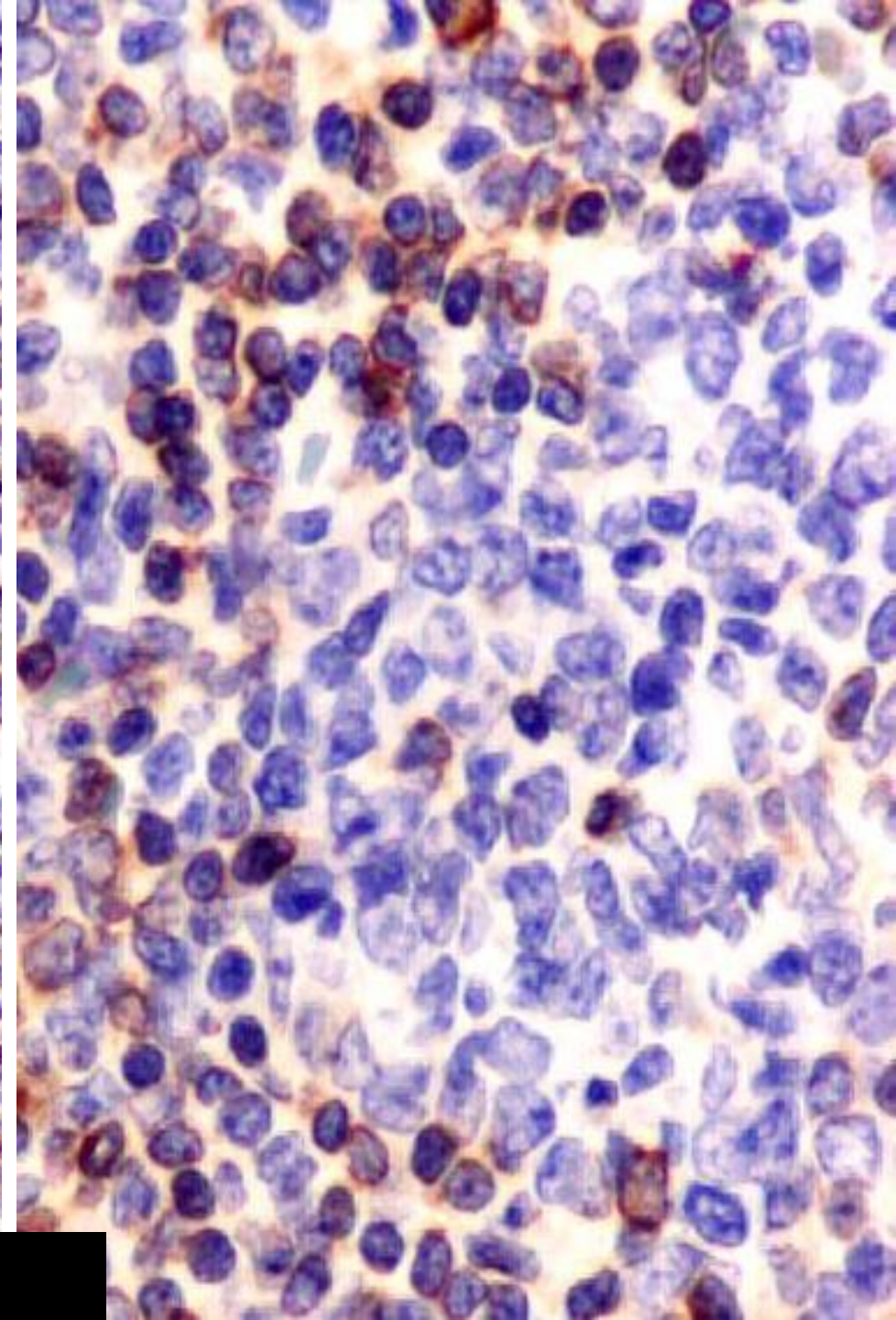
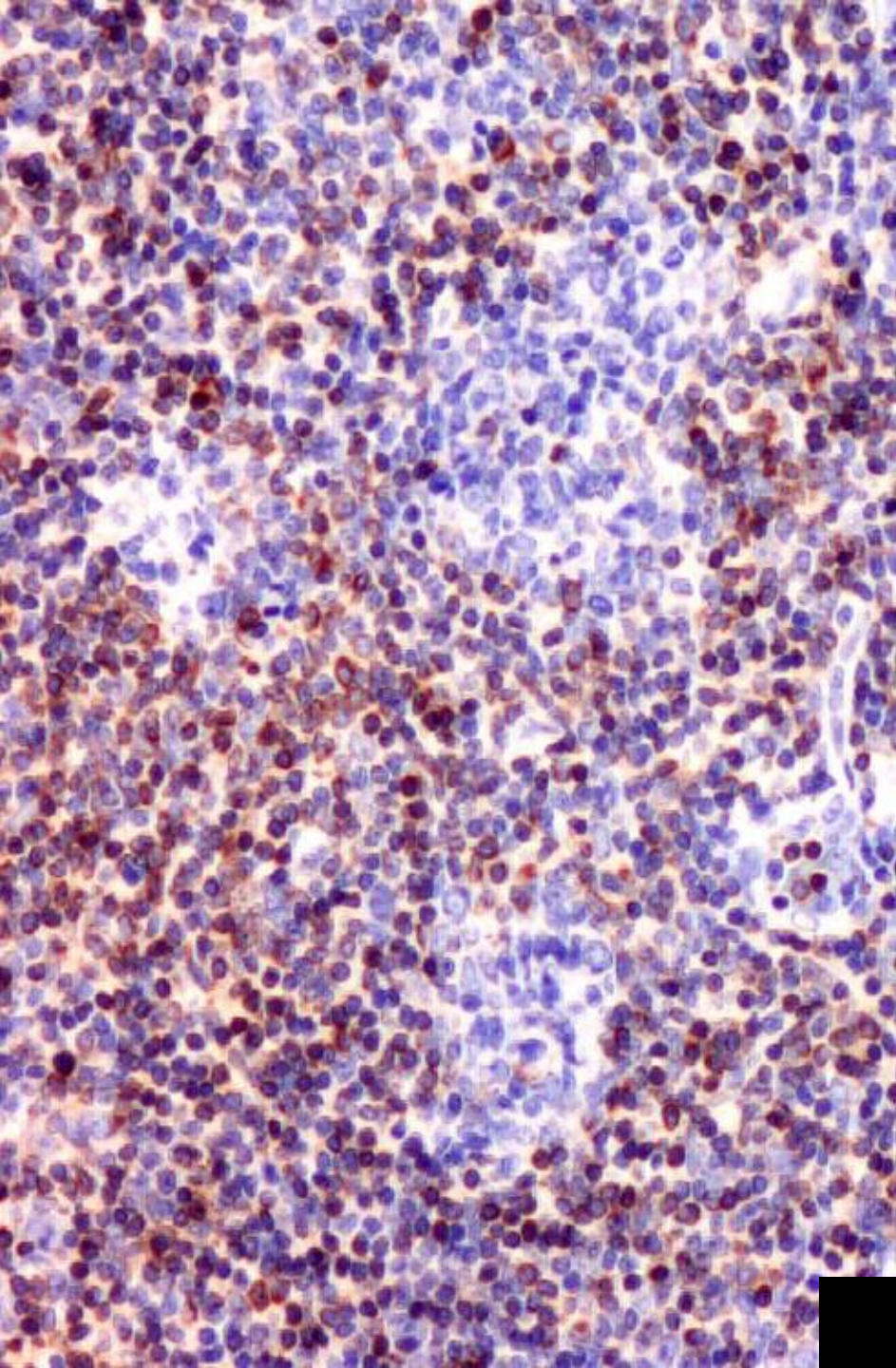
Cas n° 16

**Transformation progressive des
centres germinatifs**









Cas n° 16

- **Ganglion d'allure réactionnelle ?**
- **L Folliculaire débutant ?? (t(14;18) non contributive)**
- **Transformation progressive des centres germinatifs?**

- **Nouveaux prélèvements**