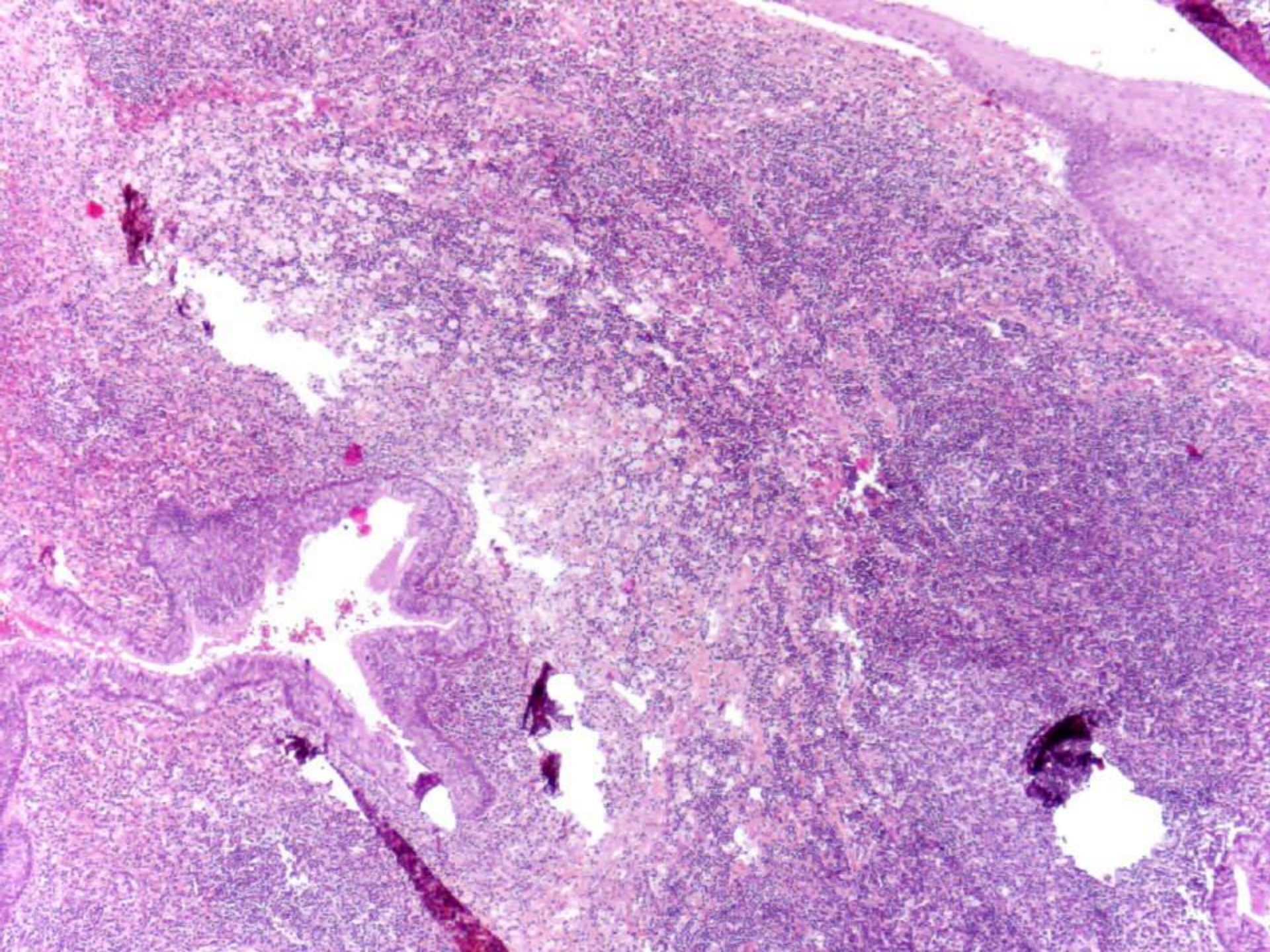
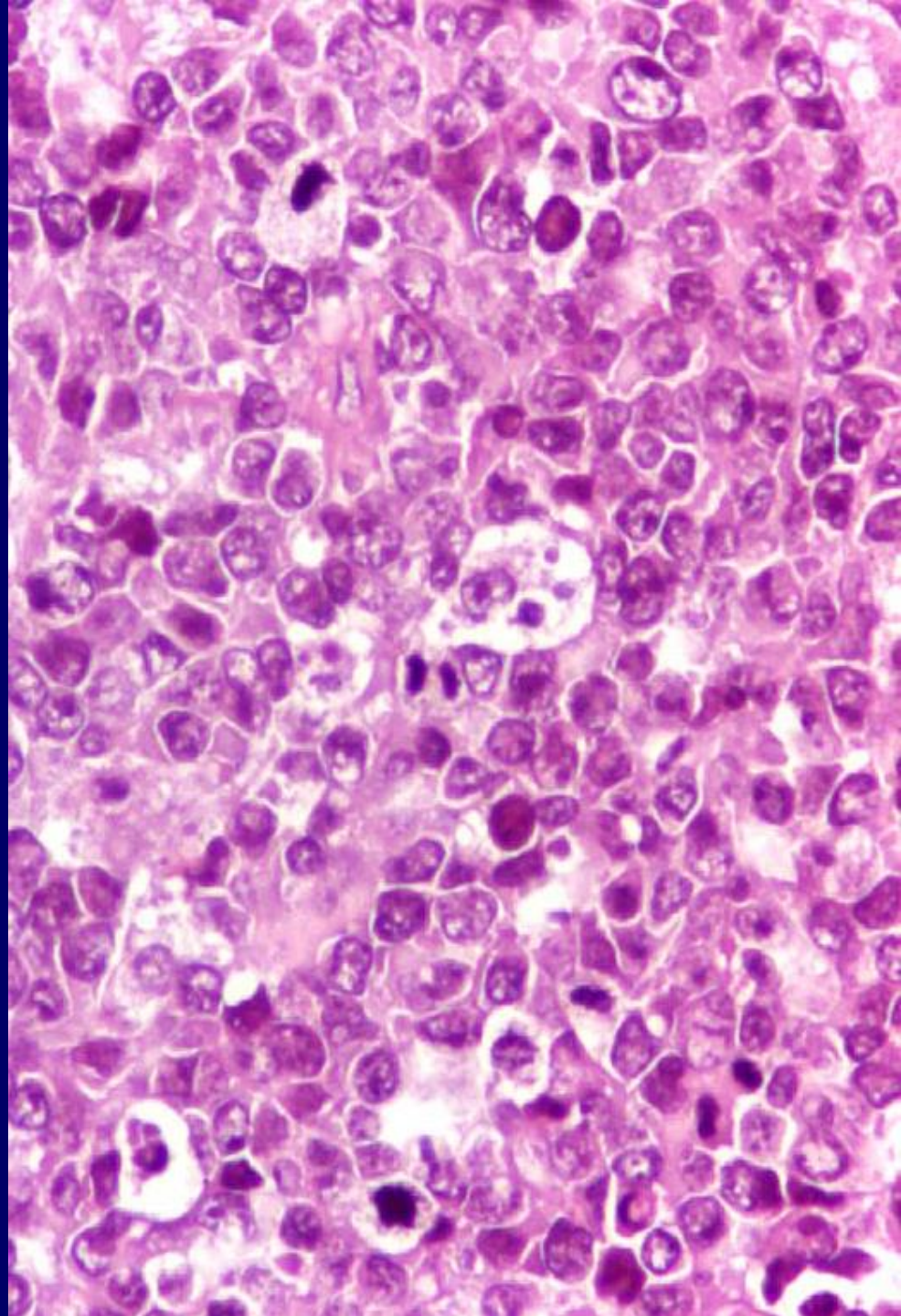
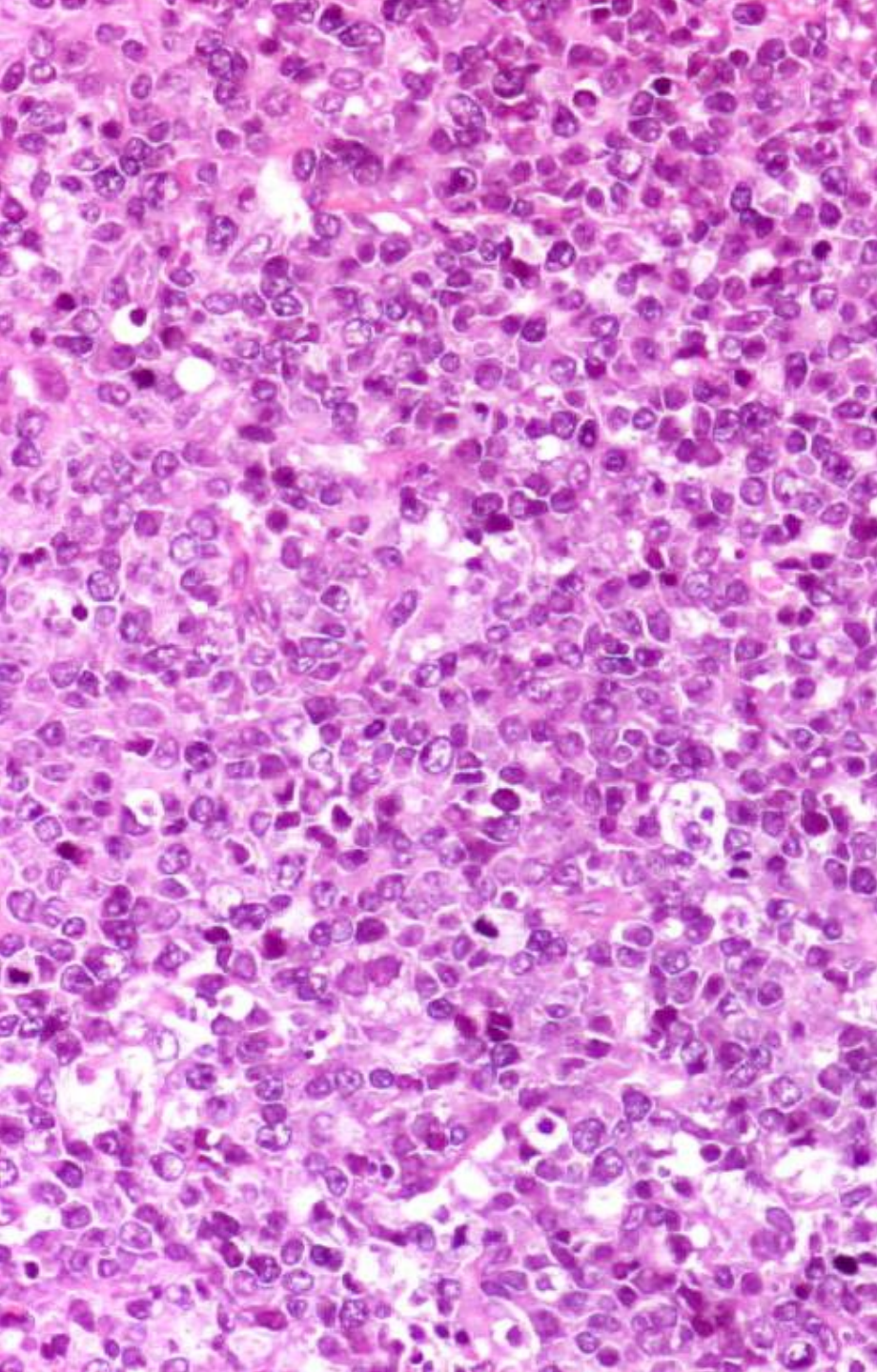


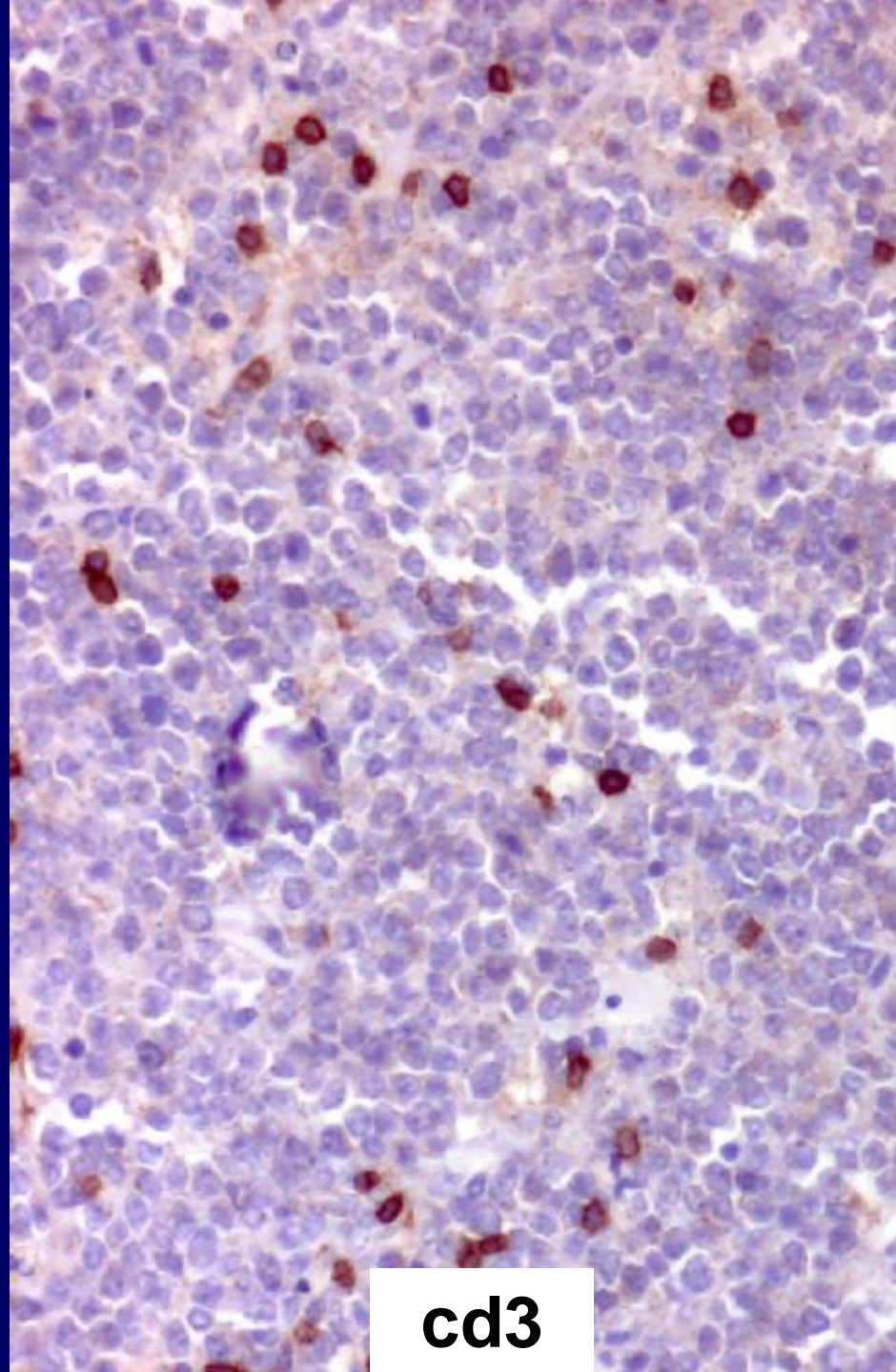
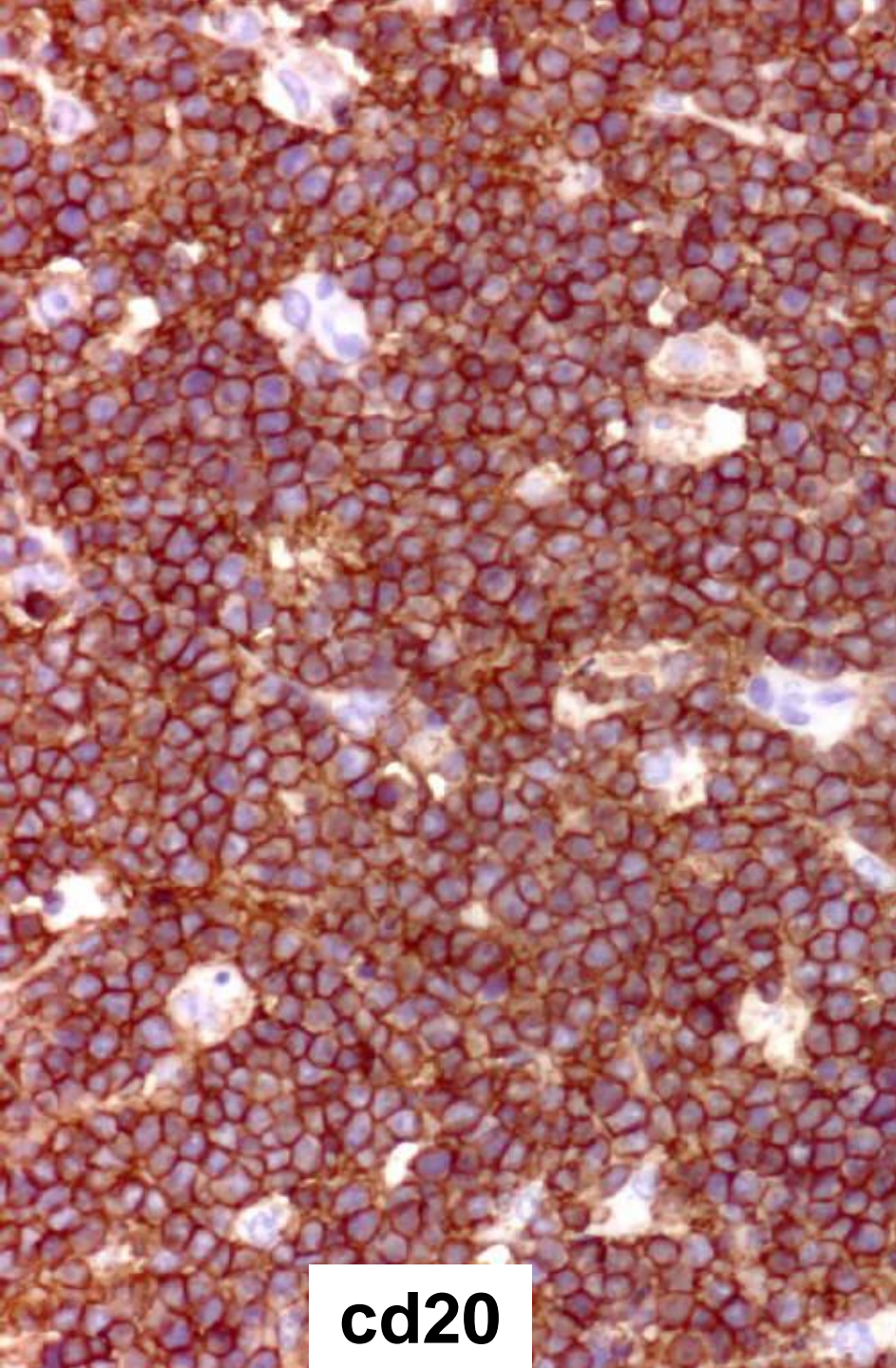
N° 18

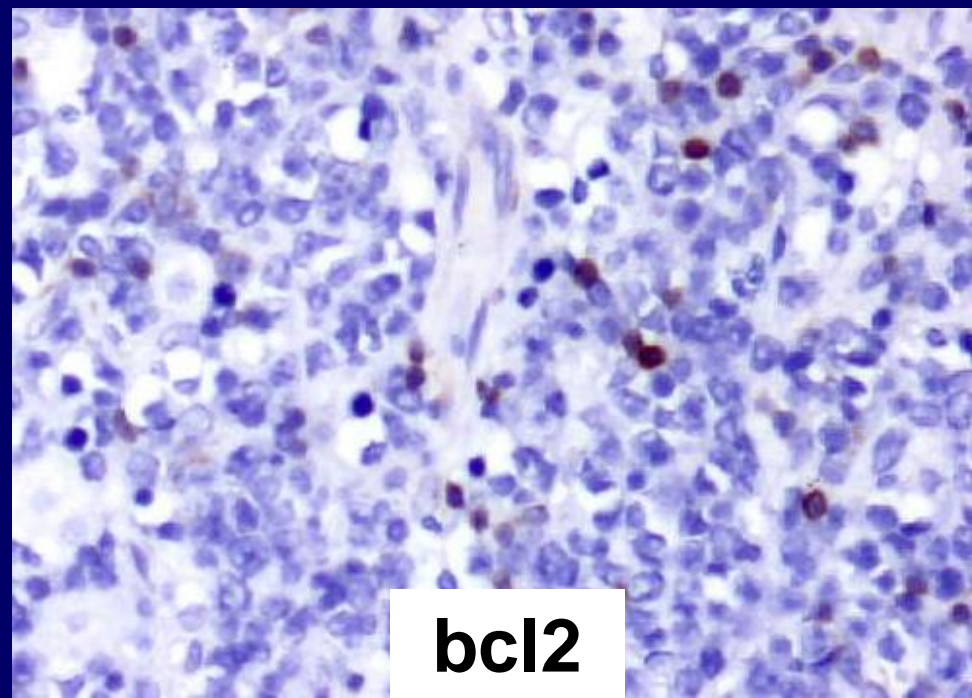
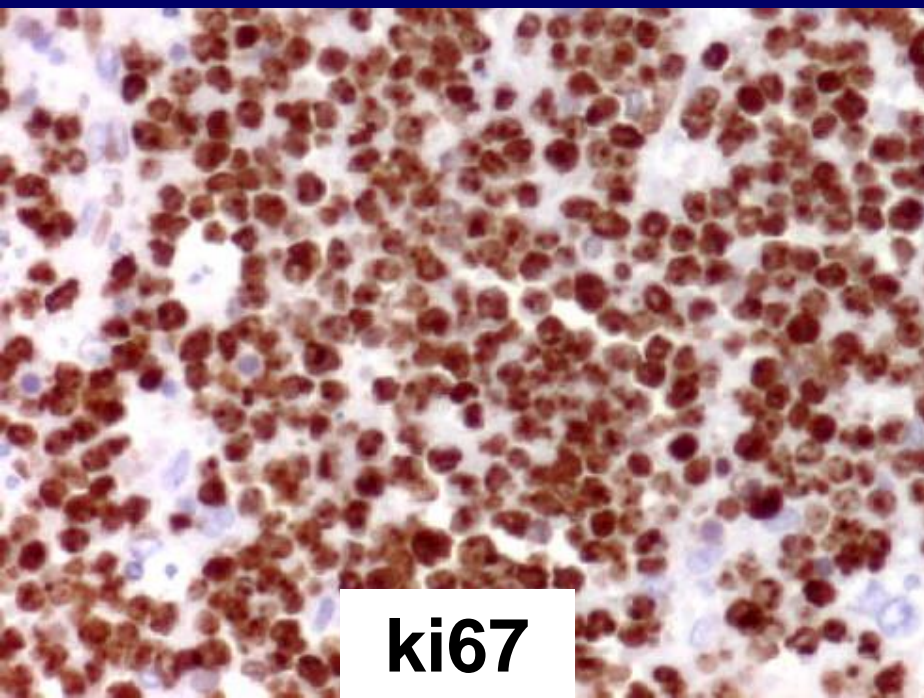
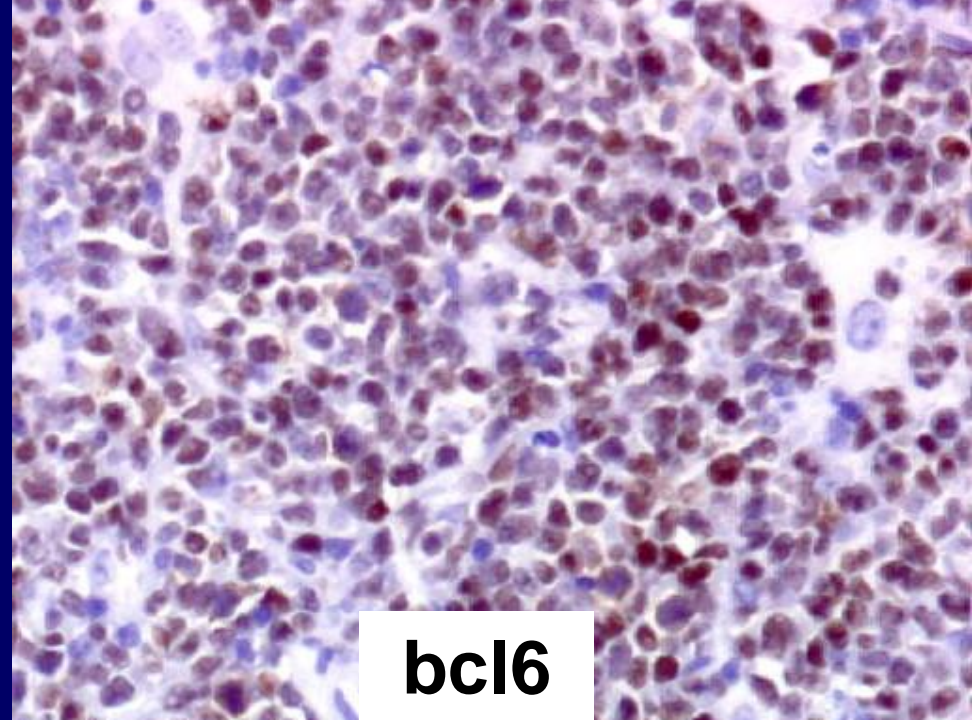
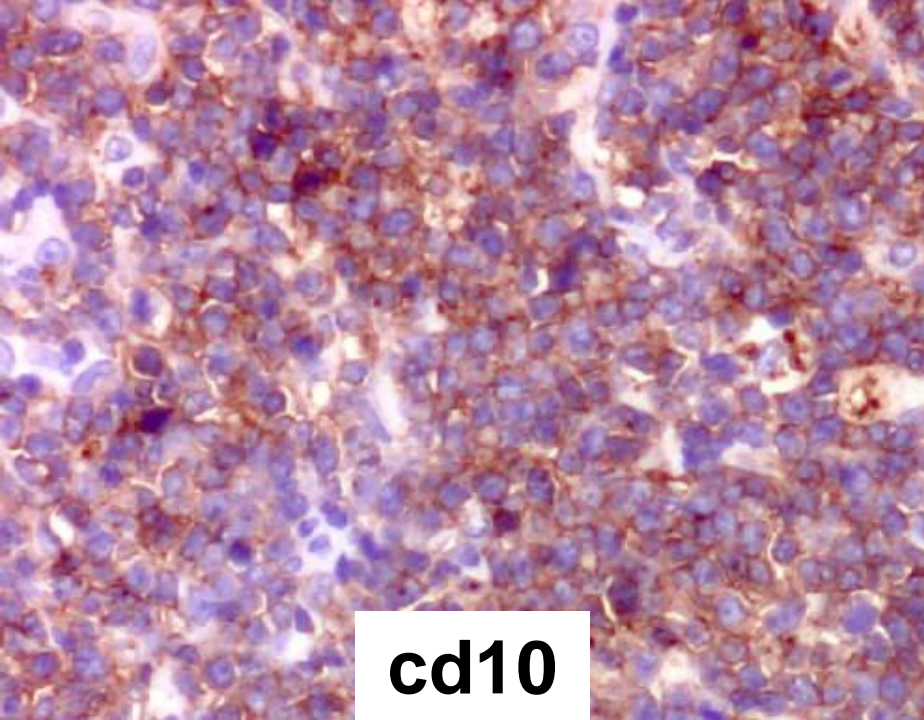
Sfax


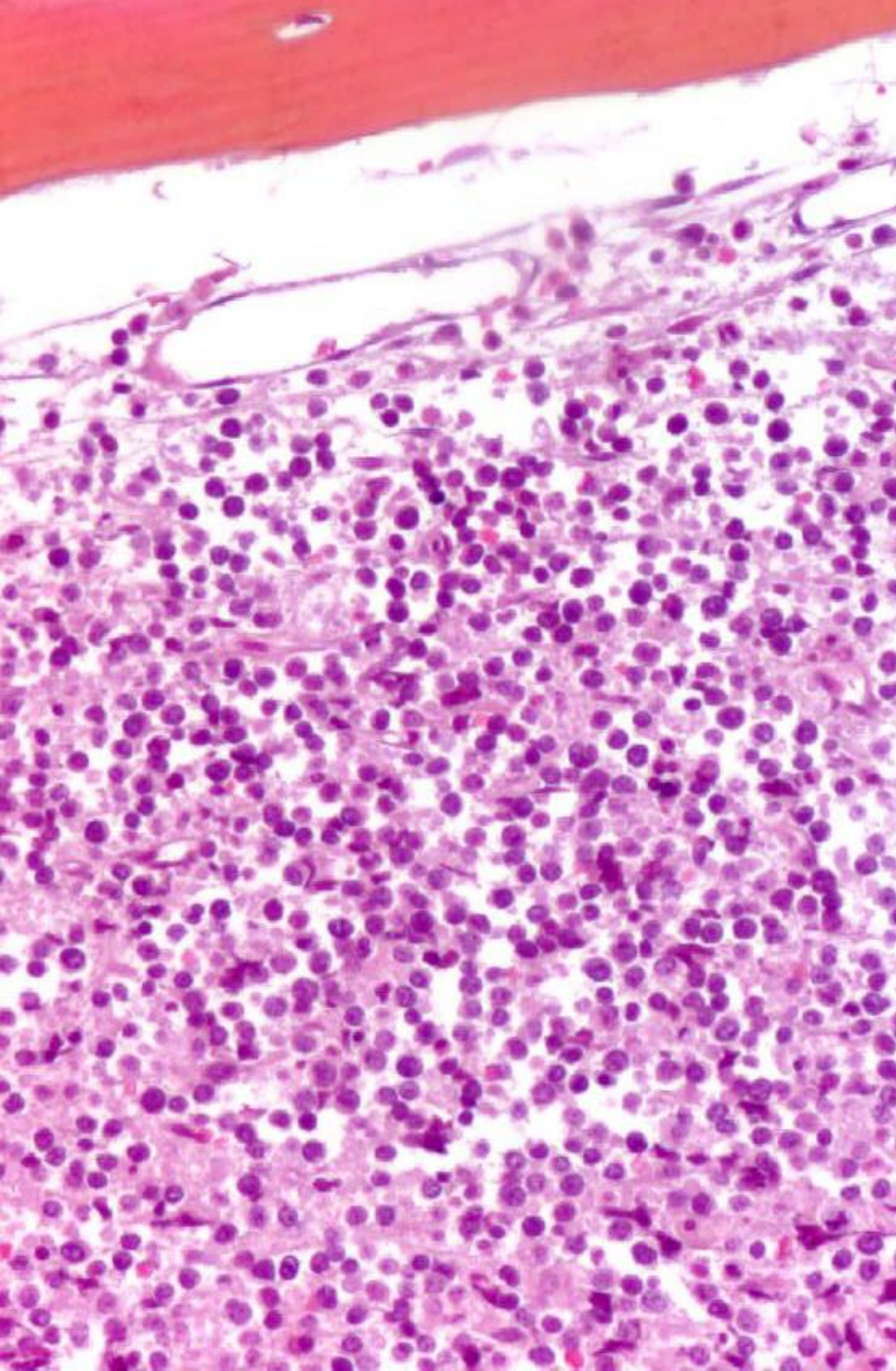
- **Garçon, 12 ans**
- **Obstruction nasale, tumeur du cavum biopsiée**
- **BM**



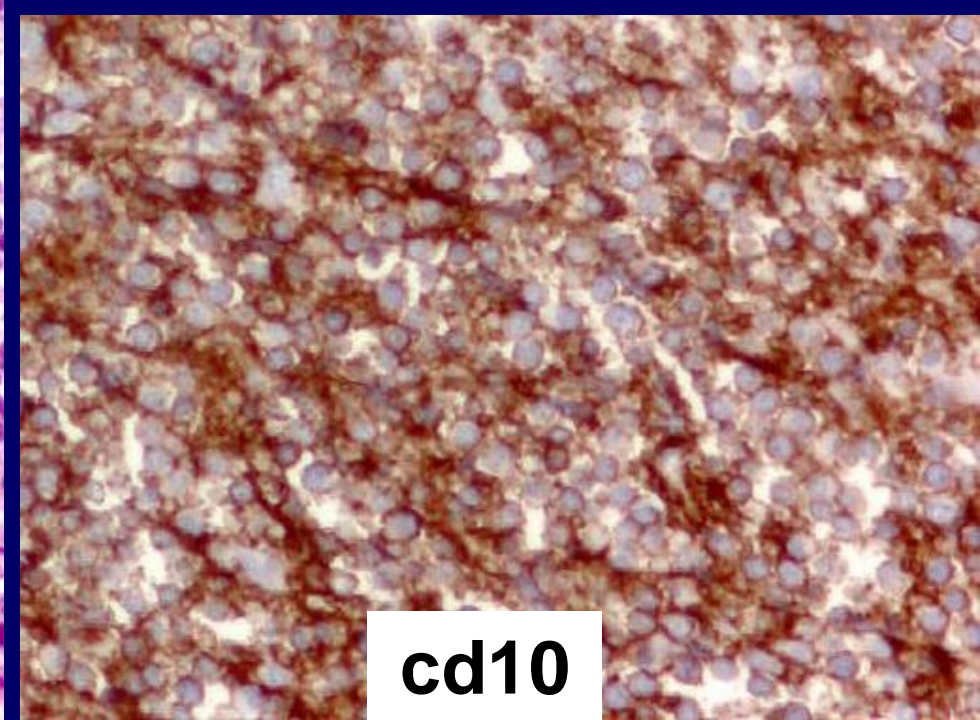








cd20



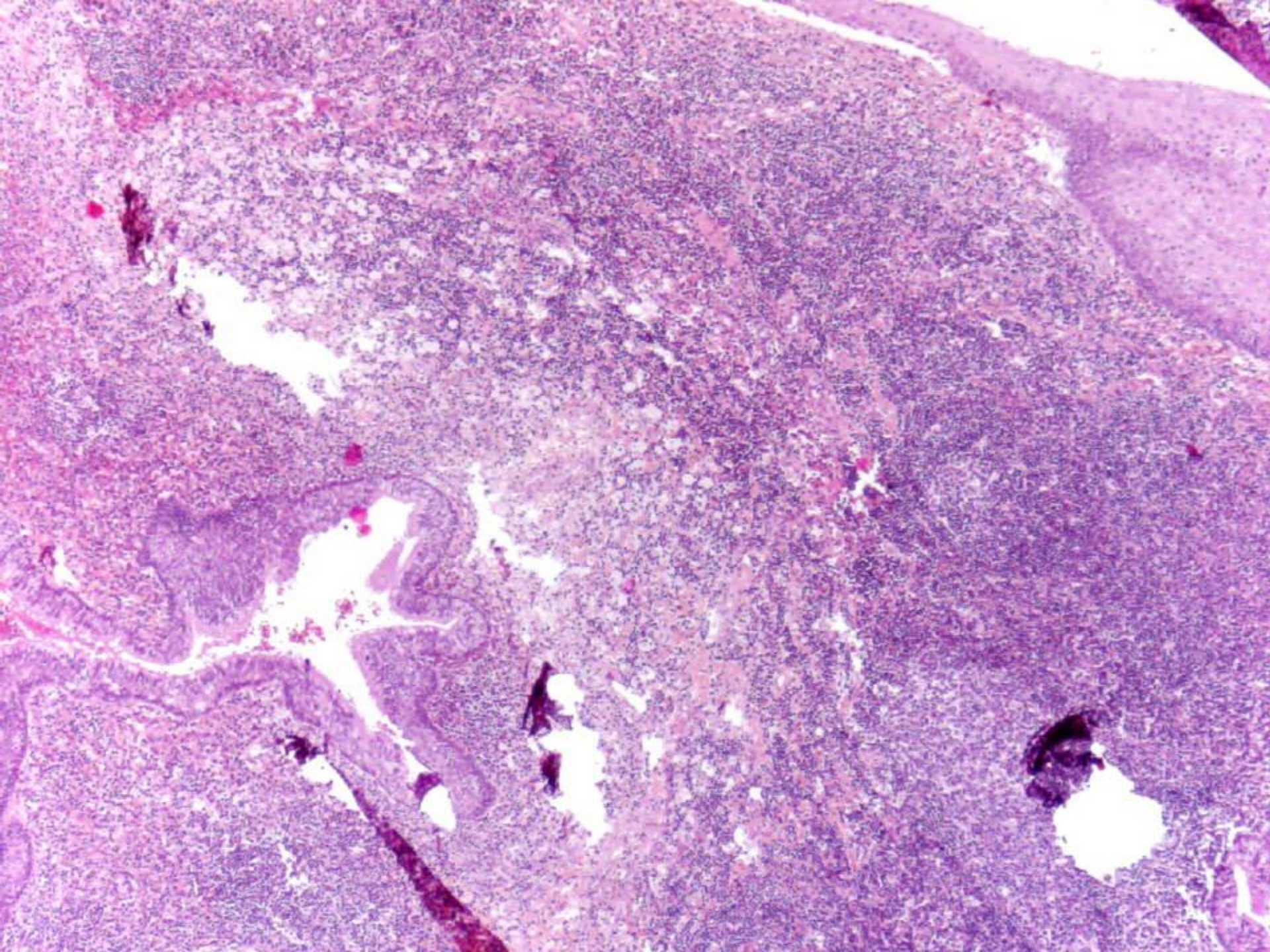
cd10

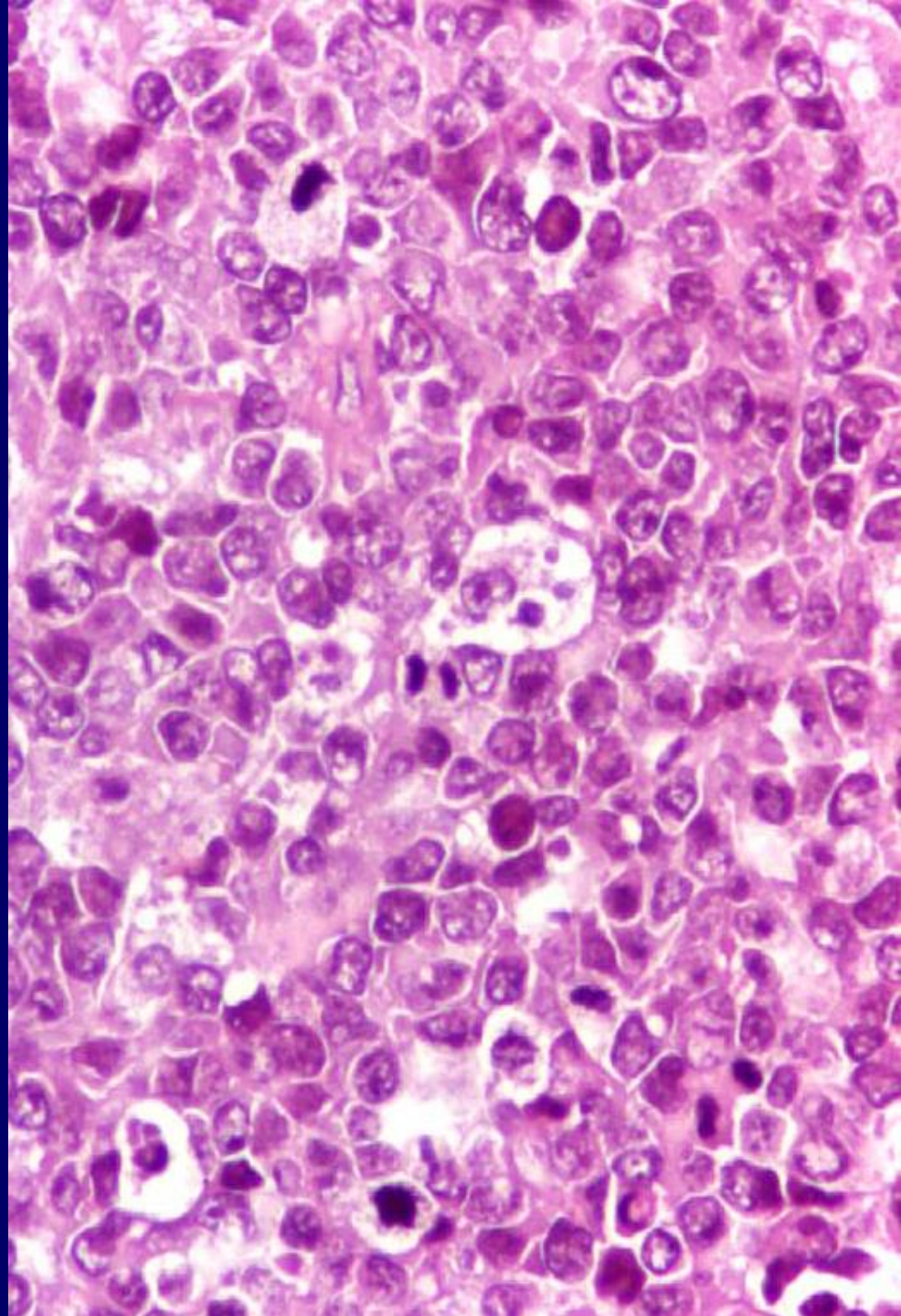
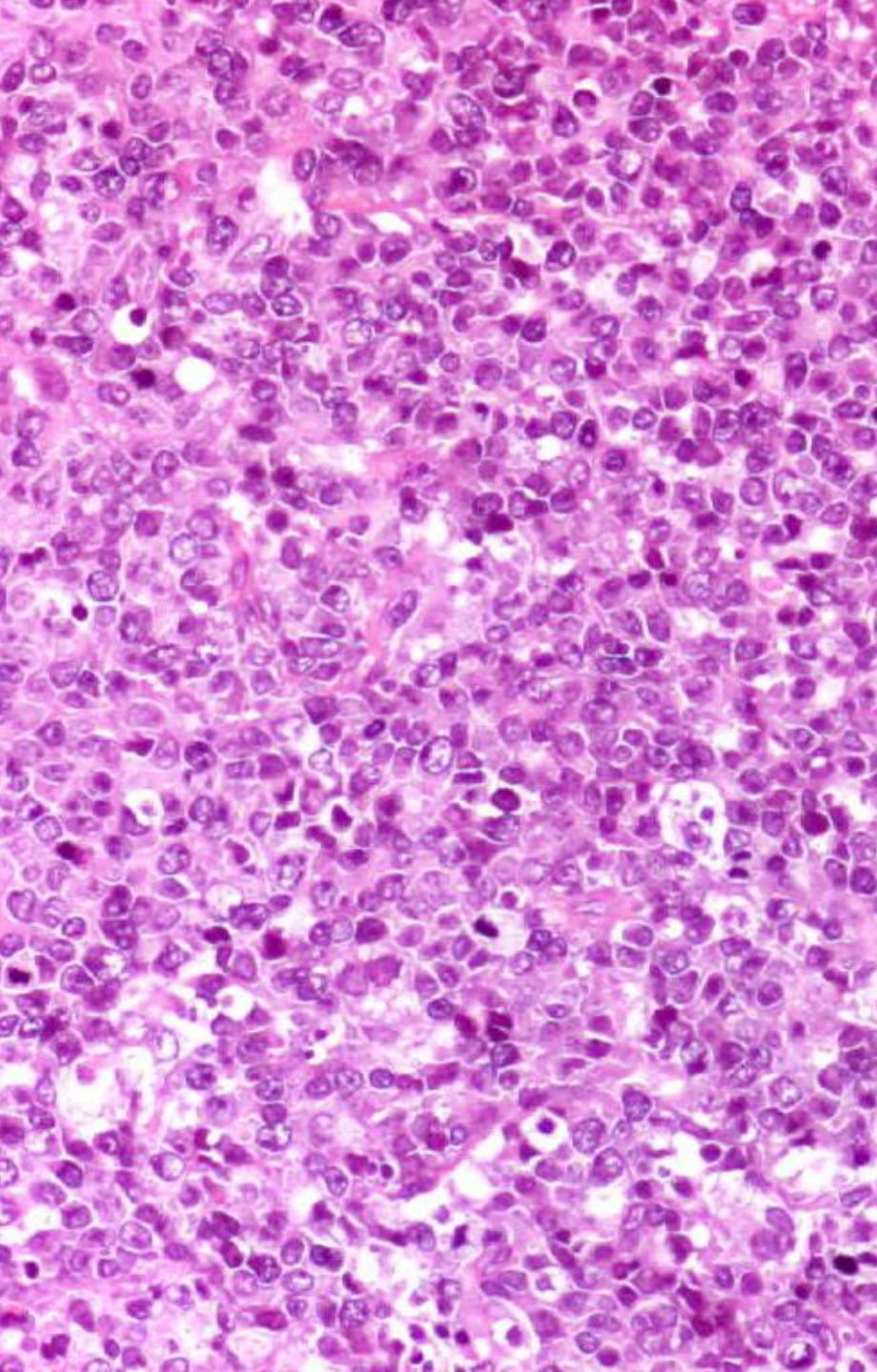
N° 18

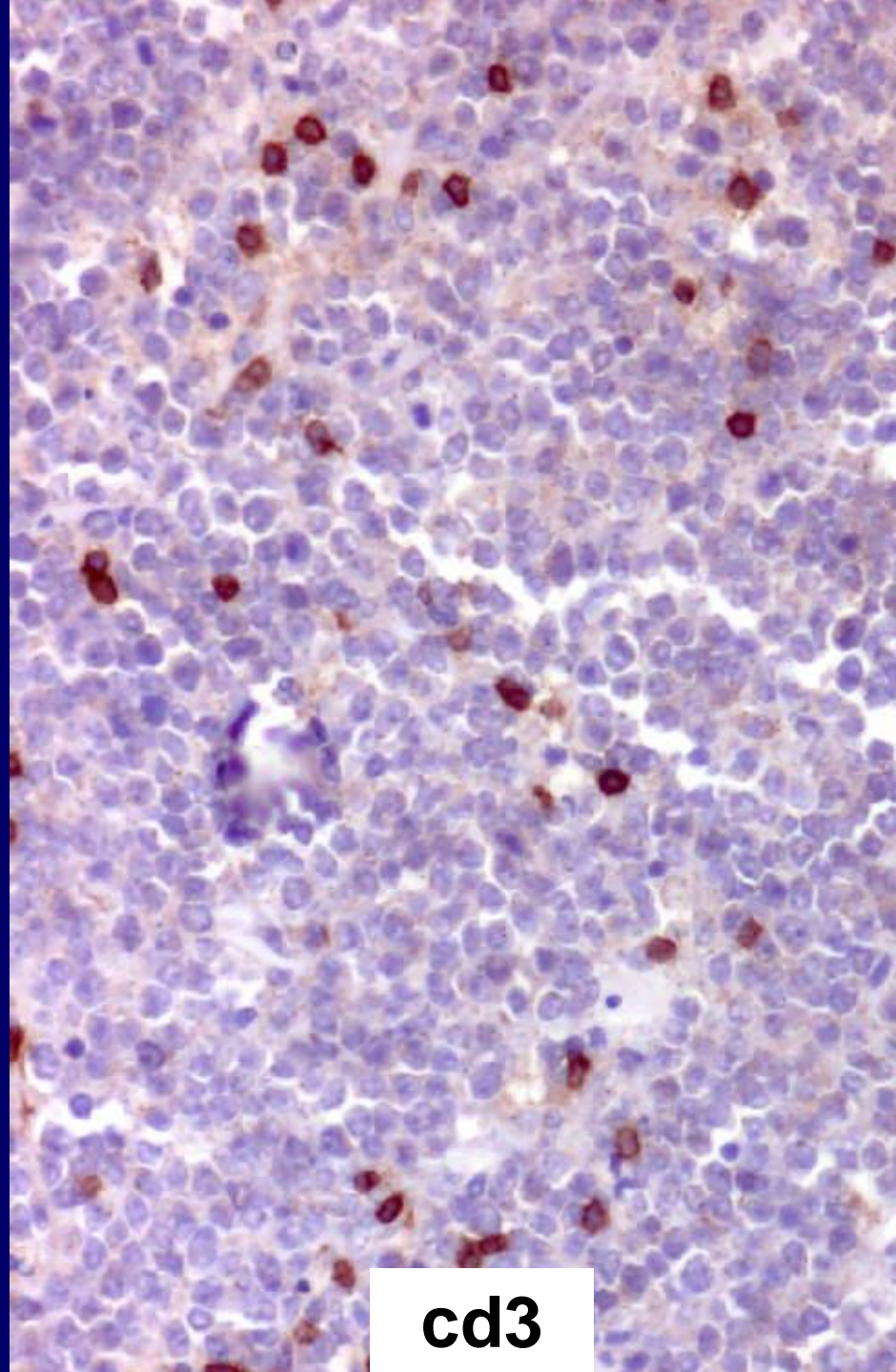
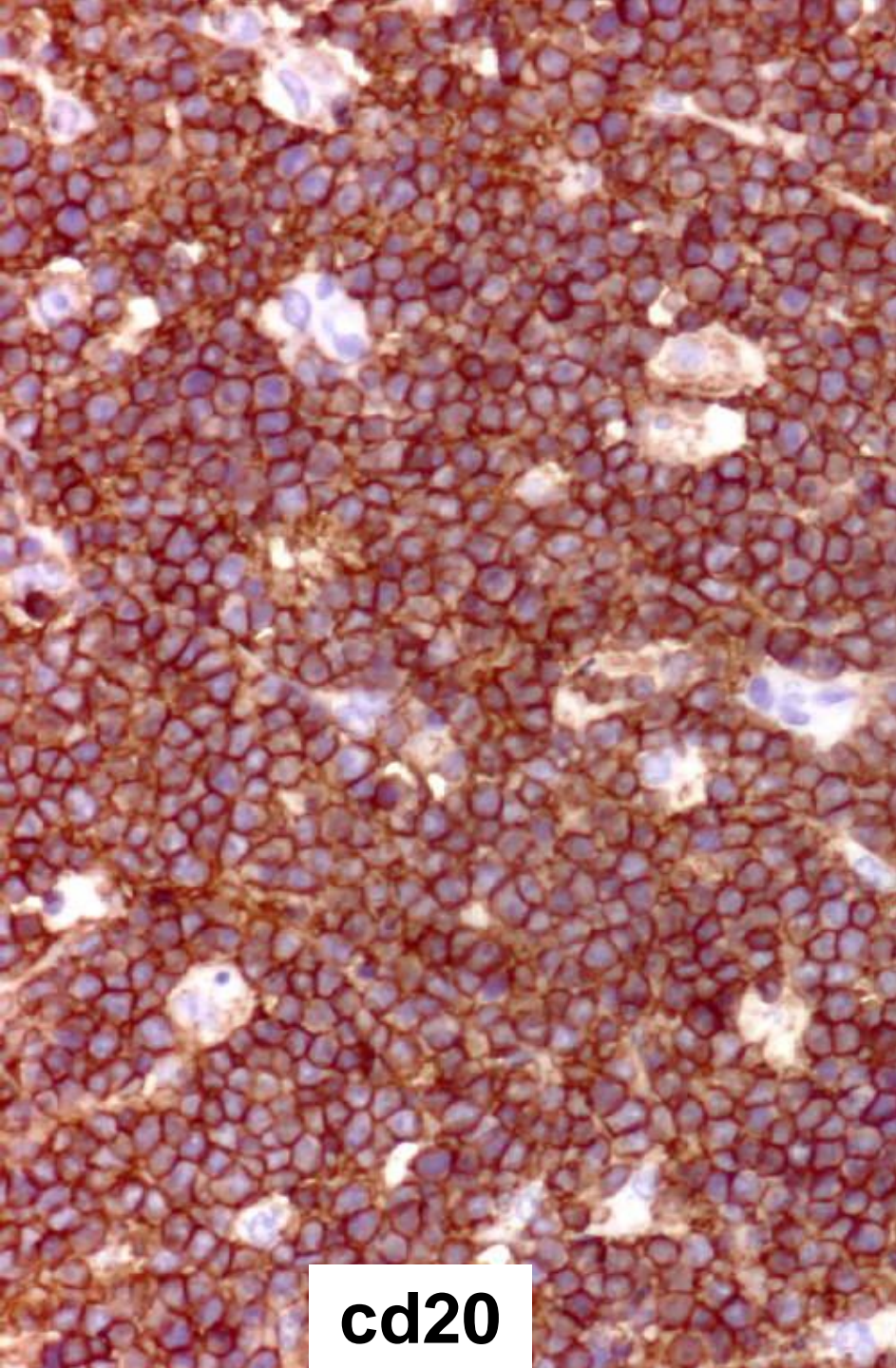
Lymphome de Burkitt

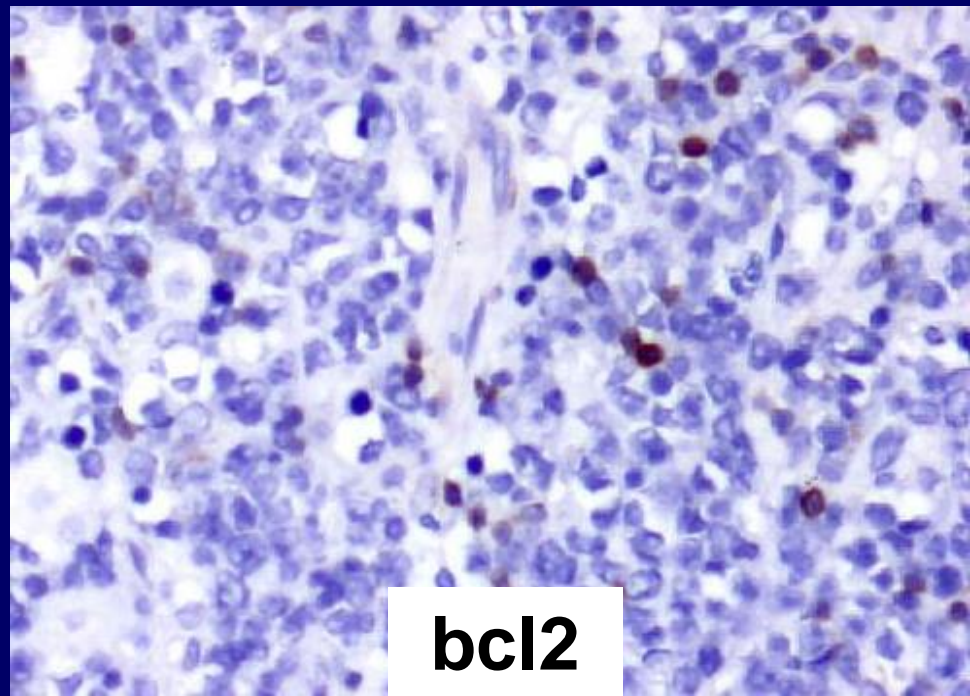
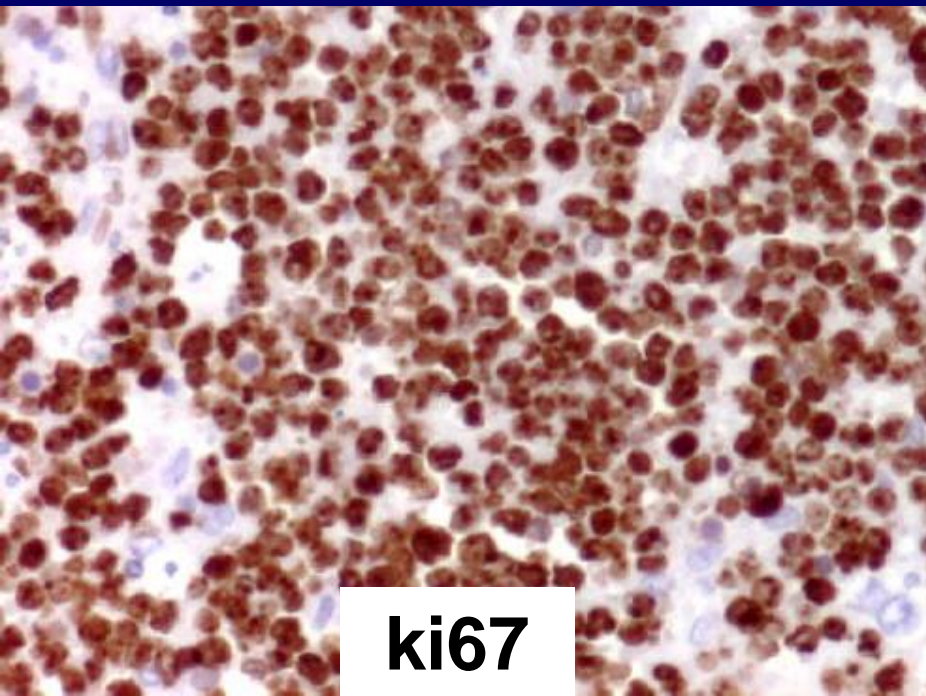
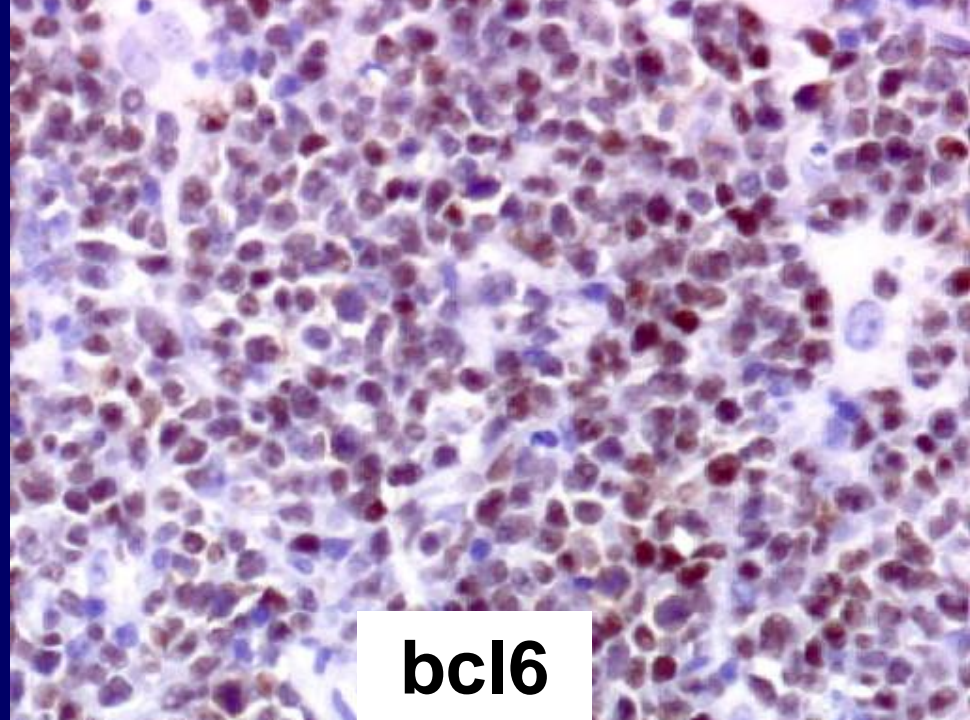
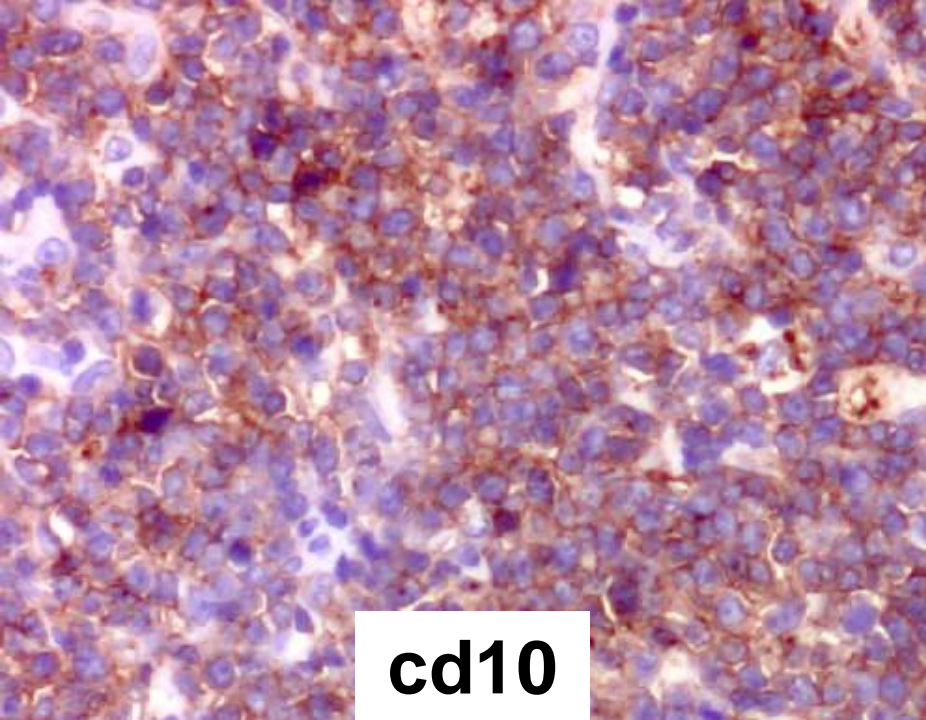
**cd20 + , cd10 + , bcl2 - , bcl6 +, Mib à 100%,
mais pas de translocation C-myc**

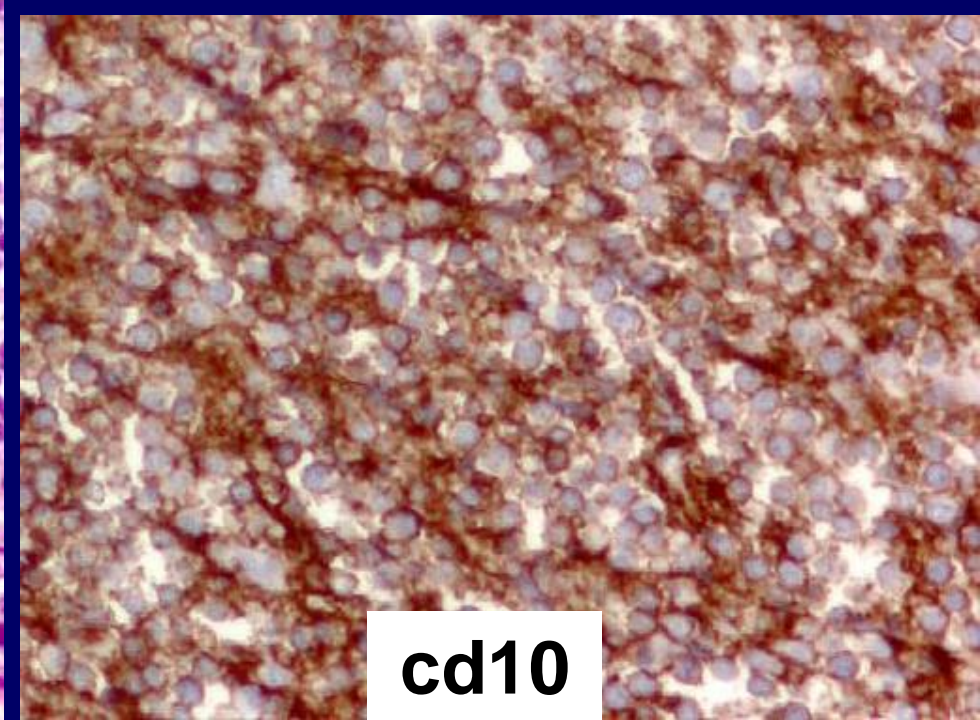

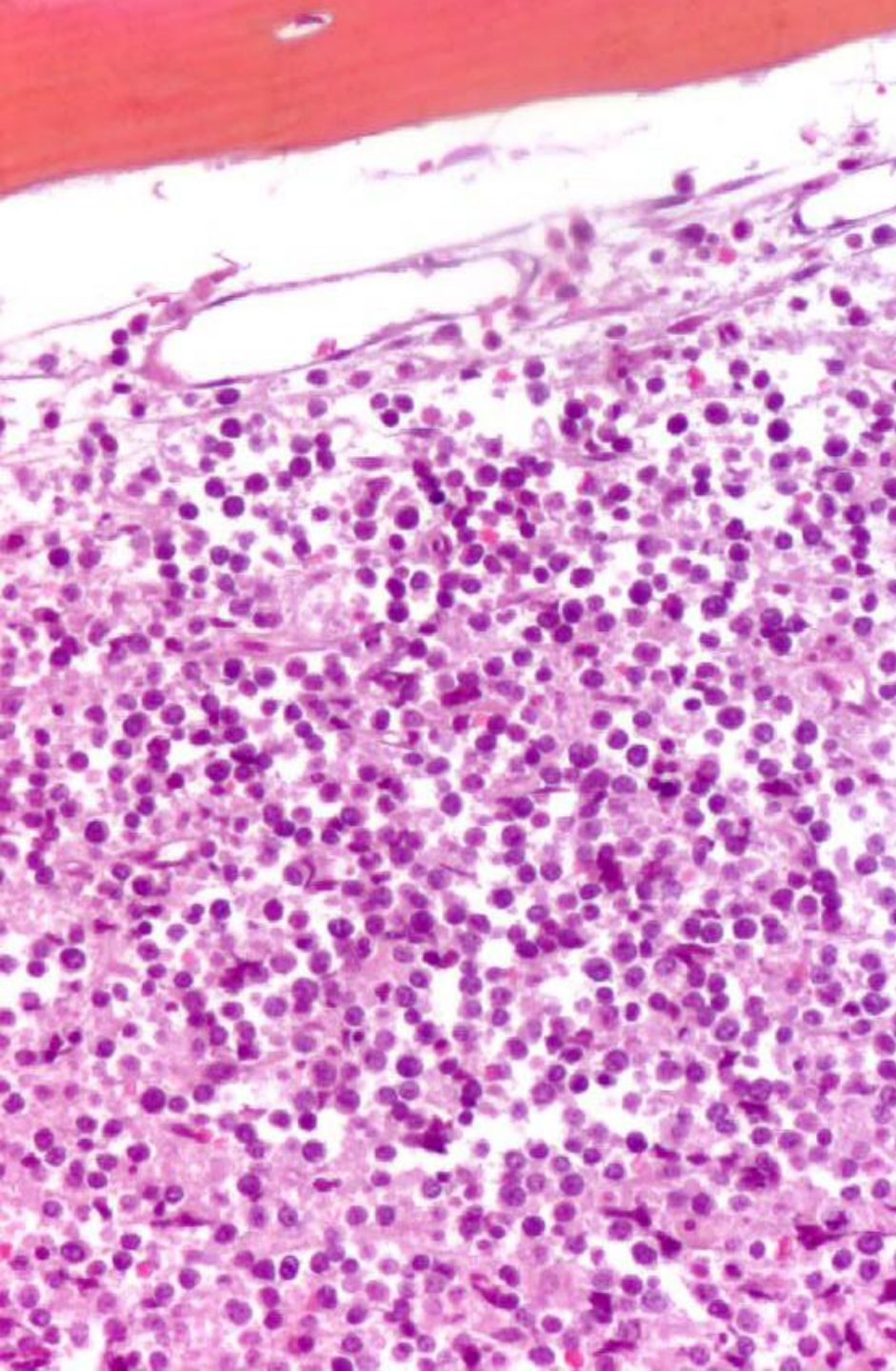
Avis Pr De Mascarel











Diagnostic Pr De Mascarel

Lymphome de Burkitt

cd20 + , cd10 + , bcl2 - , bcl6 +, Mib à 100%,
mais pas de translocation C-myc