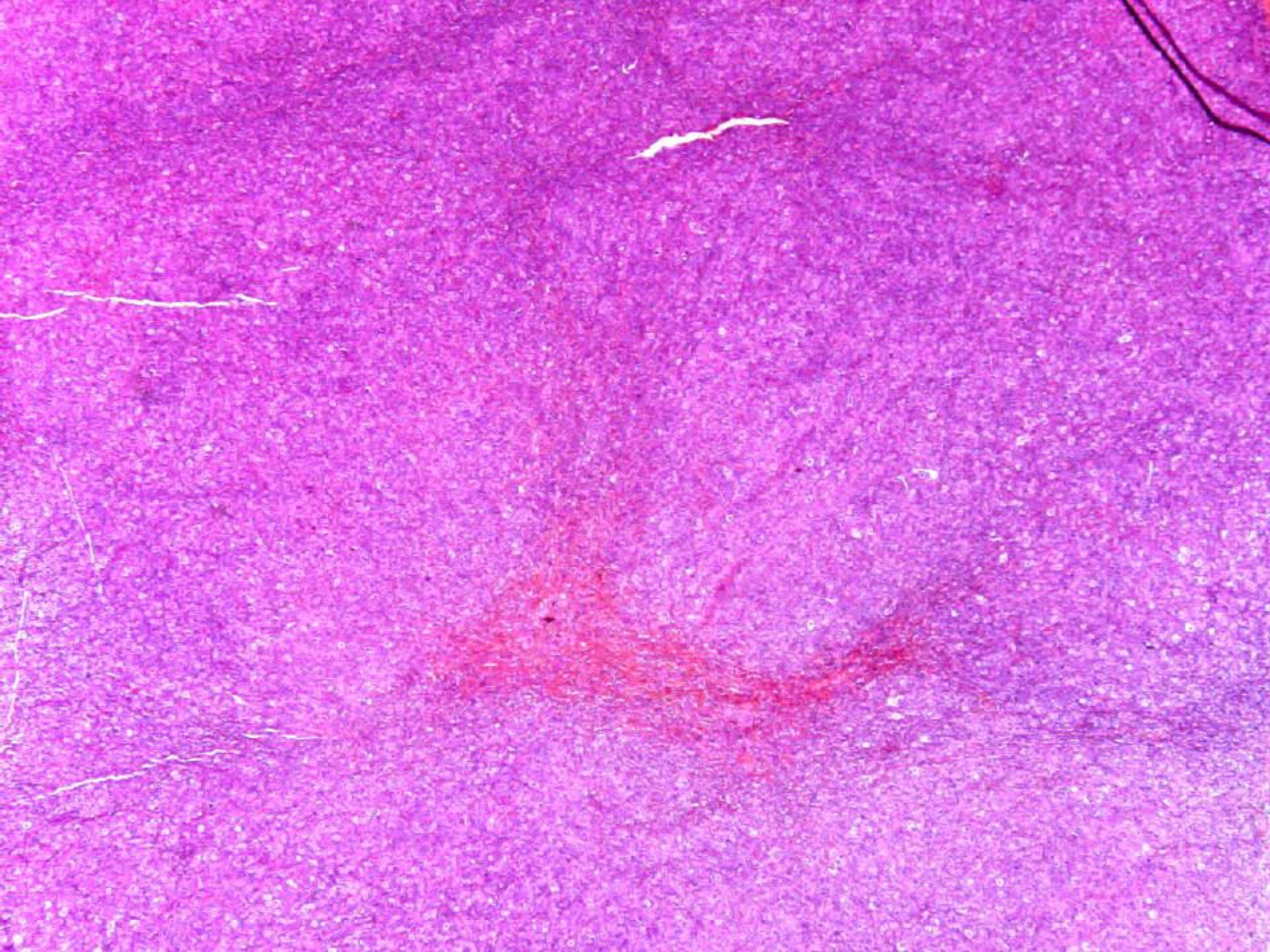
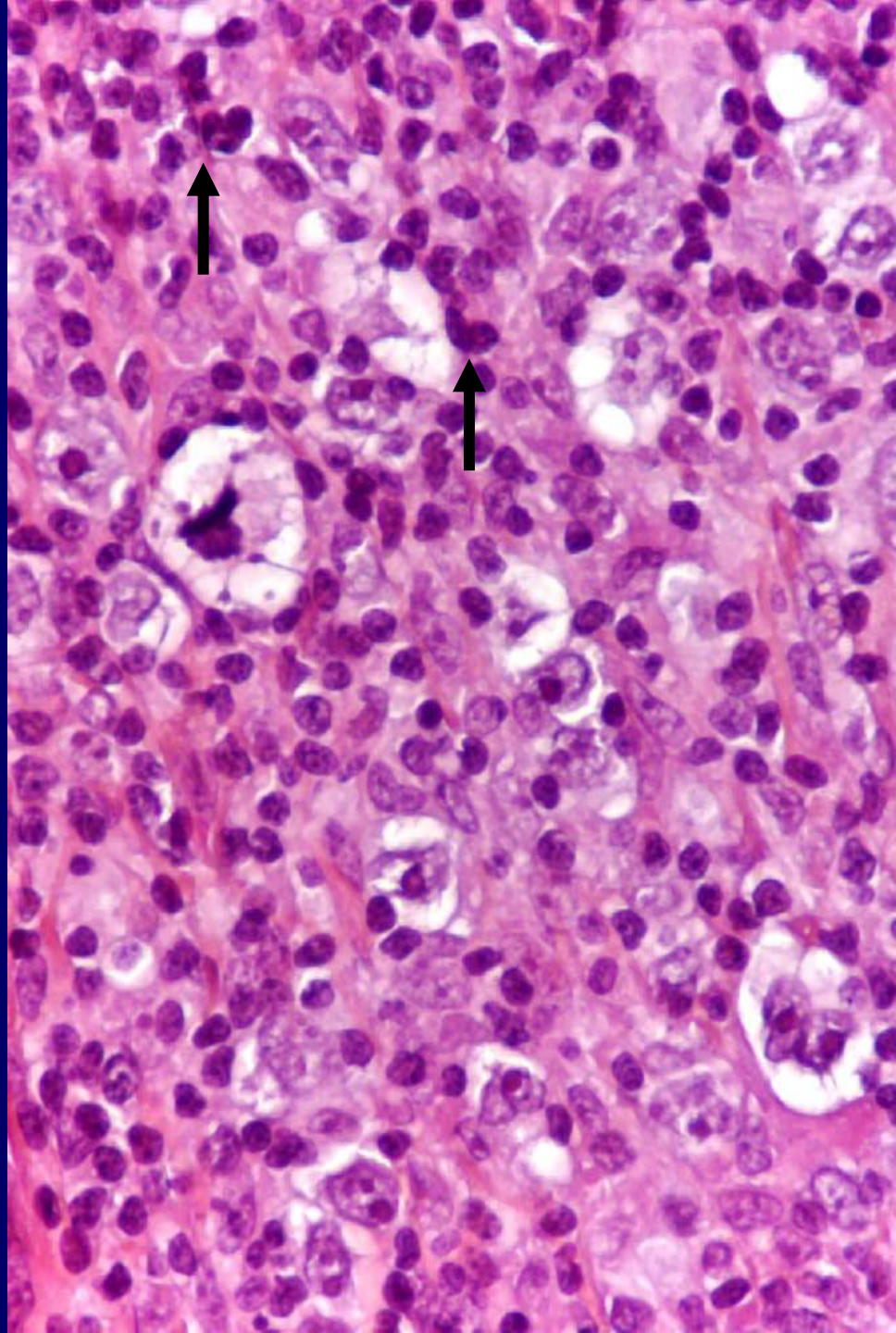
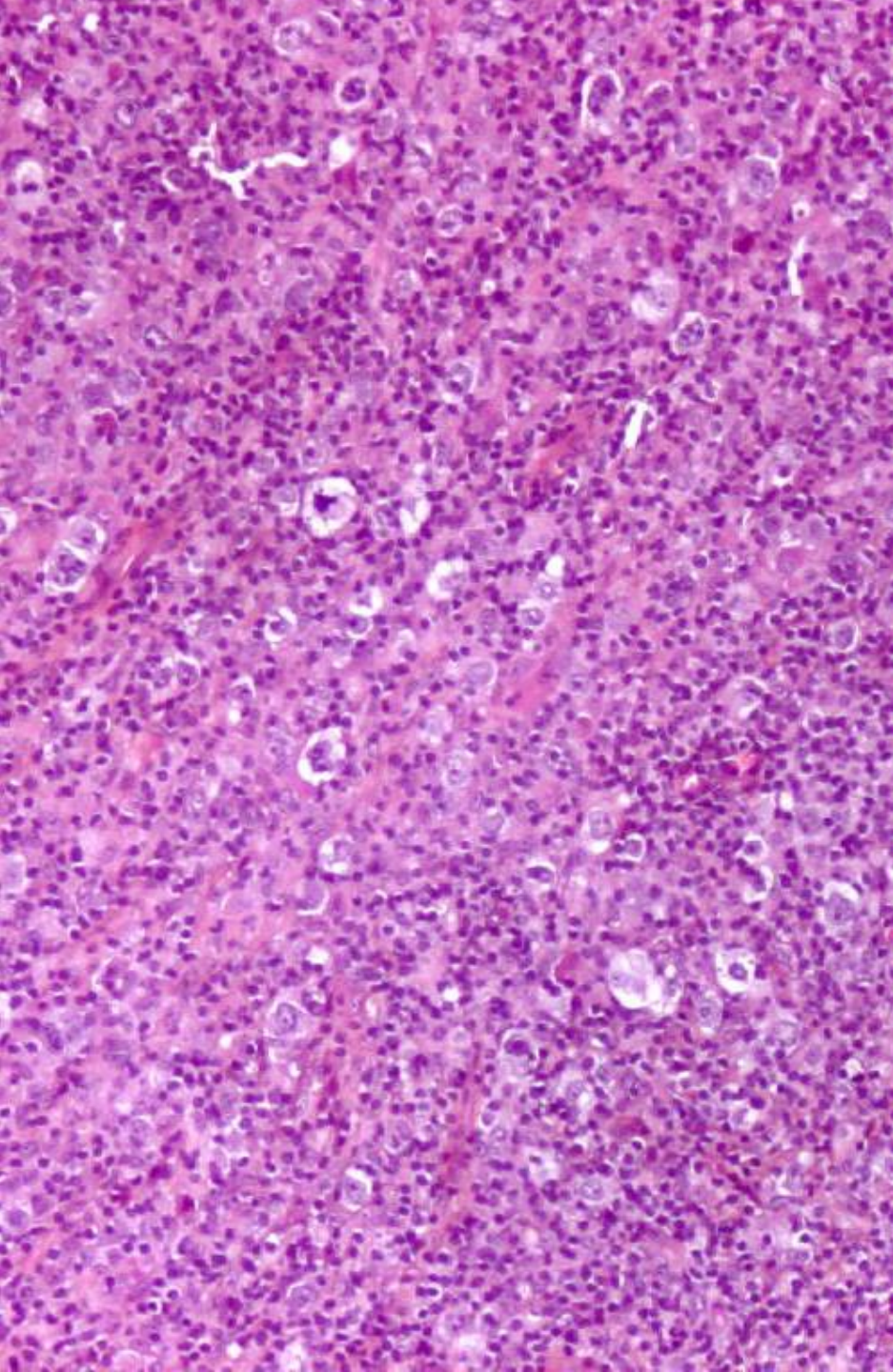


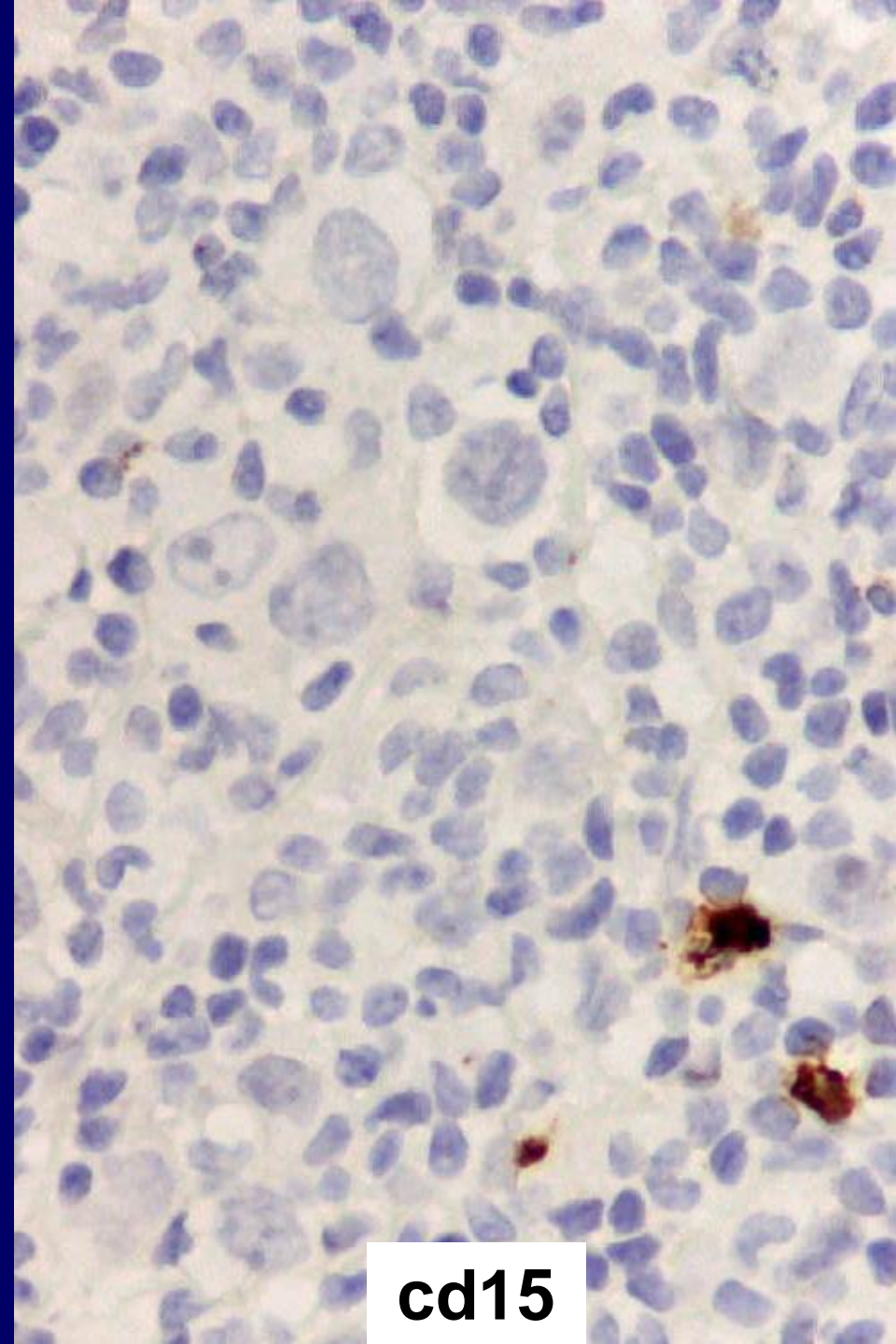
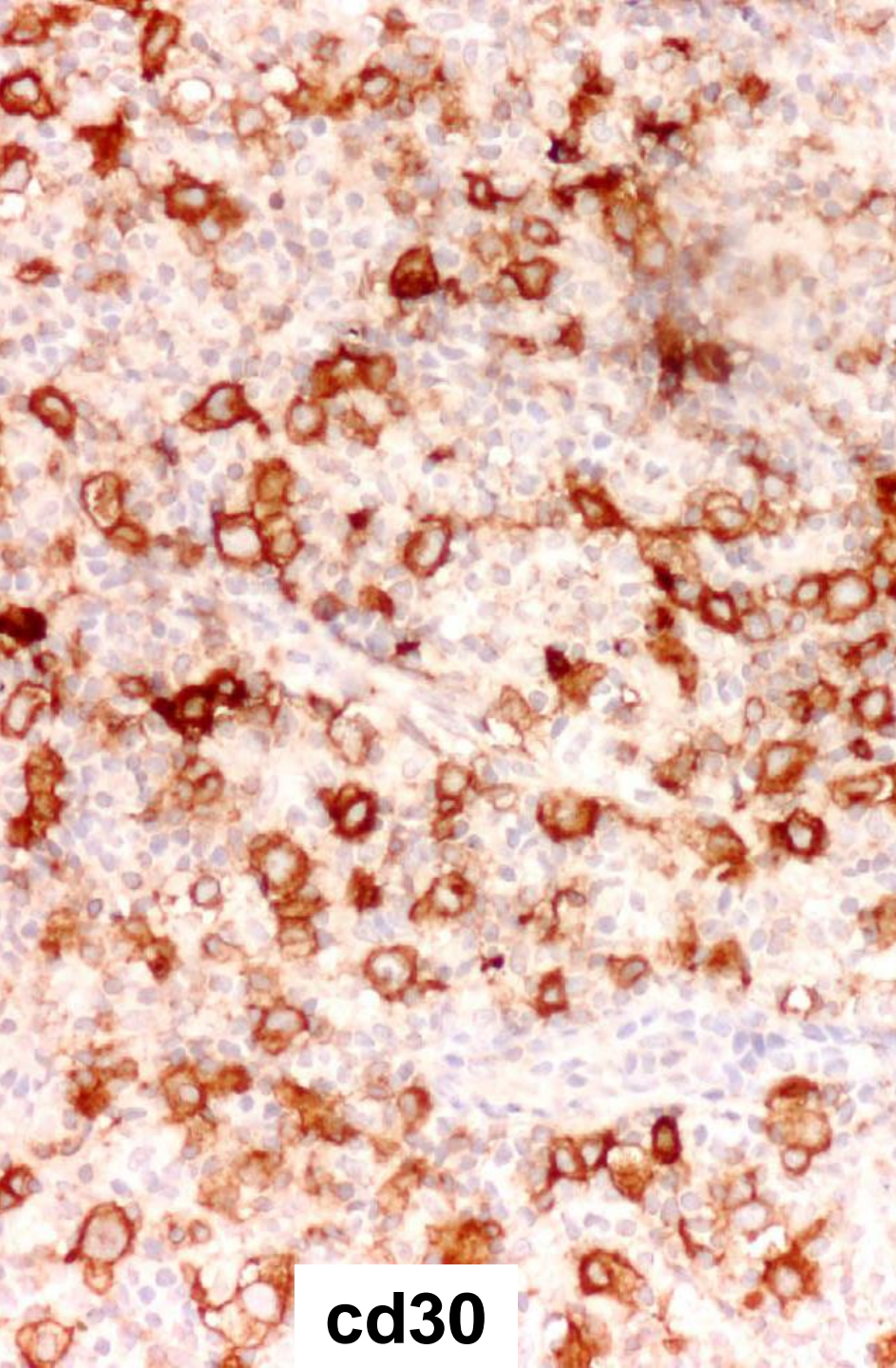
# N° 14

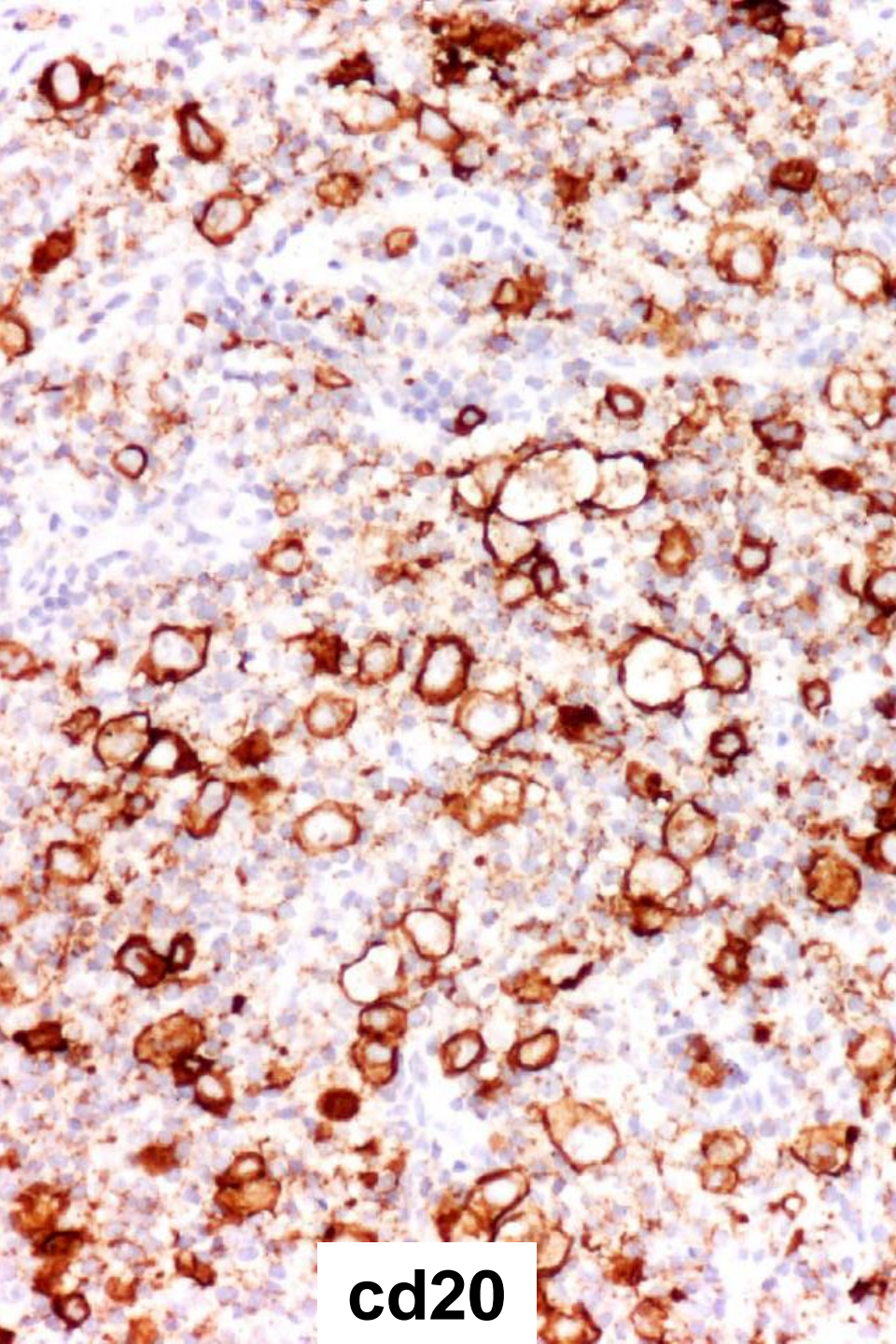
## Alger

- Femme de 61 ans.
- Adénopathies périphériques et profondes
- Hépatosplénomégalie
  
- Biopsie ganglionnaire : 3405/07.

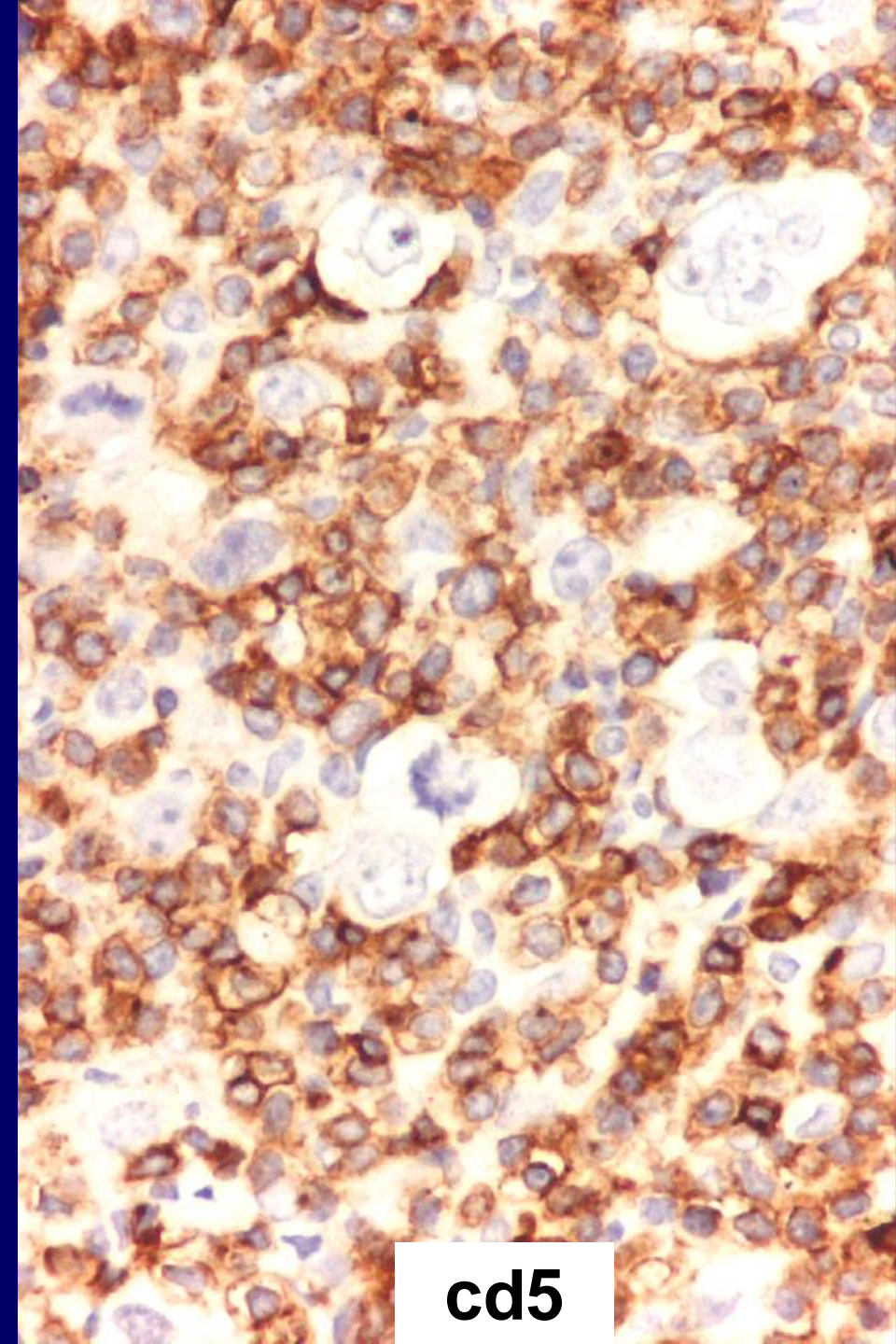




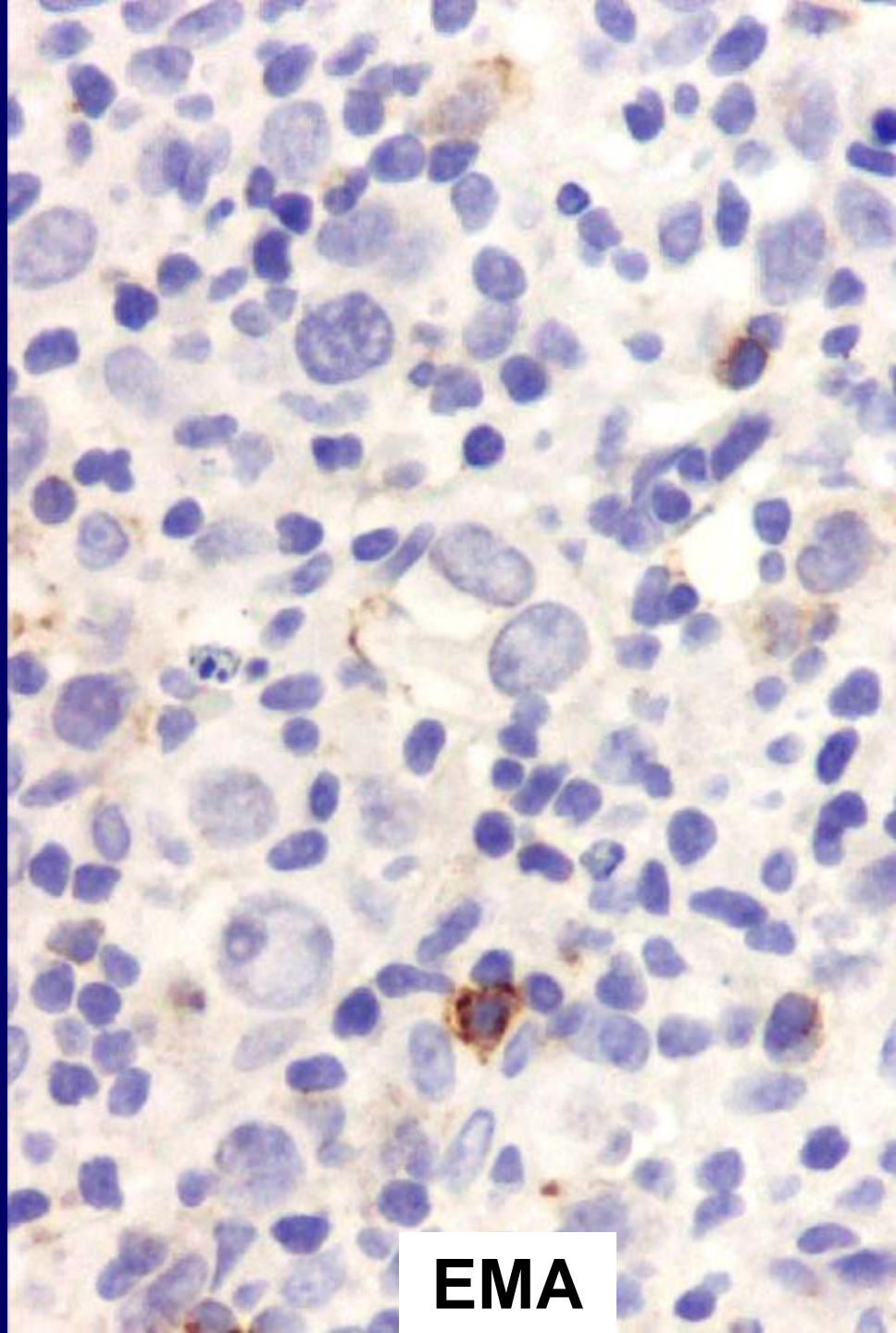
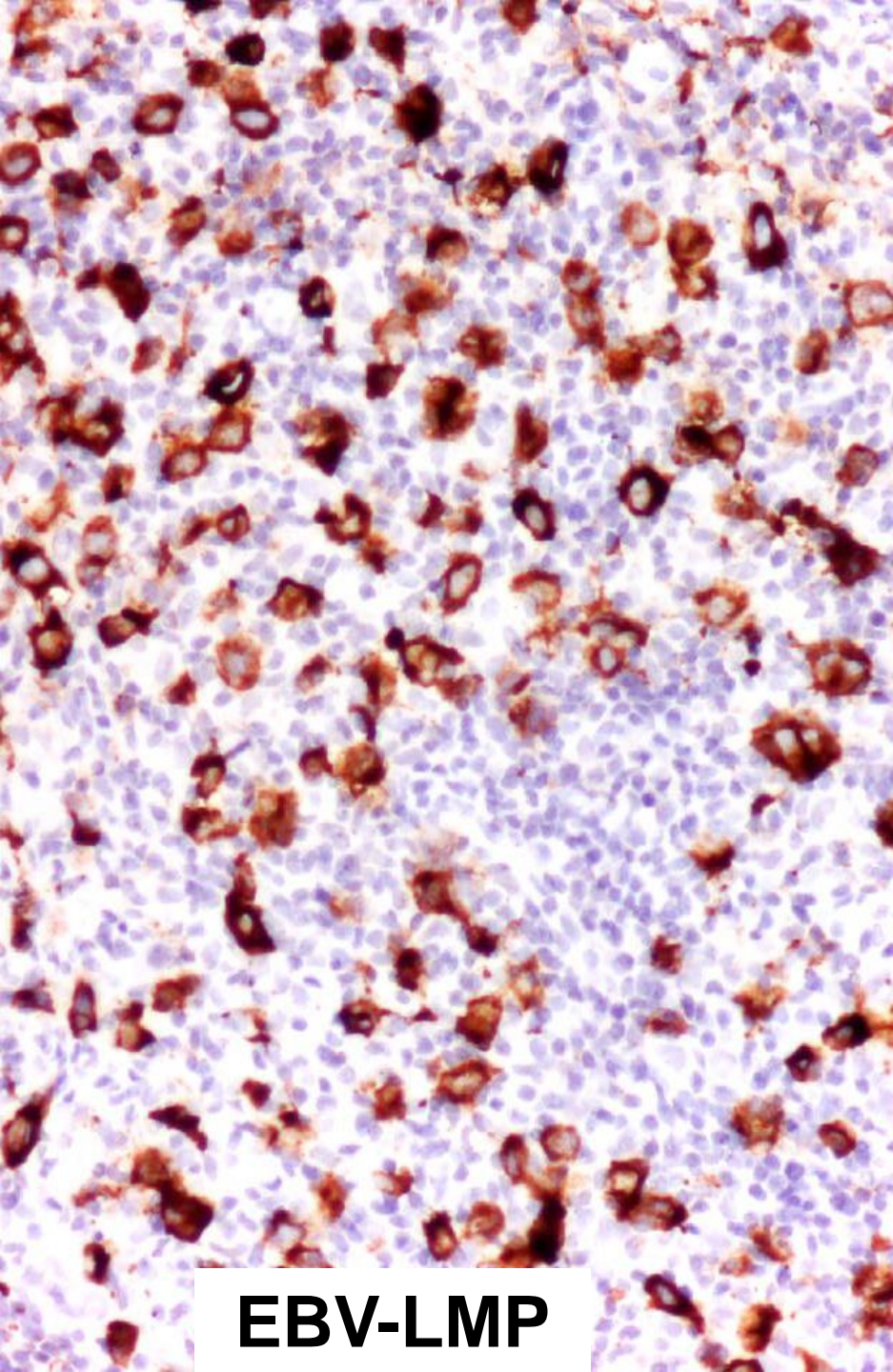




**cd20**



**cd5**



# N° 14

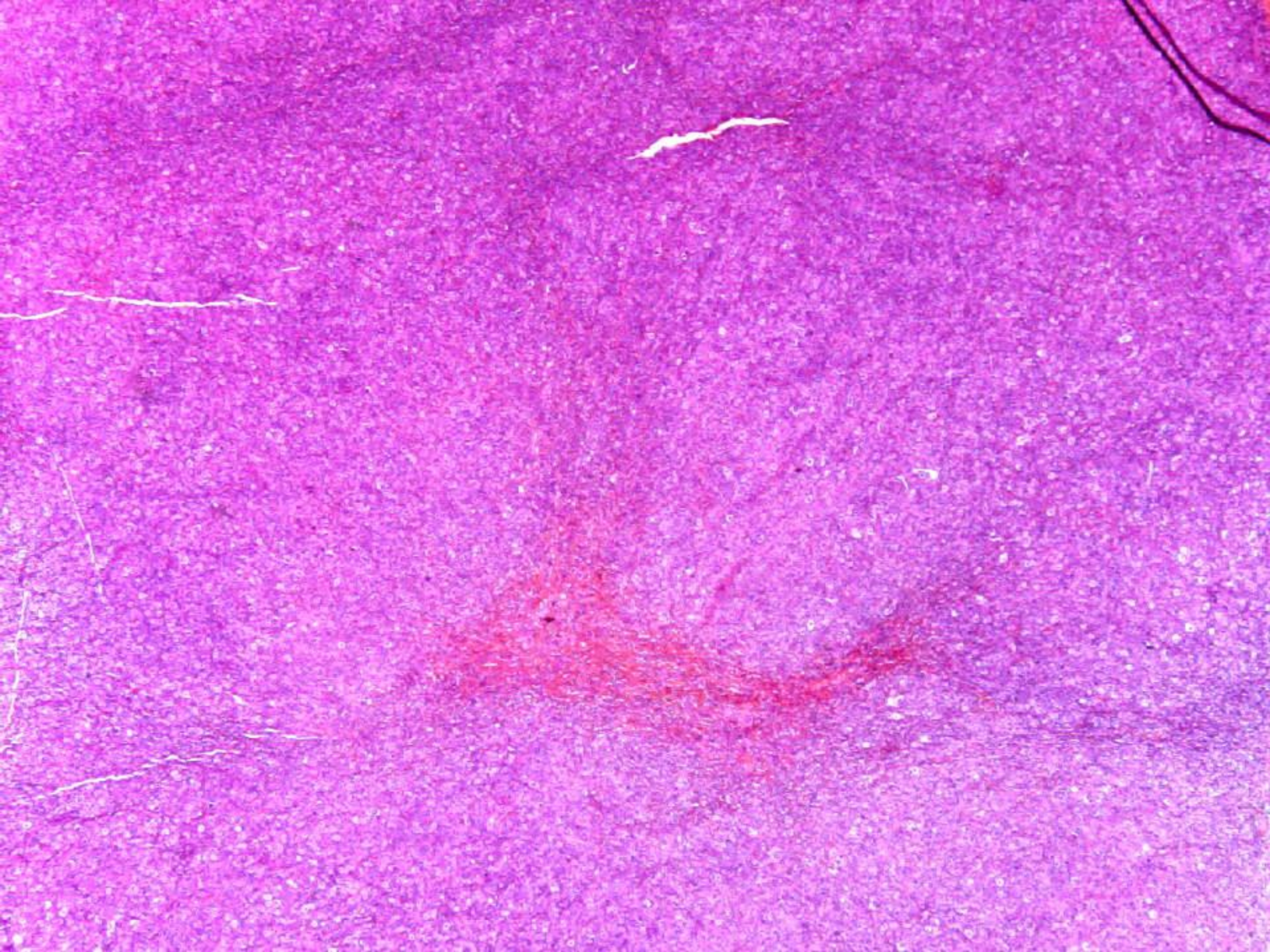
**Lymphome de Hodgkin classique,  
type scléronodulaire**

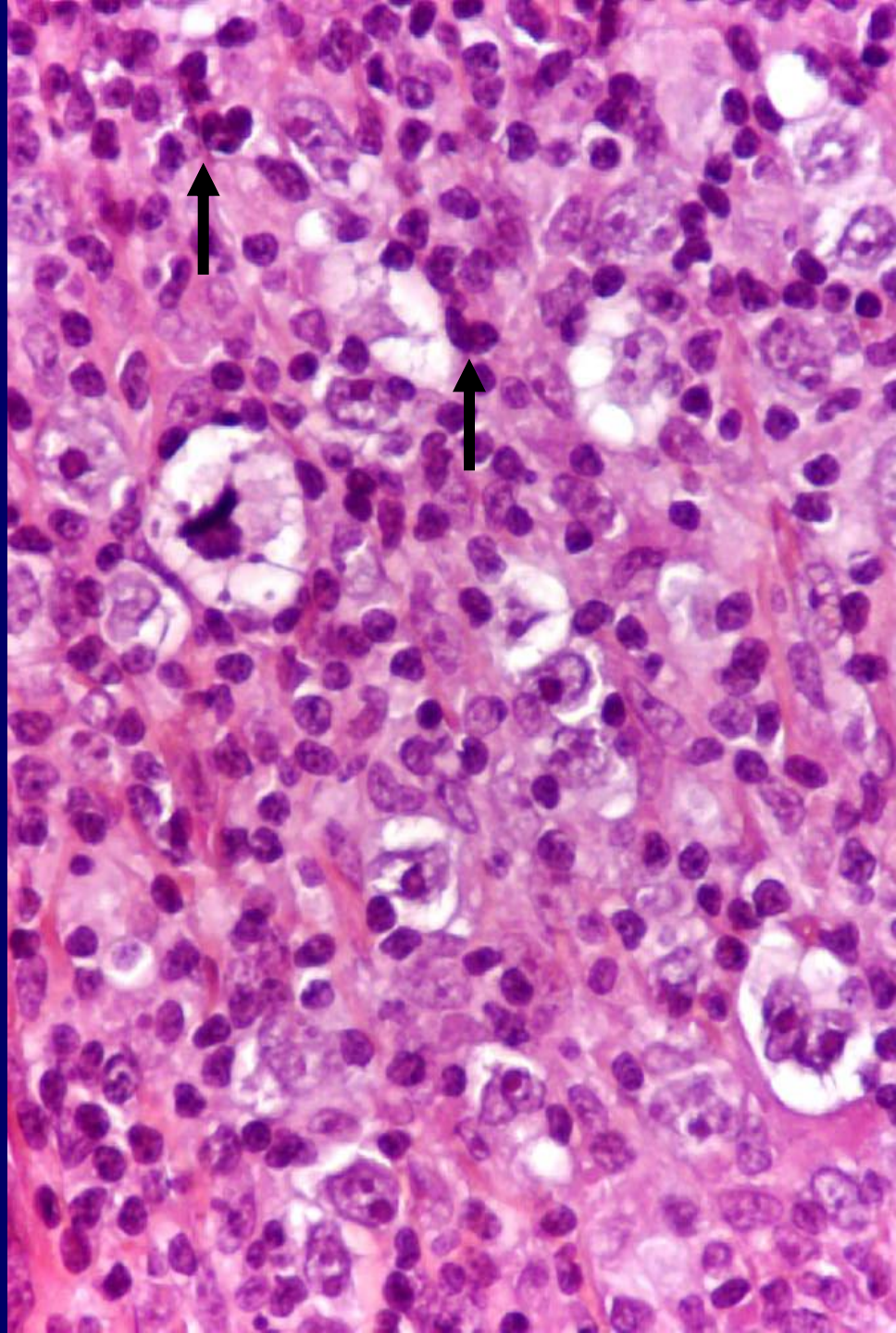
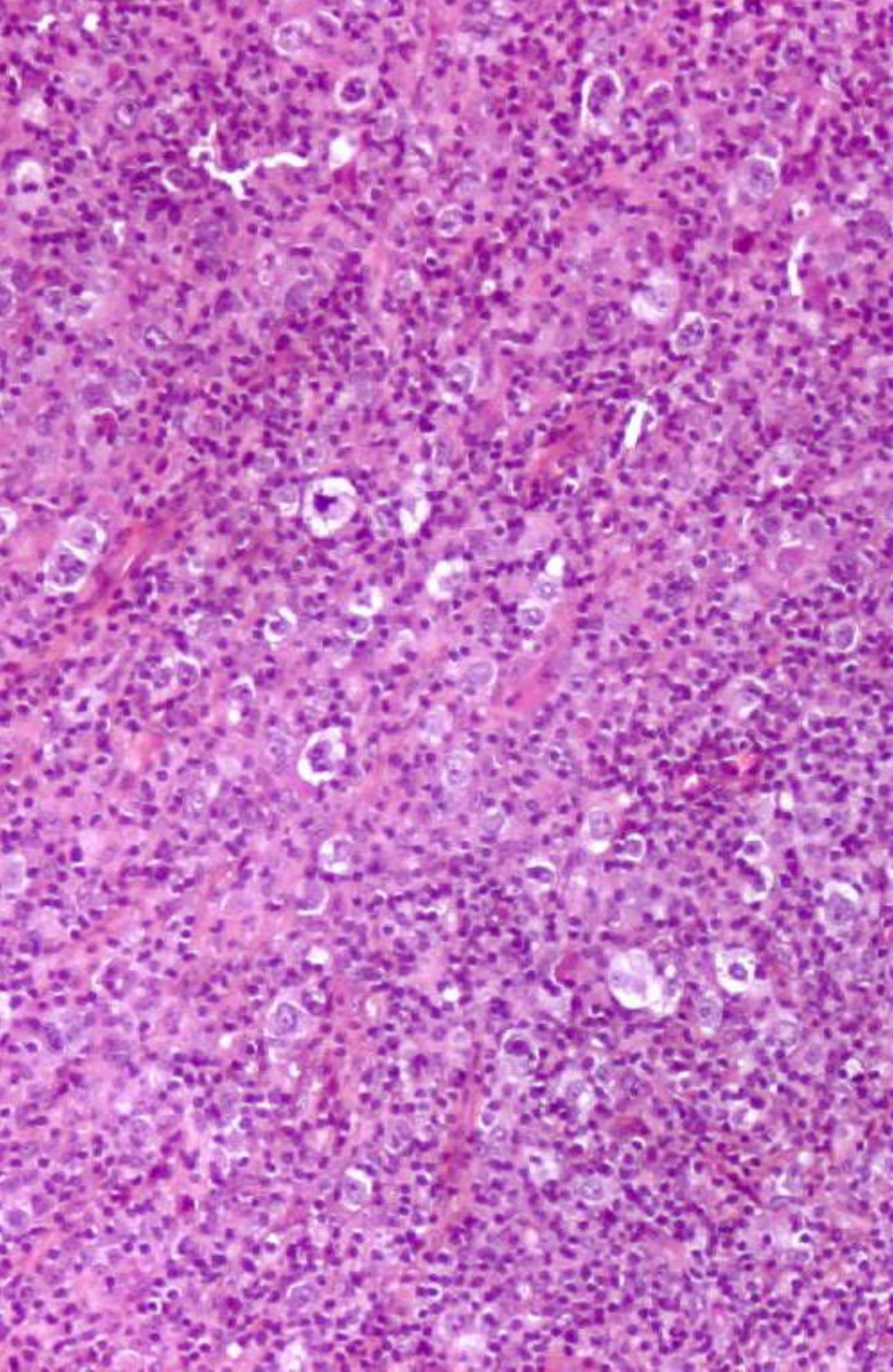
**C/RS : cd30 + , EBV LMP + , EBNA2 - ,  
cd15 - , cd20 + , cdw75 -**

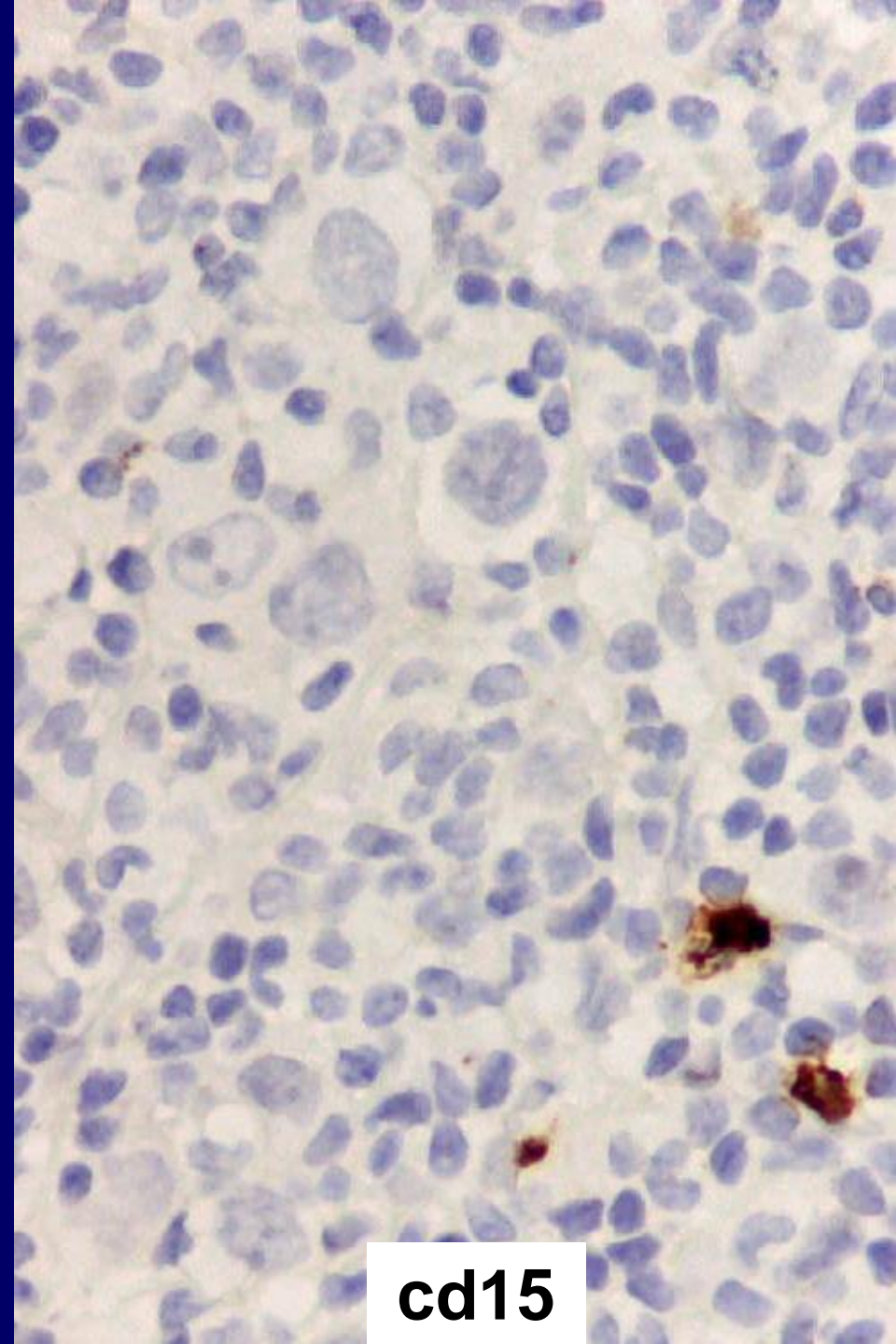
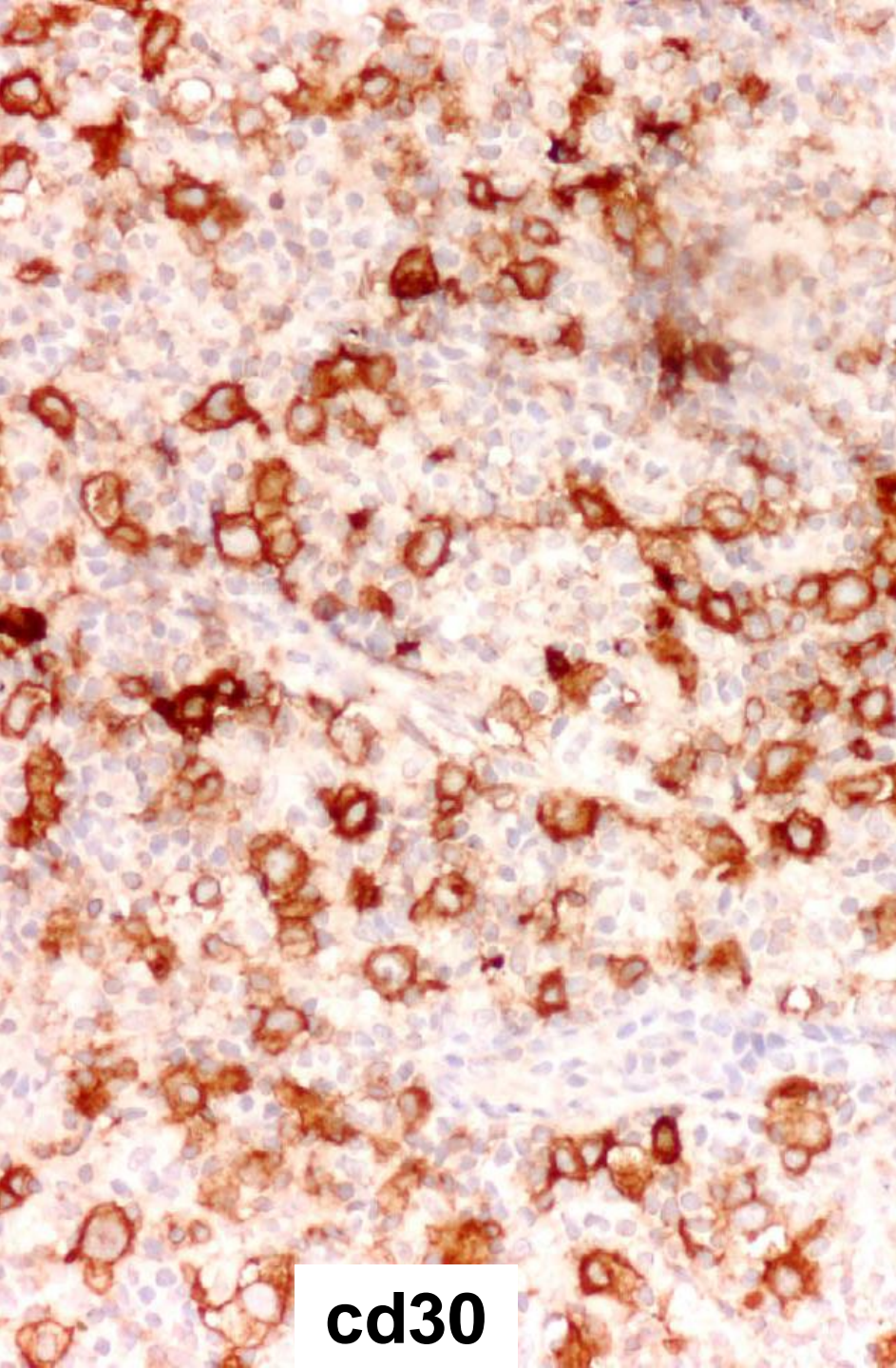
**DLBCL peu probable : EBV + , EMA -  
PCR B?**

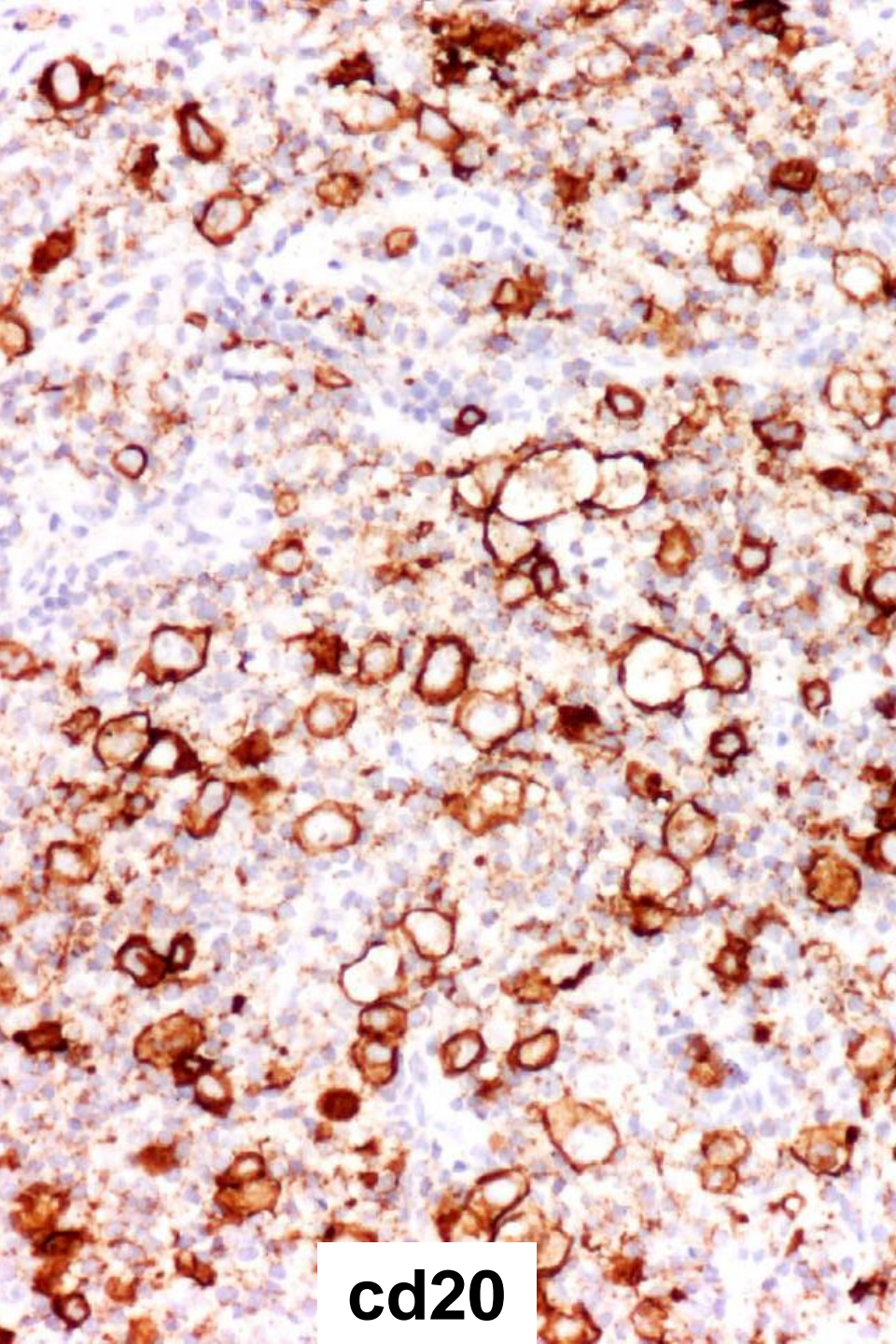
**Avis Pr De mascarel**



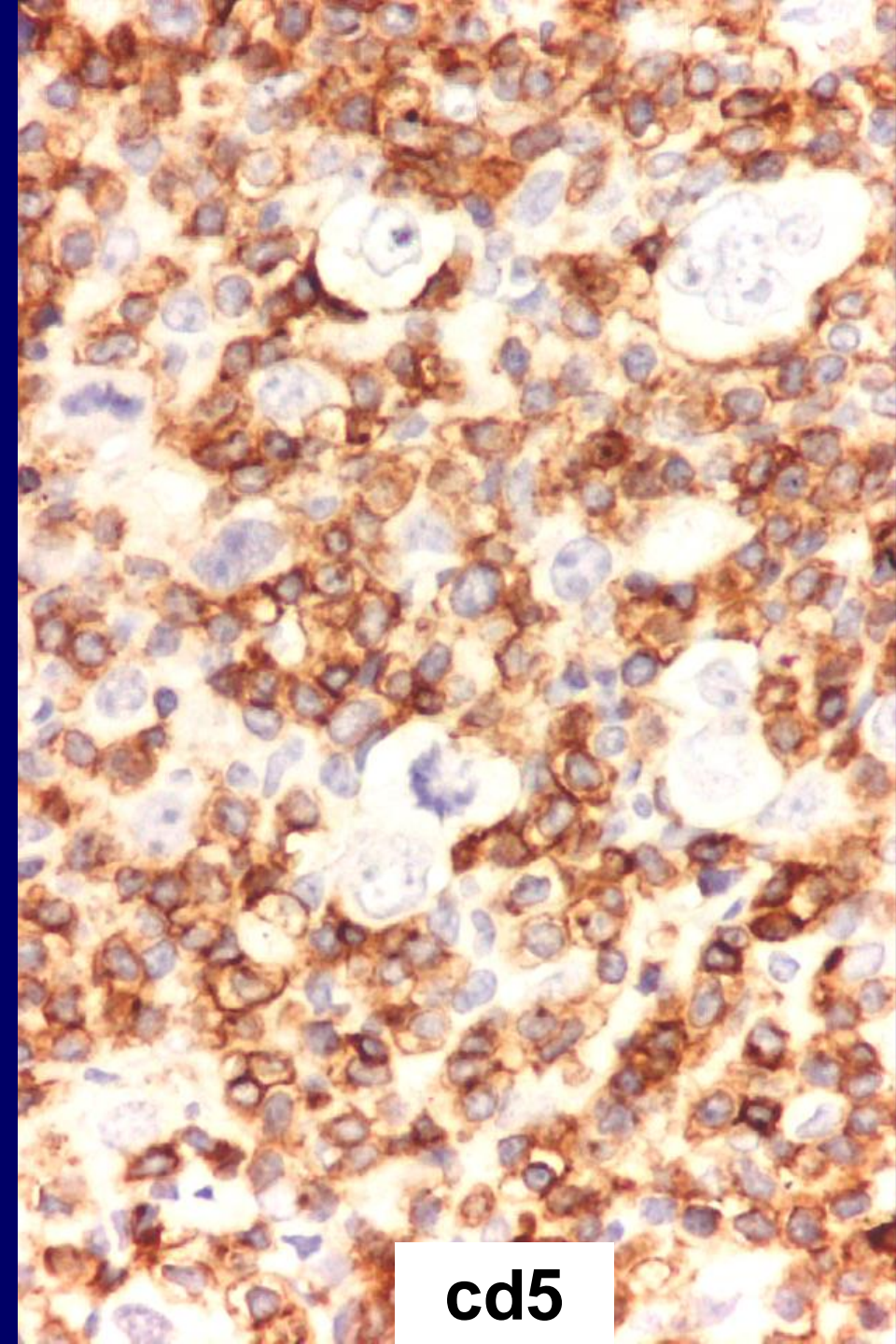




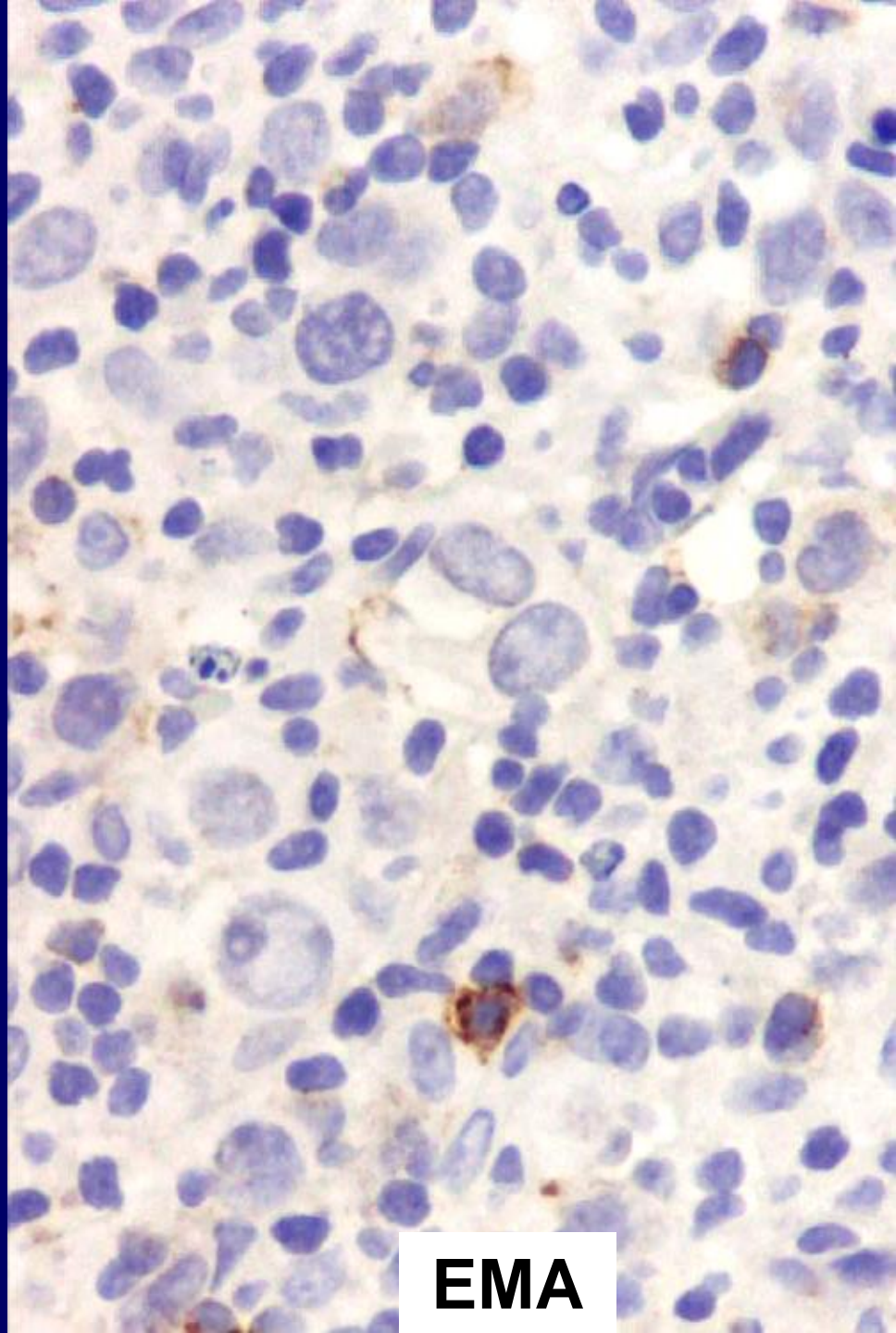
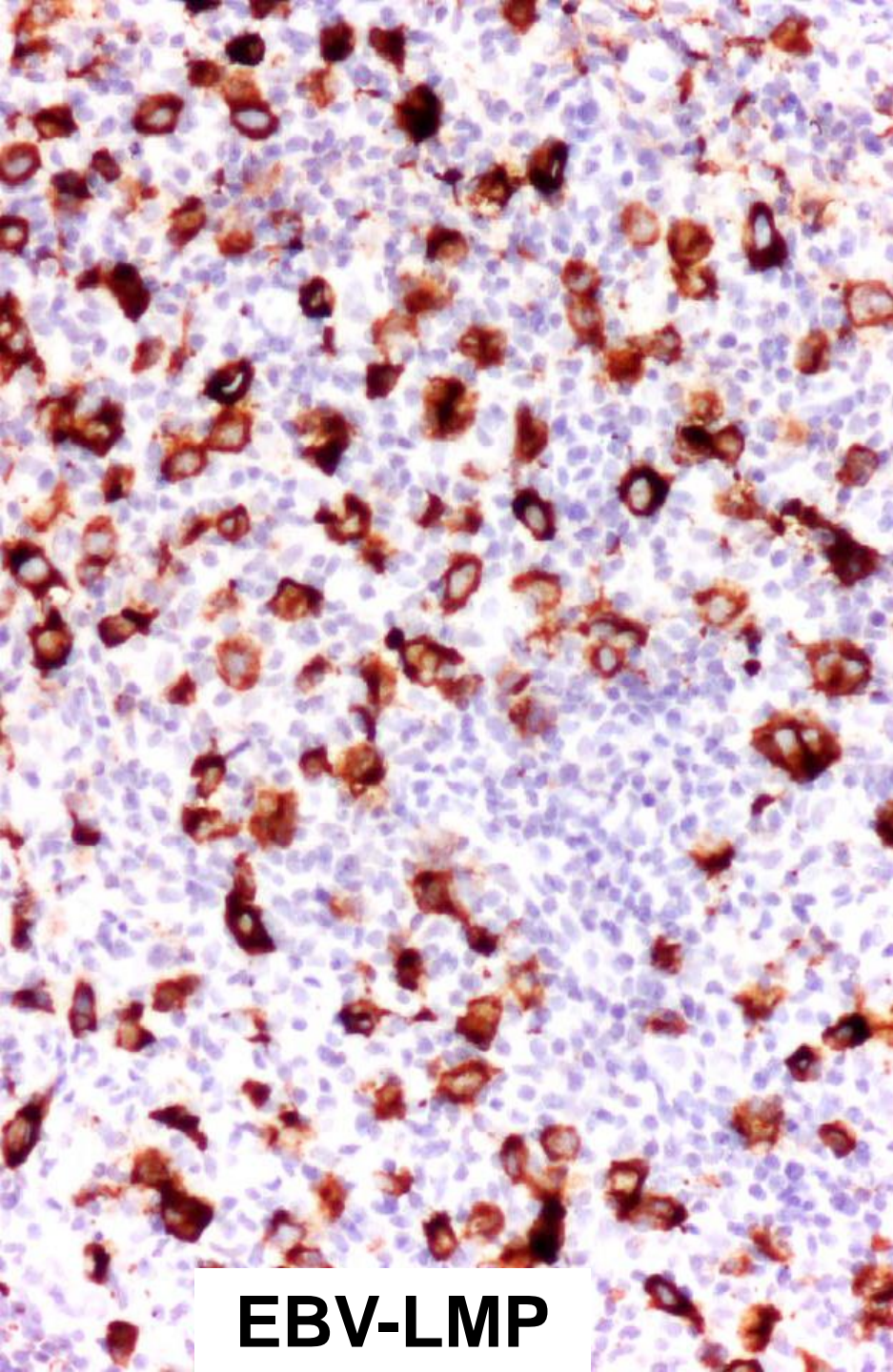




**cd20**



**cd5**



# **Diagnostic retenu par Pr De Mascarel**

**Lymphome de Hodgkin classique,  
type scléronodulaire**

**C/RS : cd30 + , EBV LMP + , EBNA2 - ,  
cd15 - , cd20 + , cdw75 -**

**DLBCL peu probable : EBV + , EMA -  
PCR B?**