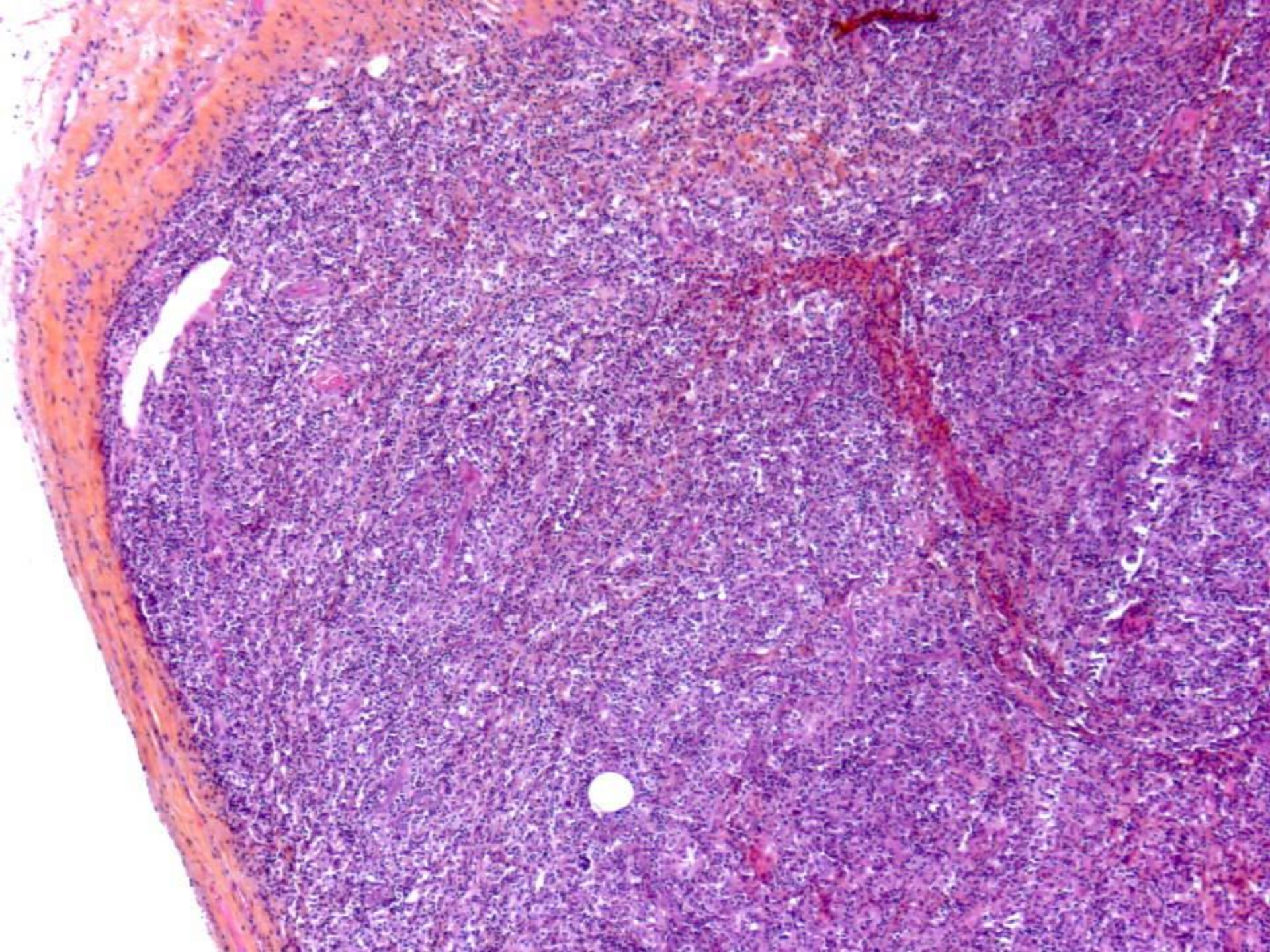
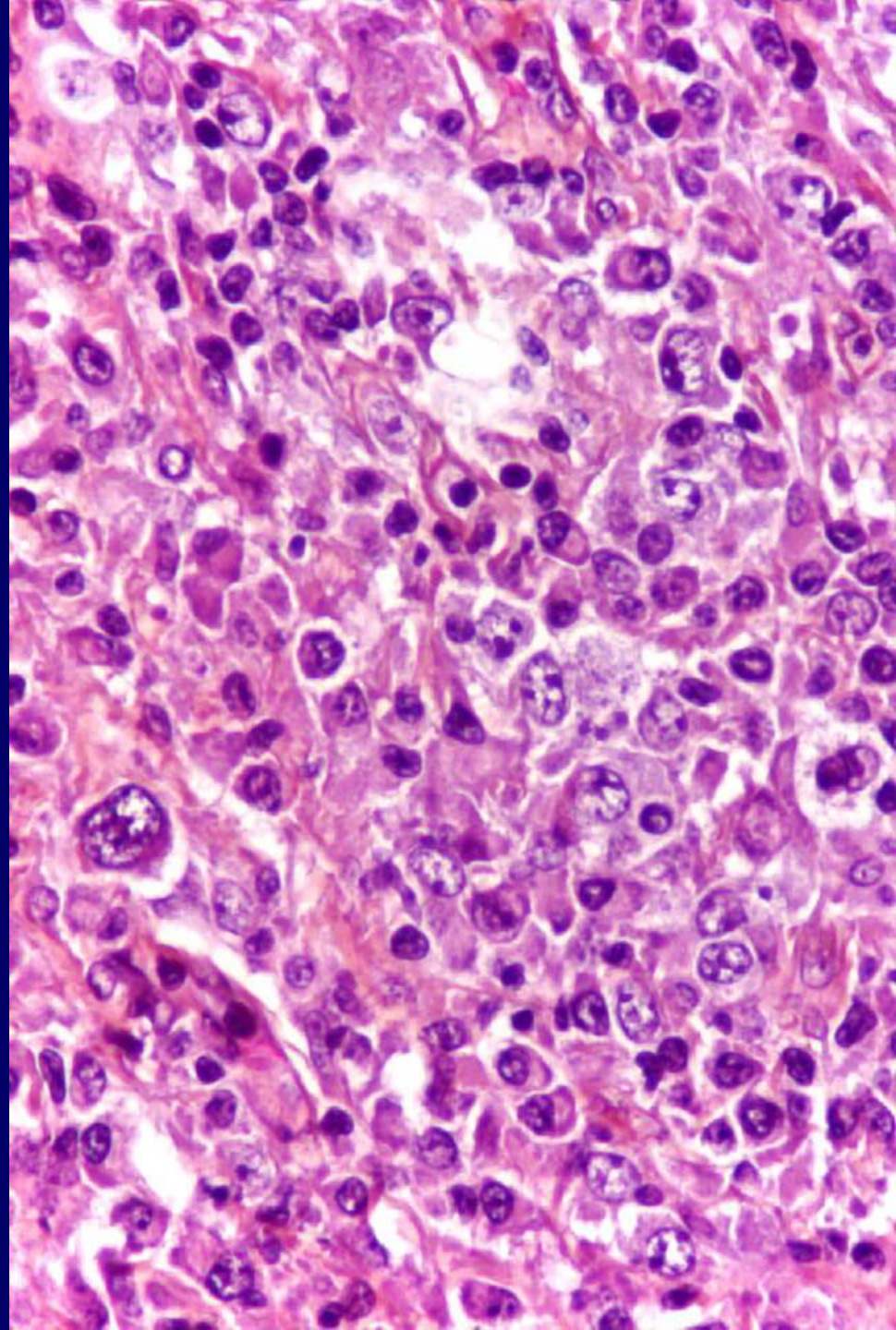
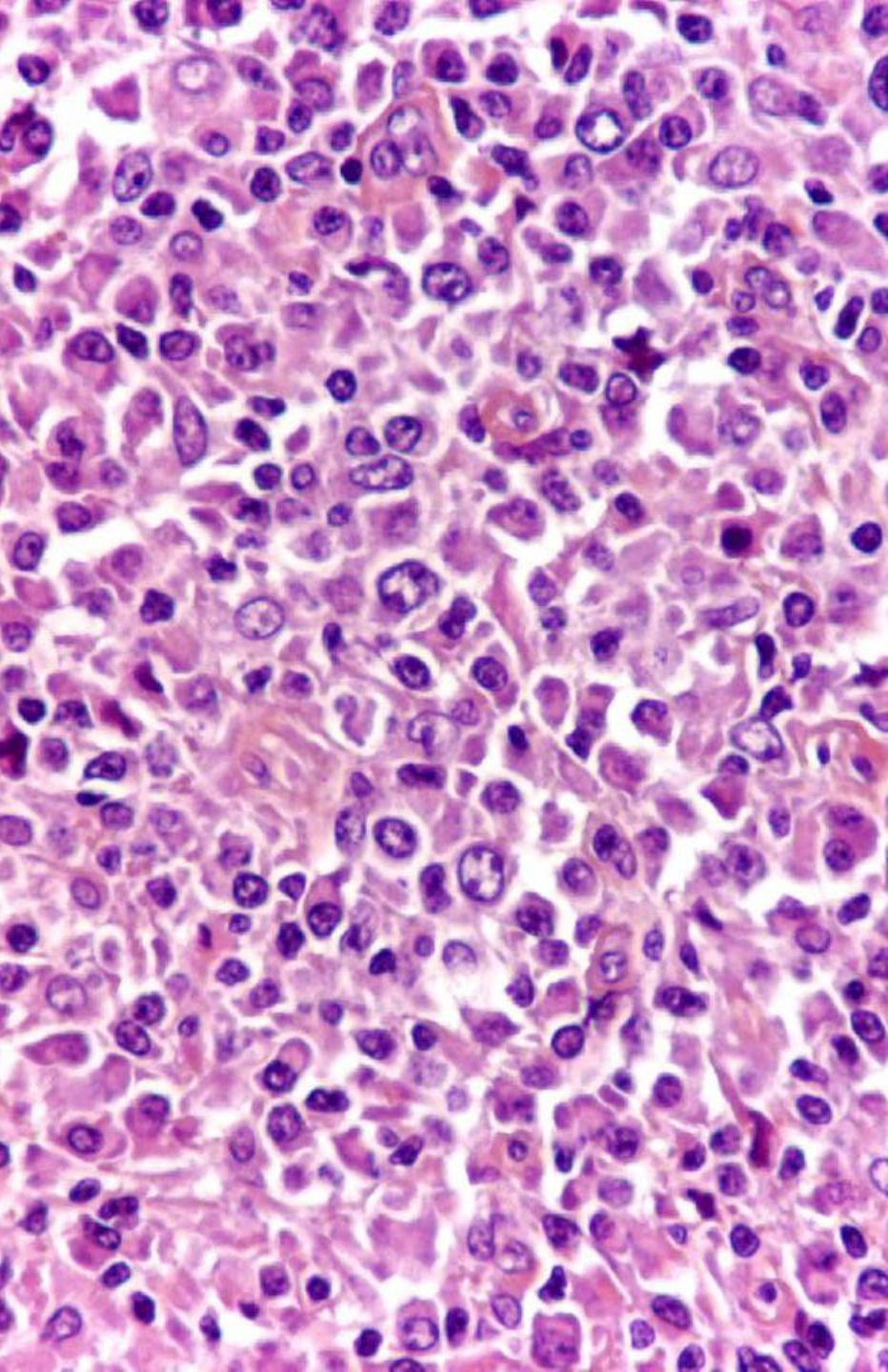
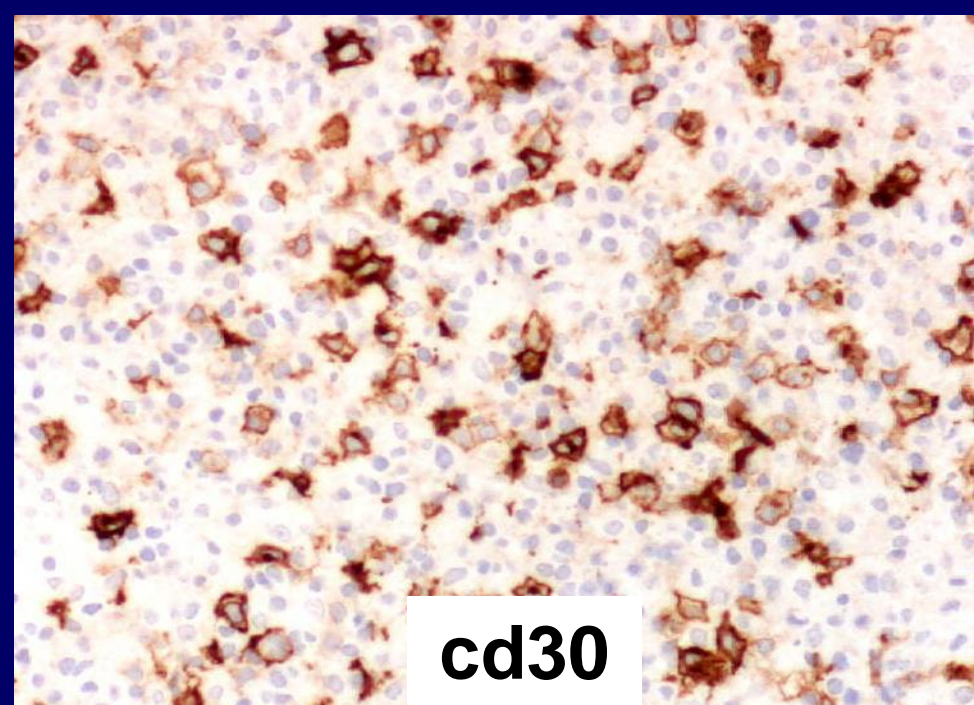
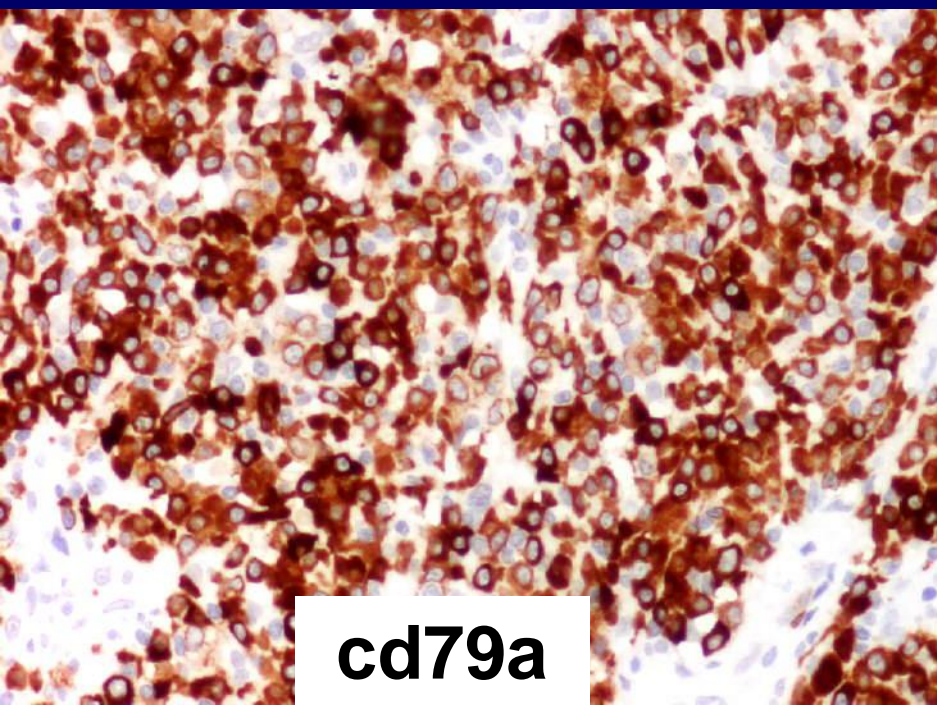
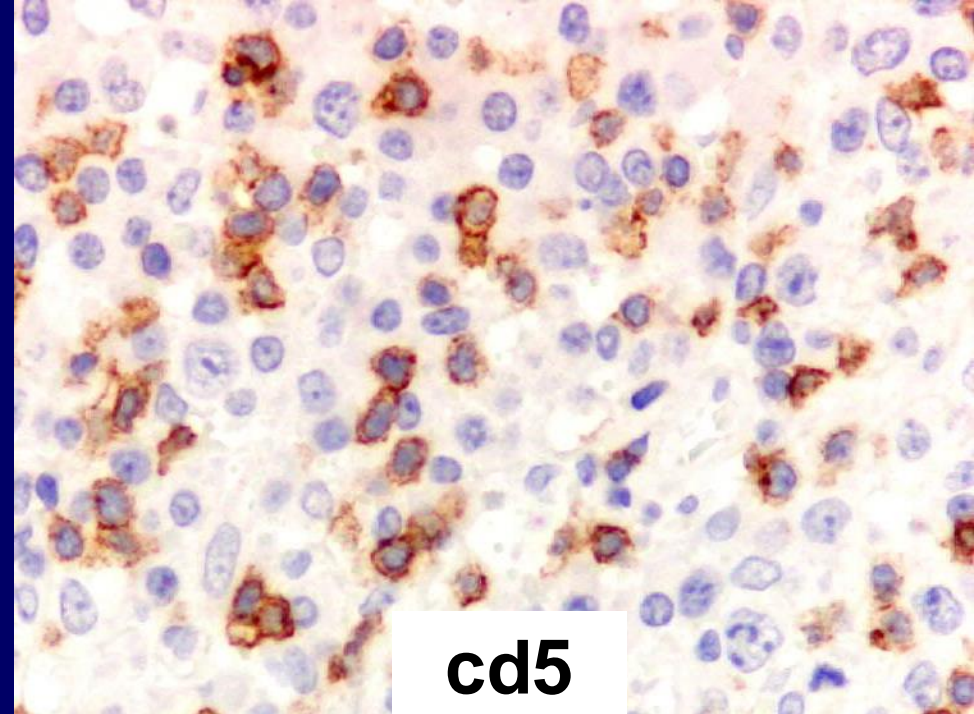
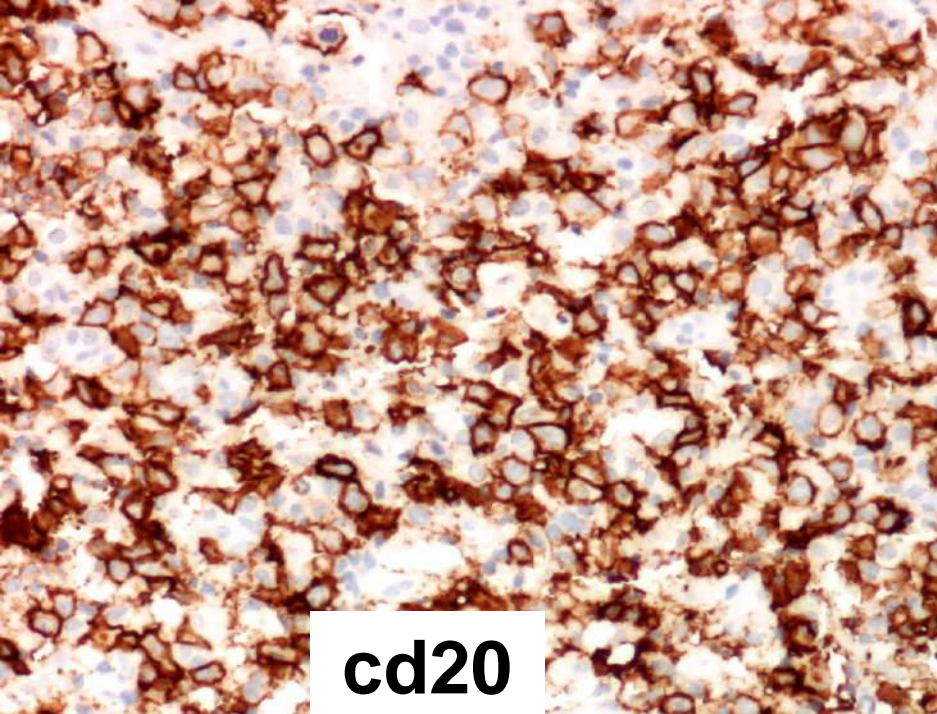
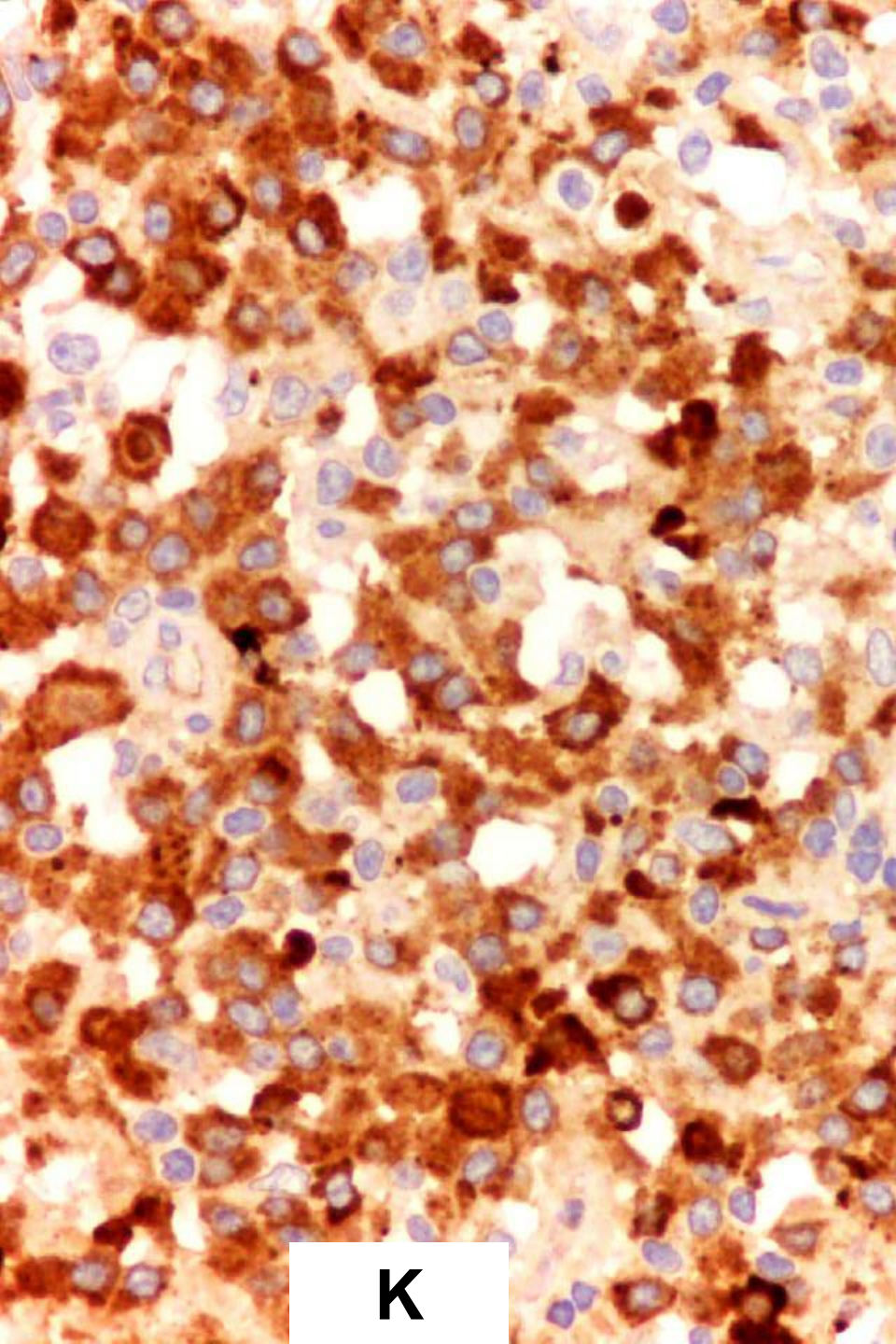


Avis Pr De mascarel

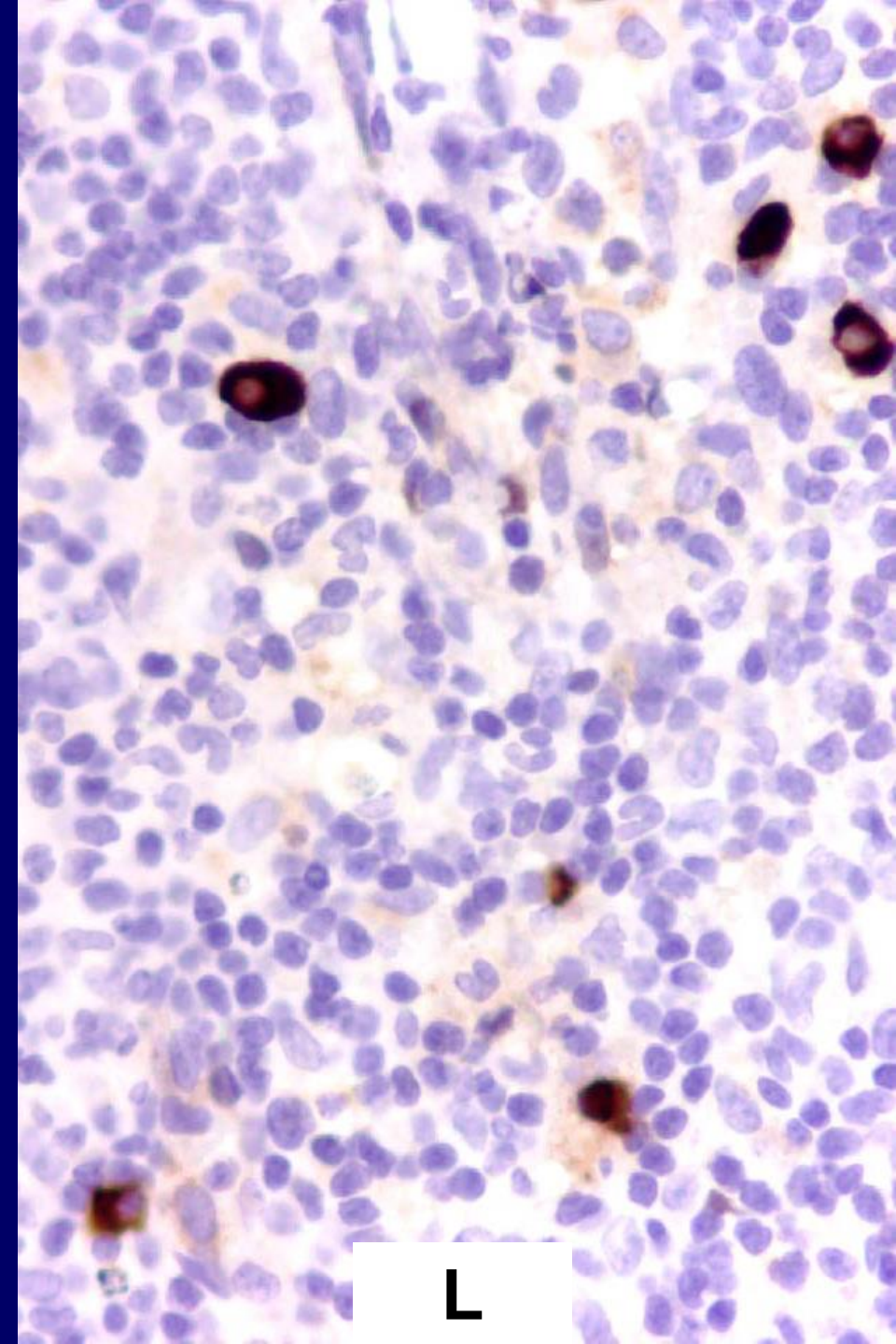








K

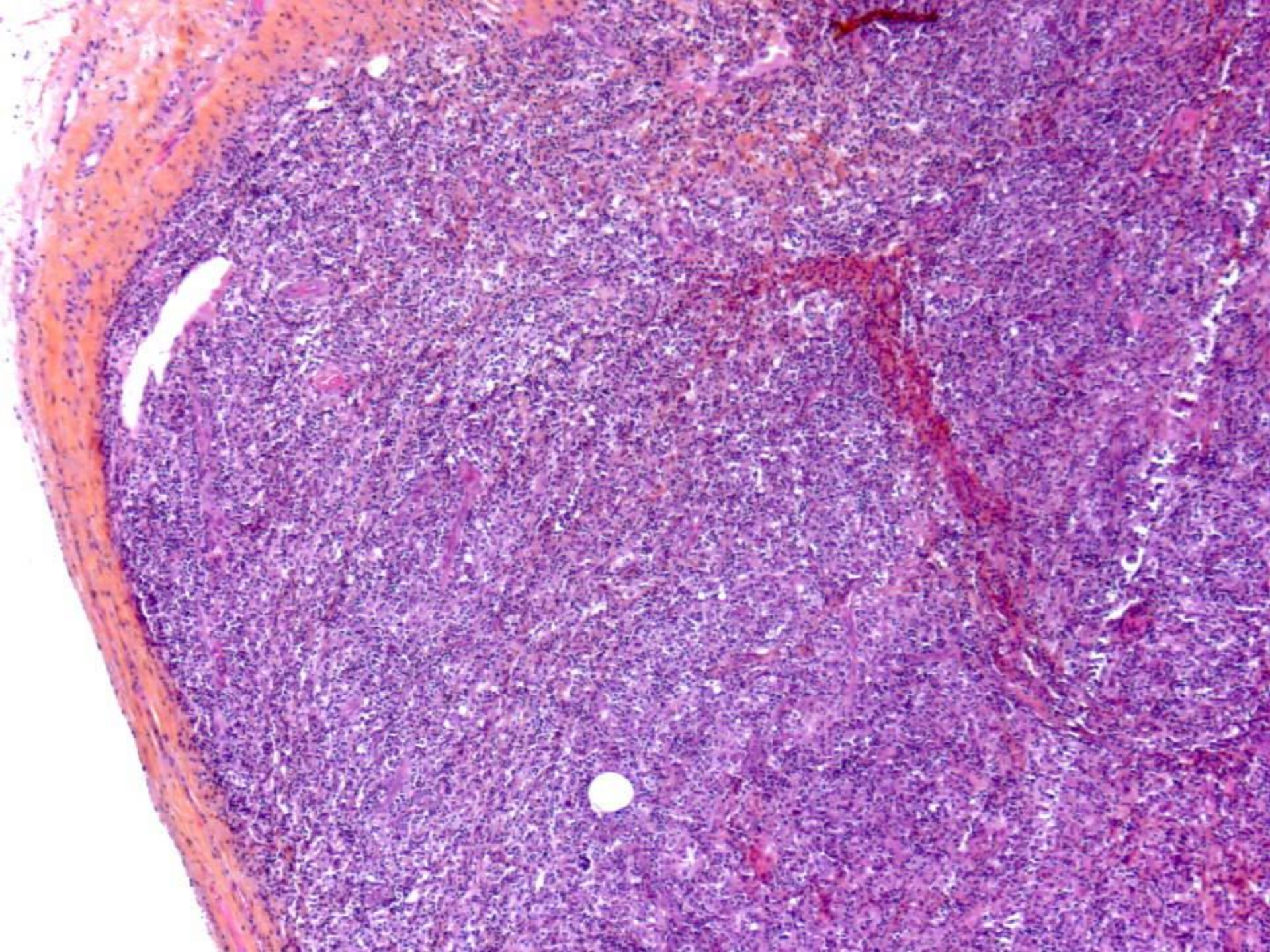


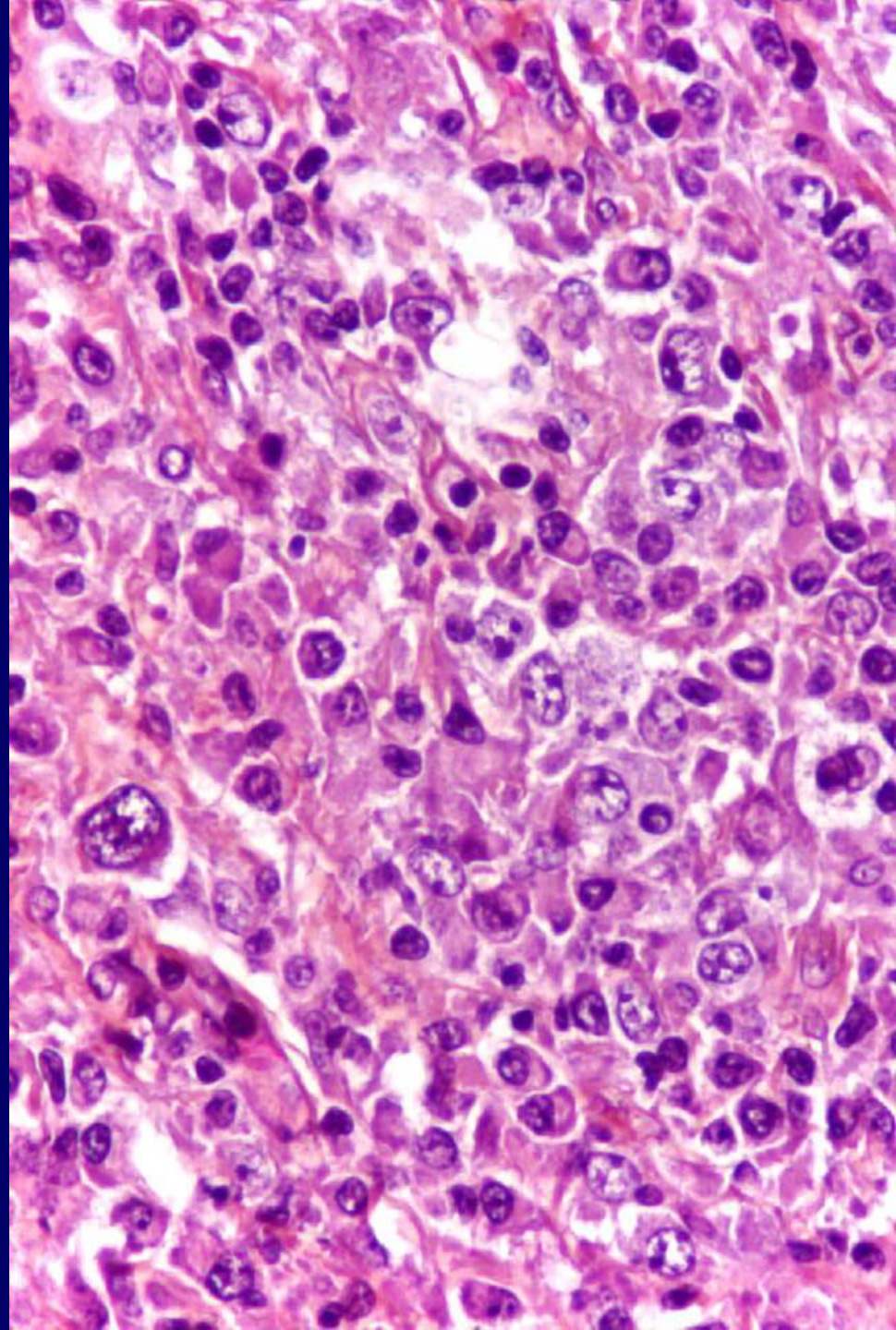
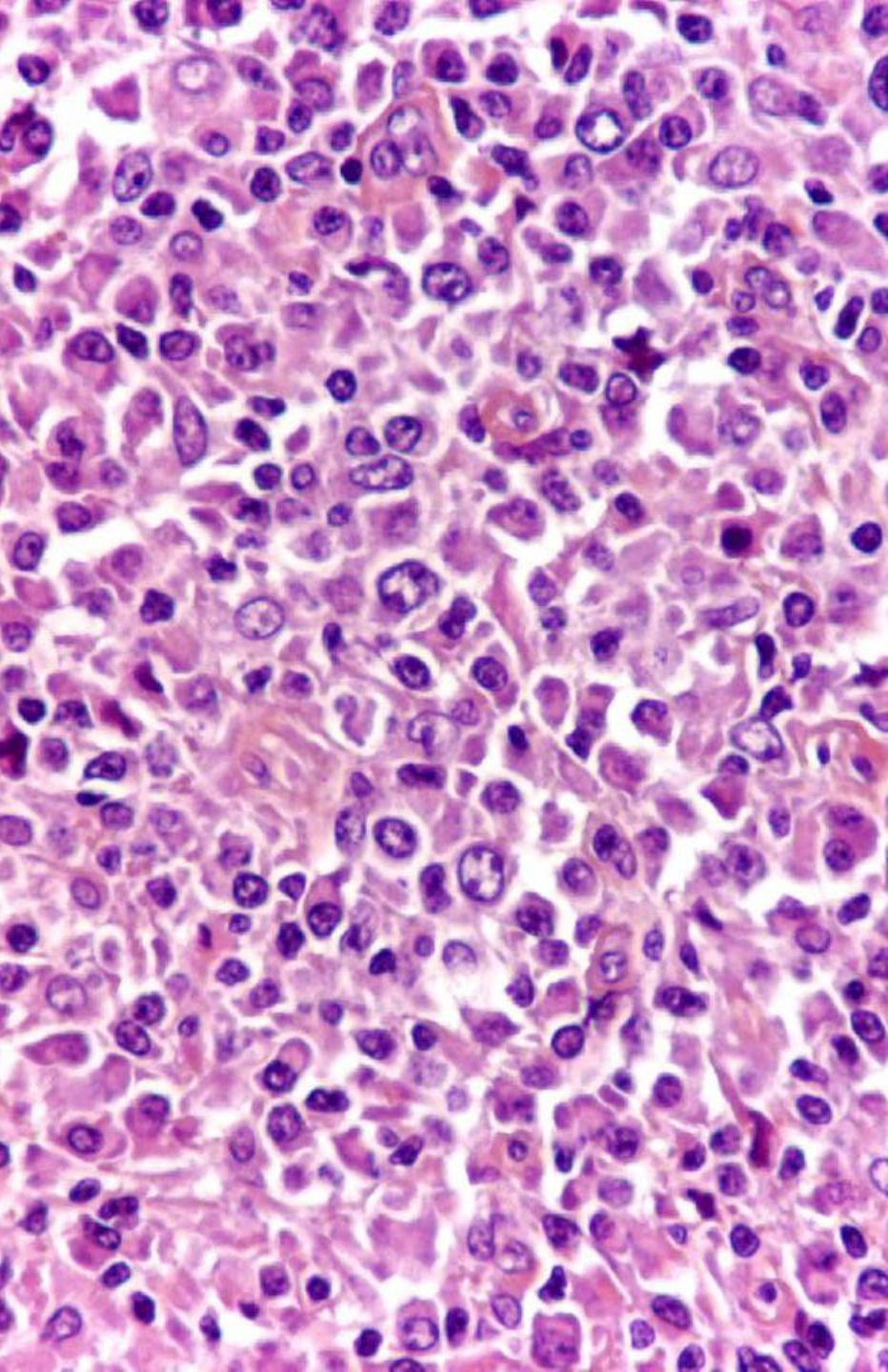
L

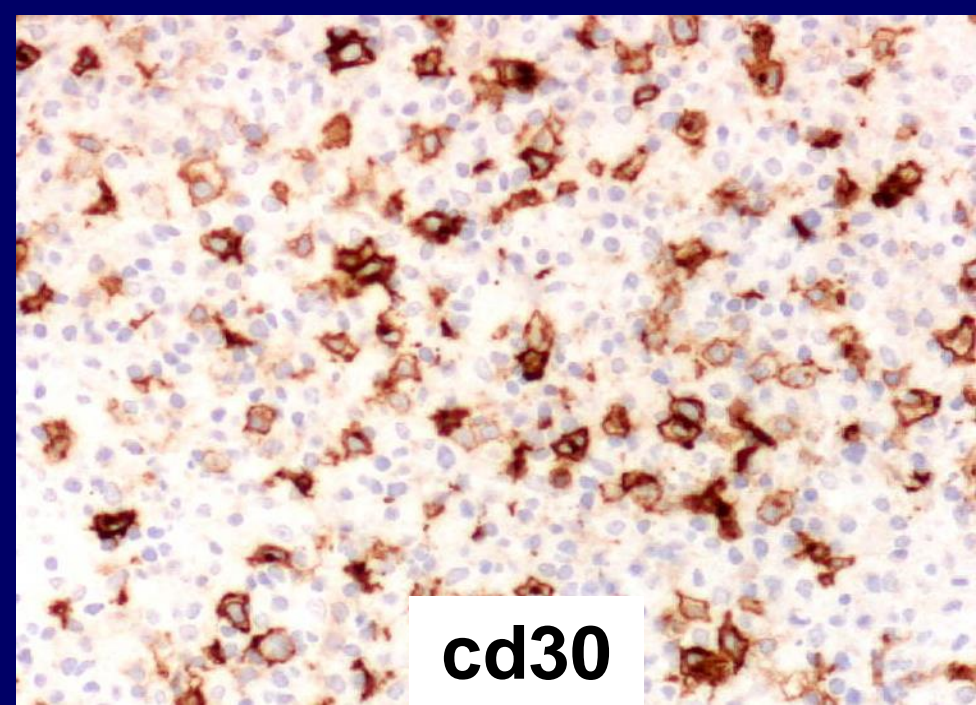
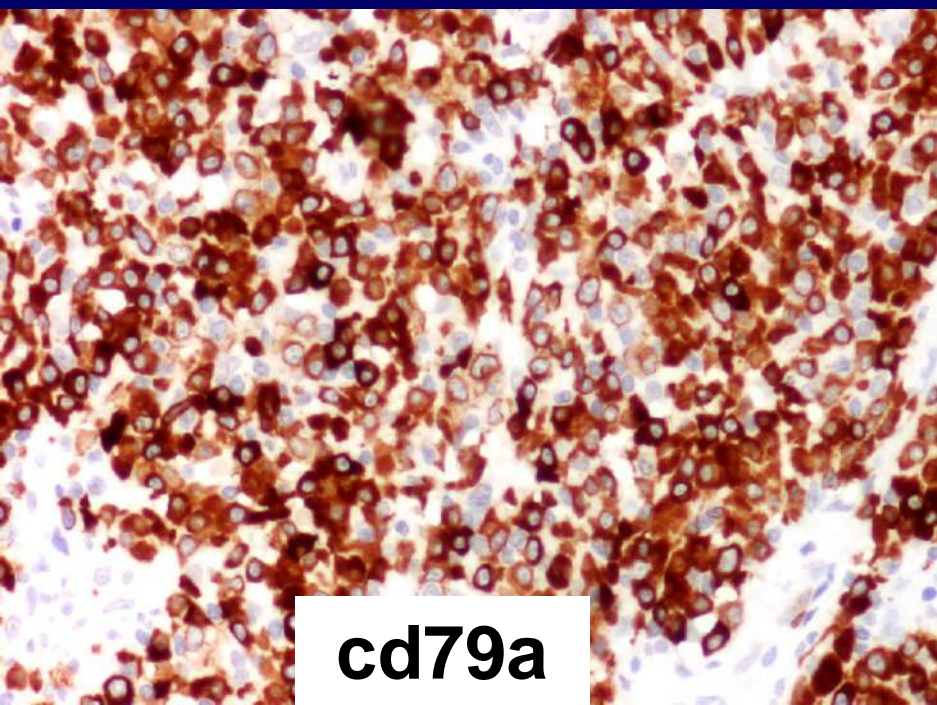
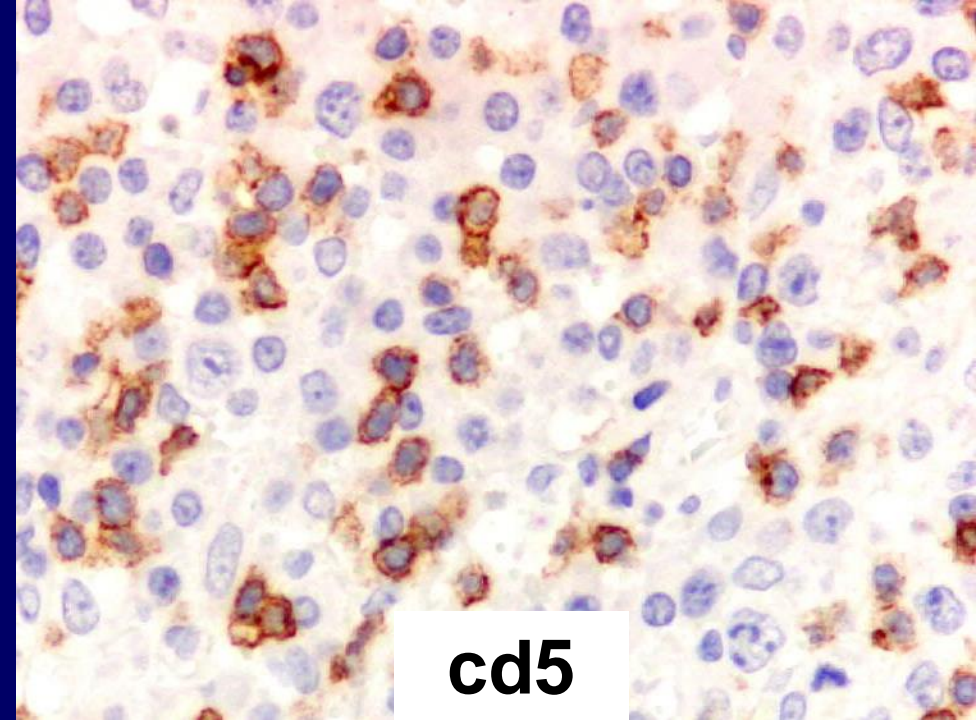
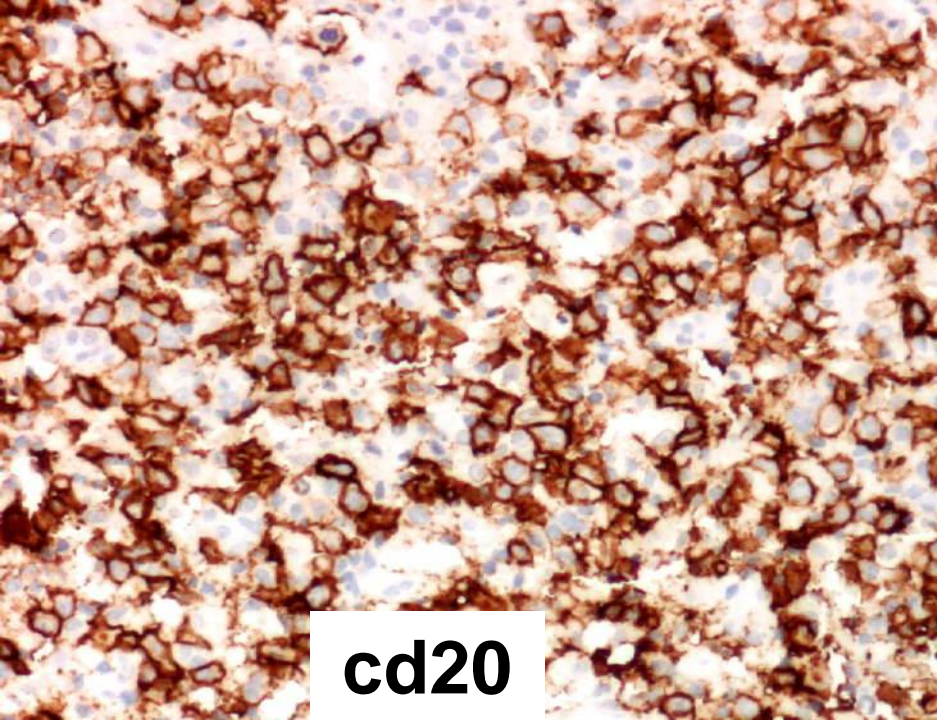
Diagnostic retenu par Pr De Mascarel

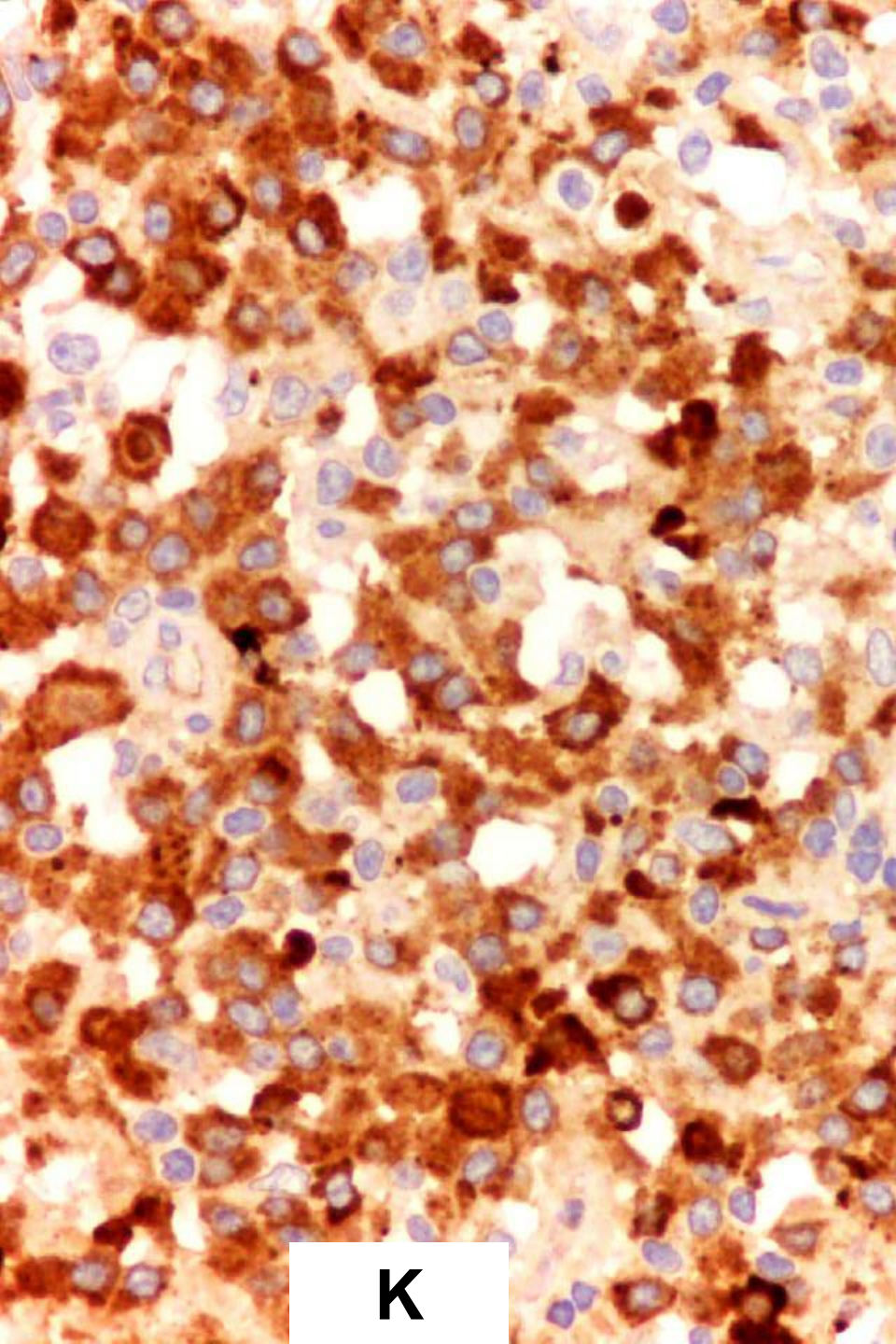
**Lymphome à grandes cellules B cd20 + ,
CD30 + à différenciation plasmocytaire
monotypique kappa**

Avis Pr De mascarel

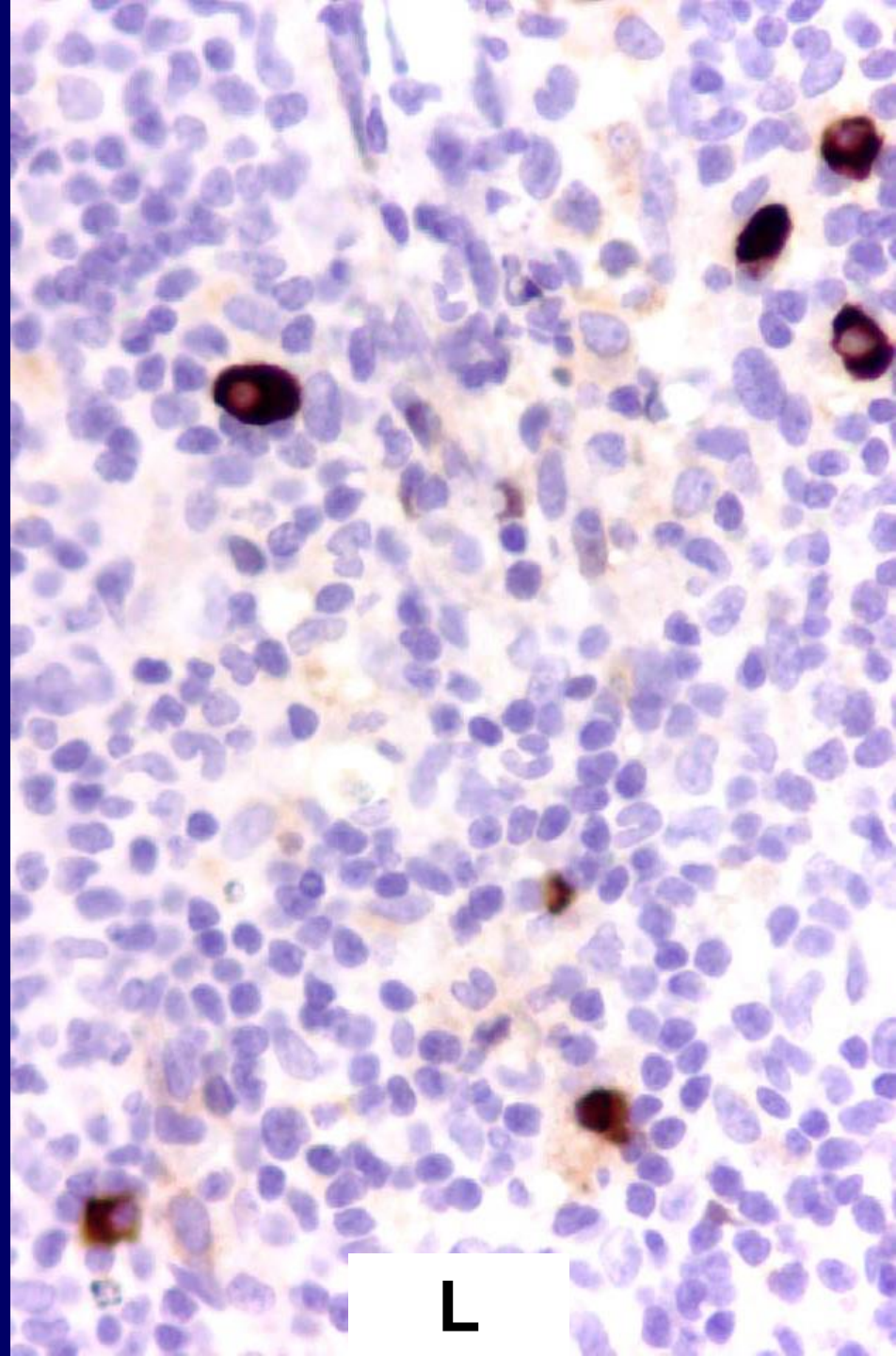








K



L

Diagnostic retenu par Pr De Mascarel

**Lymphome à grandes cellules B cd20 + ,
CD30 + à différenciation plasmocytaire
monotypique kappa**