

CAS CLINIQUE N°12

Service d'hématologie clinique Sousse
Laboratoire d'anatomie pathologique Sousse

- G.F 45 ans ayant un mycosis fongoïde diagnostiqué en 1991, traité par corticothérapie locale et générale associée à une puvathérapie.
- Consulte en octobre 1997 pour une réapparition des lésions cutanées avec tuméfaction cervicale.

EXAMEN PHYSIQUE I

- Deux plaques érythémato-papulo-squameuses à bordures nettes et à contours polycycliques, l'une au niveau du sein droit et l'autre au niveau de la région inguinale.
- Adénopathie cervicale parotidienne droite de 25 mm de grand axe.

EXAMENS PARACLINIQUES

I

- Bilan en octobre 1997:

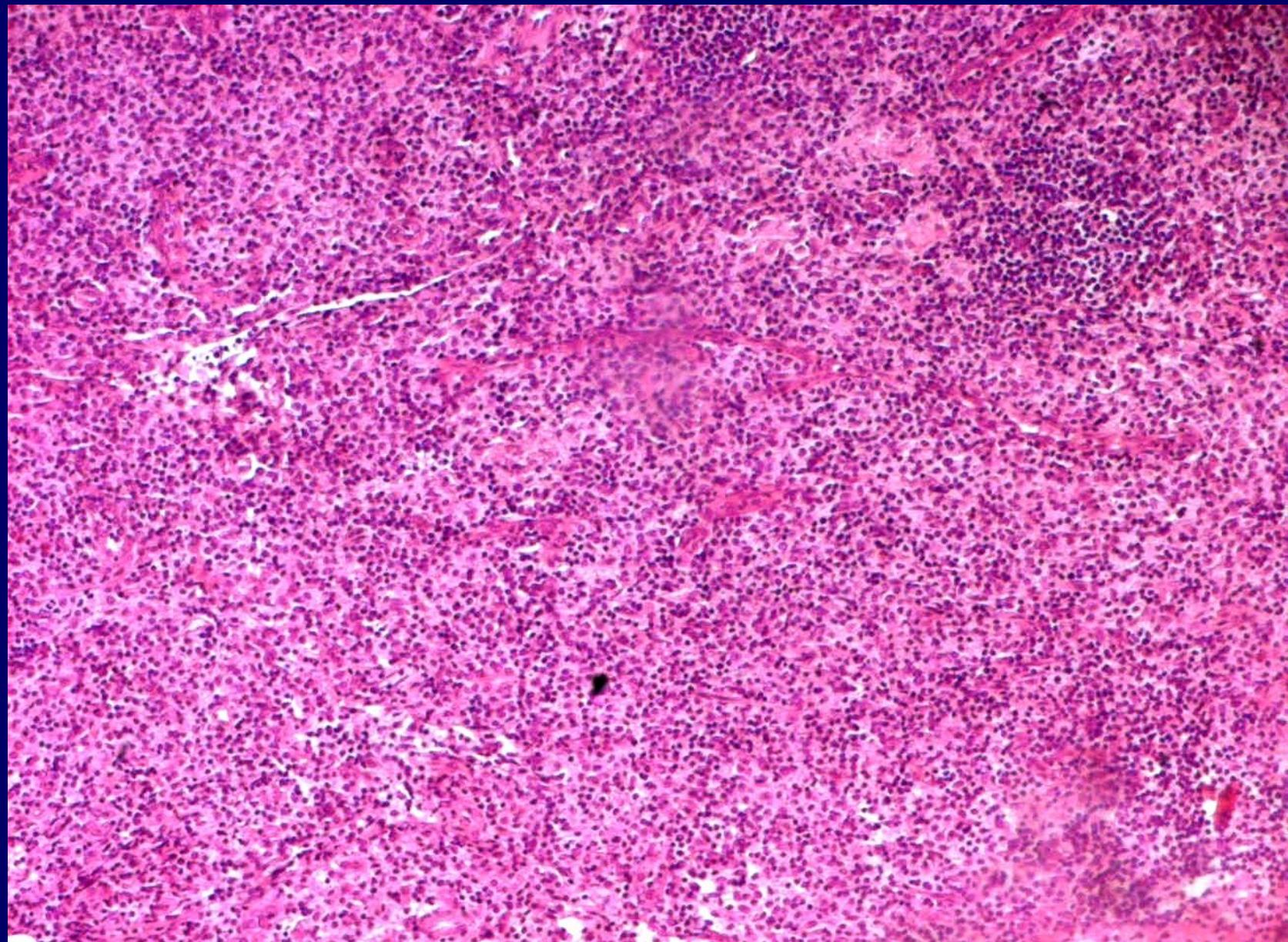
LDH : 2 fois la normale

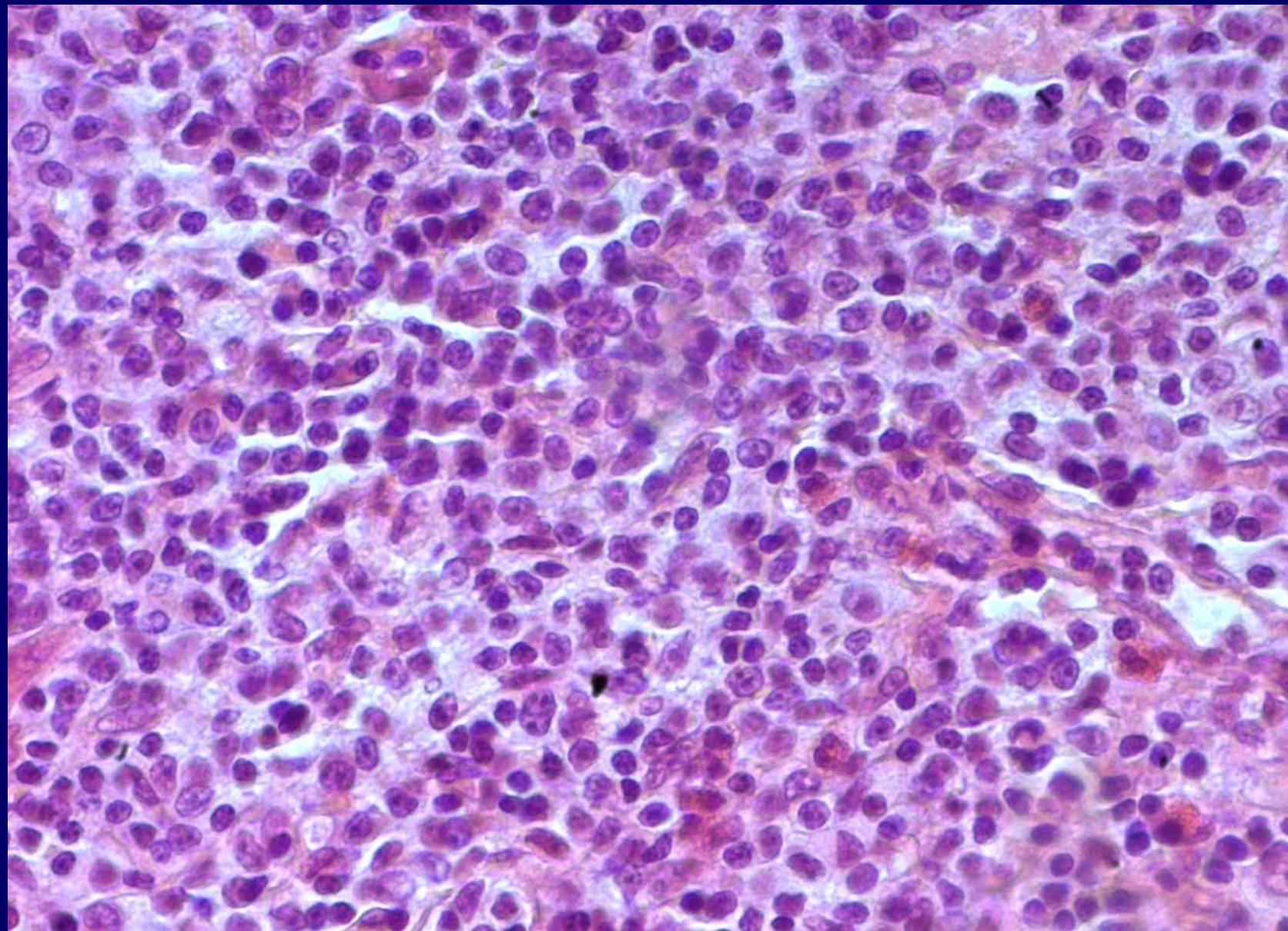
Recherche de cellules de Sézary :
négative

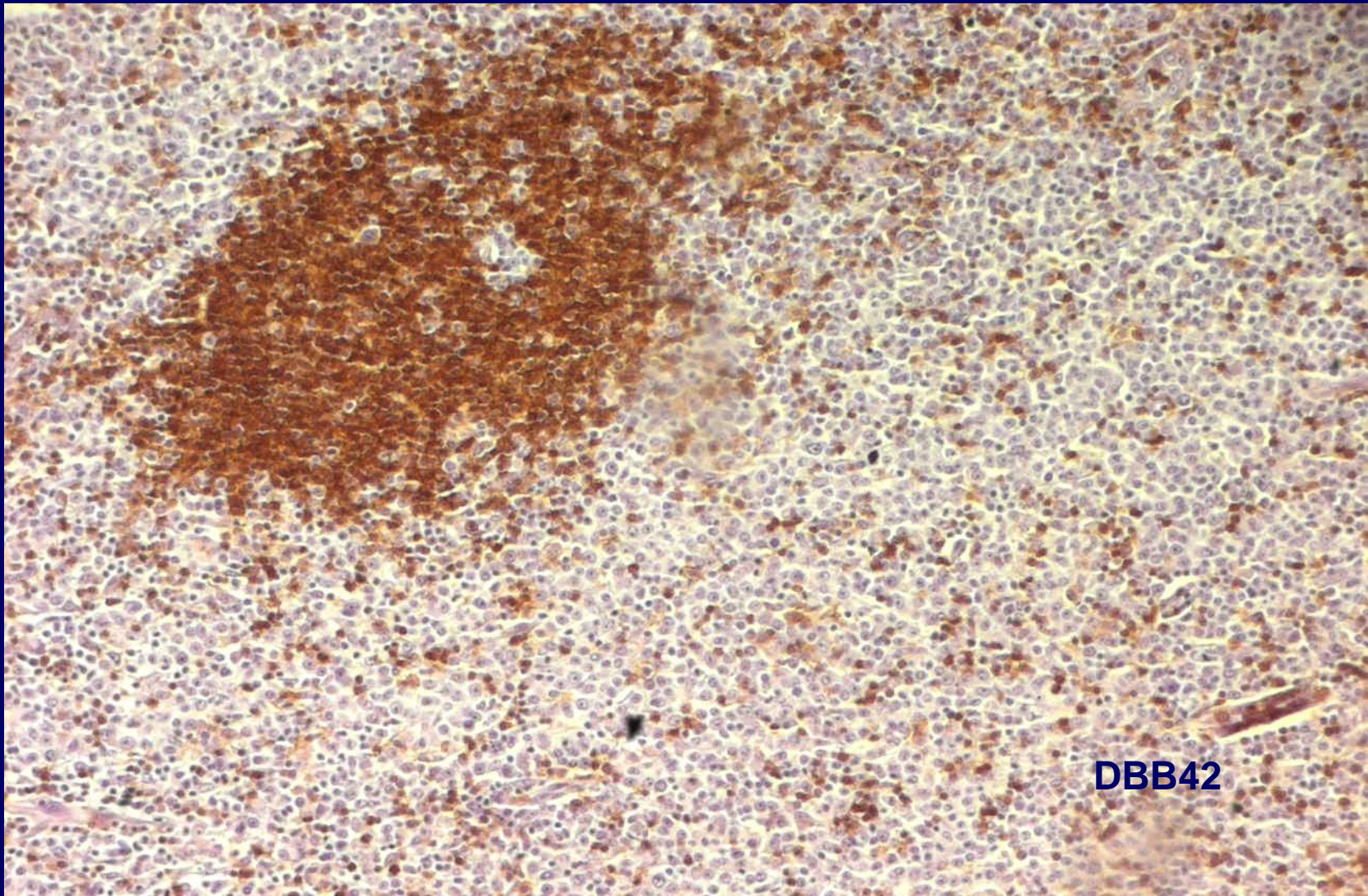
EXAMENS PARACLINIQUES

II

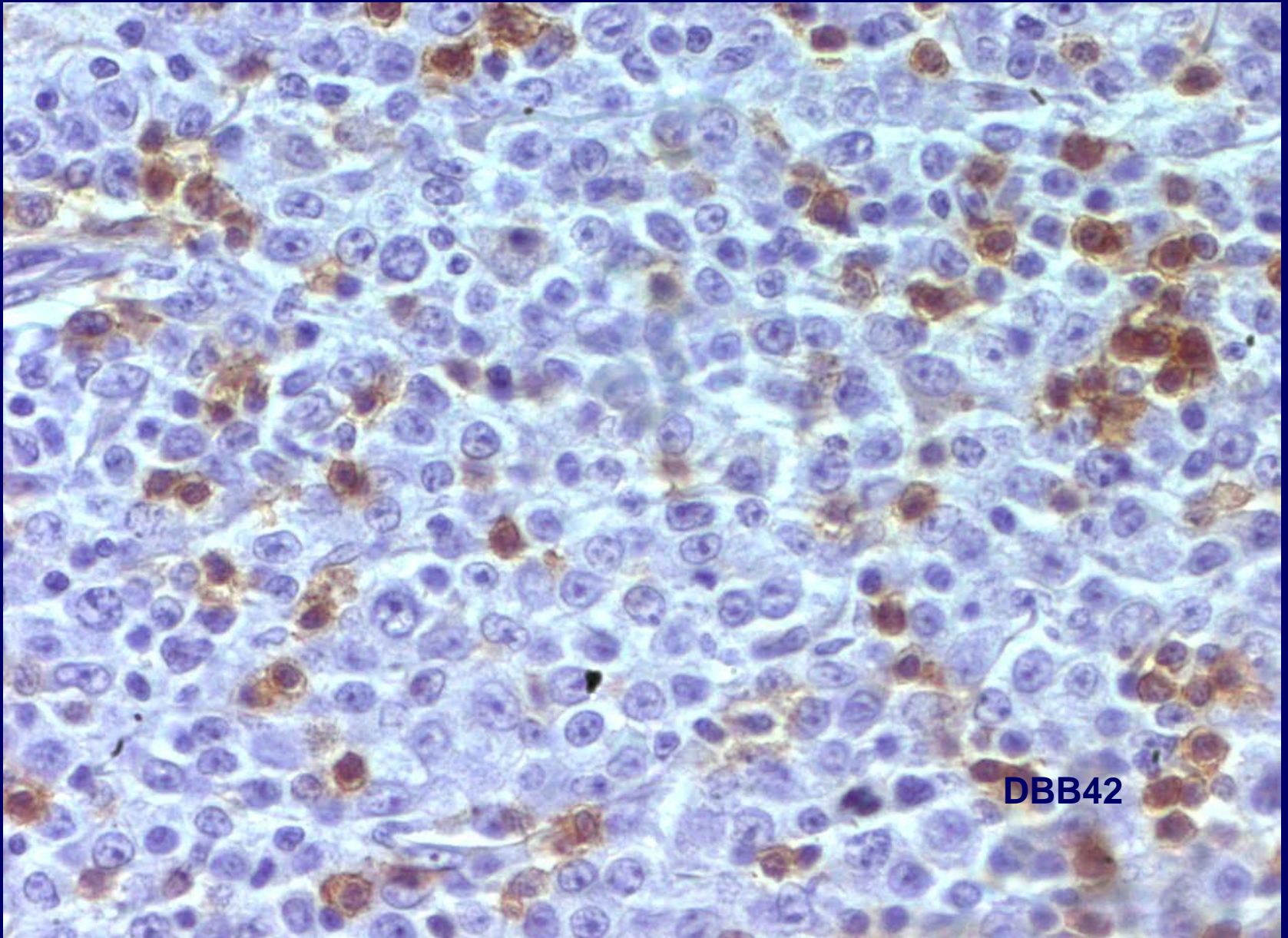
- Biopsie ganglionnaire



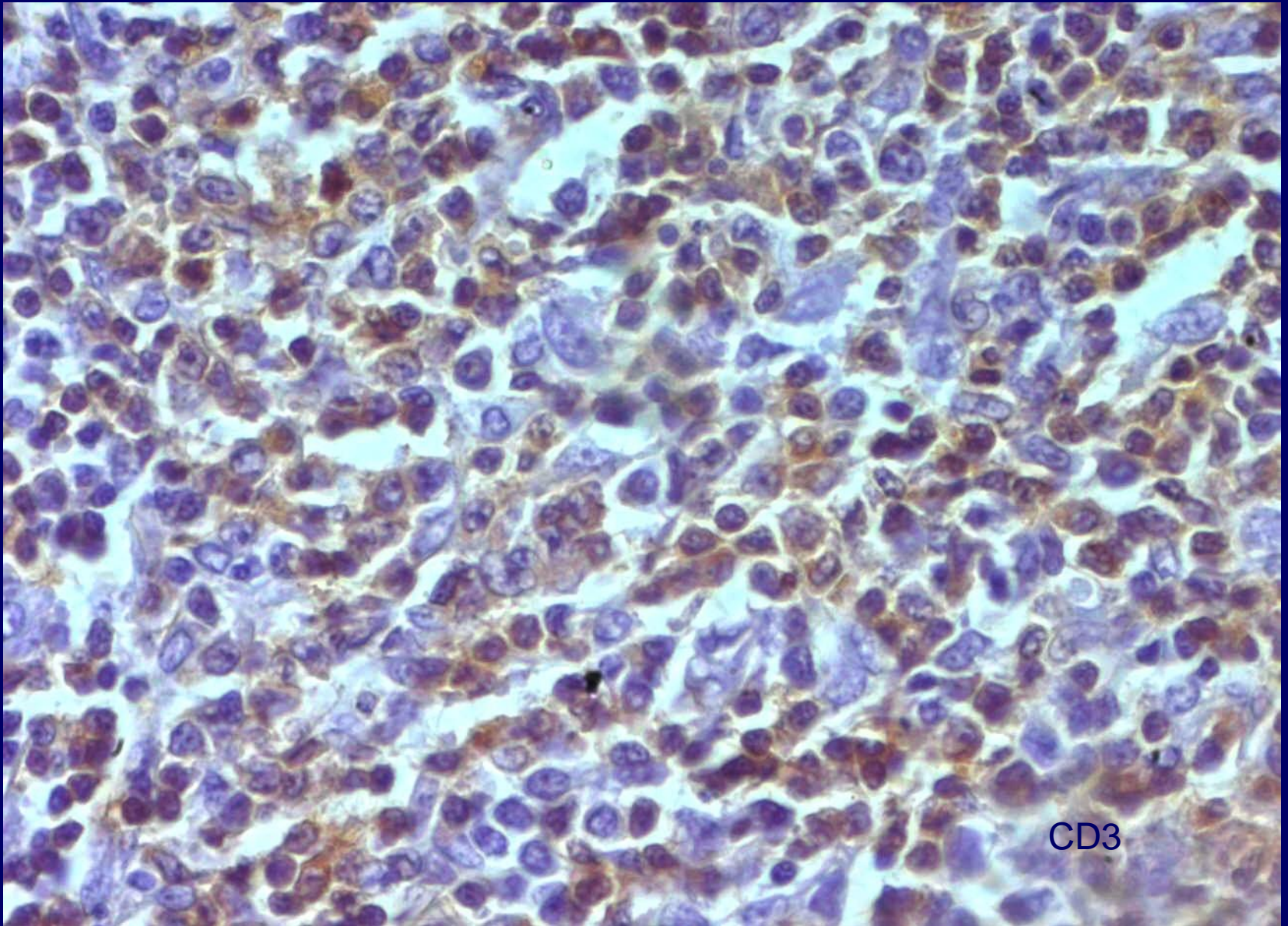




DBB42



DBB42



EXAMENS PARACLINIQUES III

- Biopsie ostéo-médullaire : absence d'infiltration tumorale
- Scanner thoraco- abdomino-pelvien : normal

TRAITEMENT

- Chimiothérapie selon le protocole LNH93.
- Evolution : Rémission complète.

EVOLUTION I

- En mars 1998:
- Réapparition de nouvelles lésions cutanées alors que la patiente recevait encore les cures (VP16- Endoxan), avec obtention de la rémission

EVOLUTION II

- En mai 1999:
- Apparition de lésions érythémateuses au niveau du visage.
- Une biopsie cutanée a conclu à un mycosis fongoïde
- Traitement par Caryolysine locale, dermocorticoïdes, Sorriatane pommade et puvathérapie
- Évolution favorable

EVOLUTION III

- En Août 2007:

Apparition de nouvelles lésions au niveau de la fosse iliaque avec adénopathie inguinale gauche

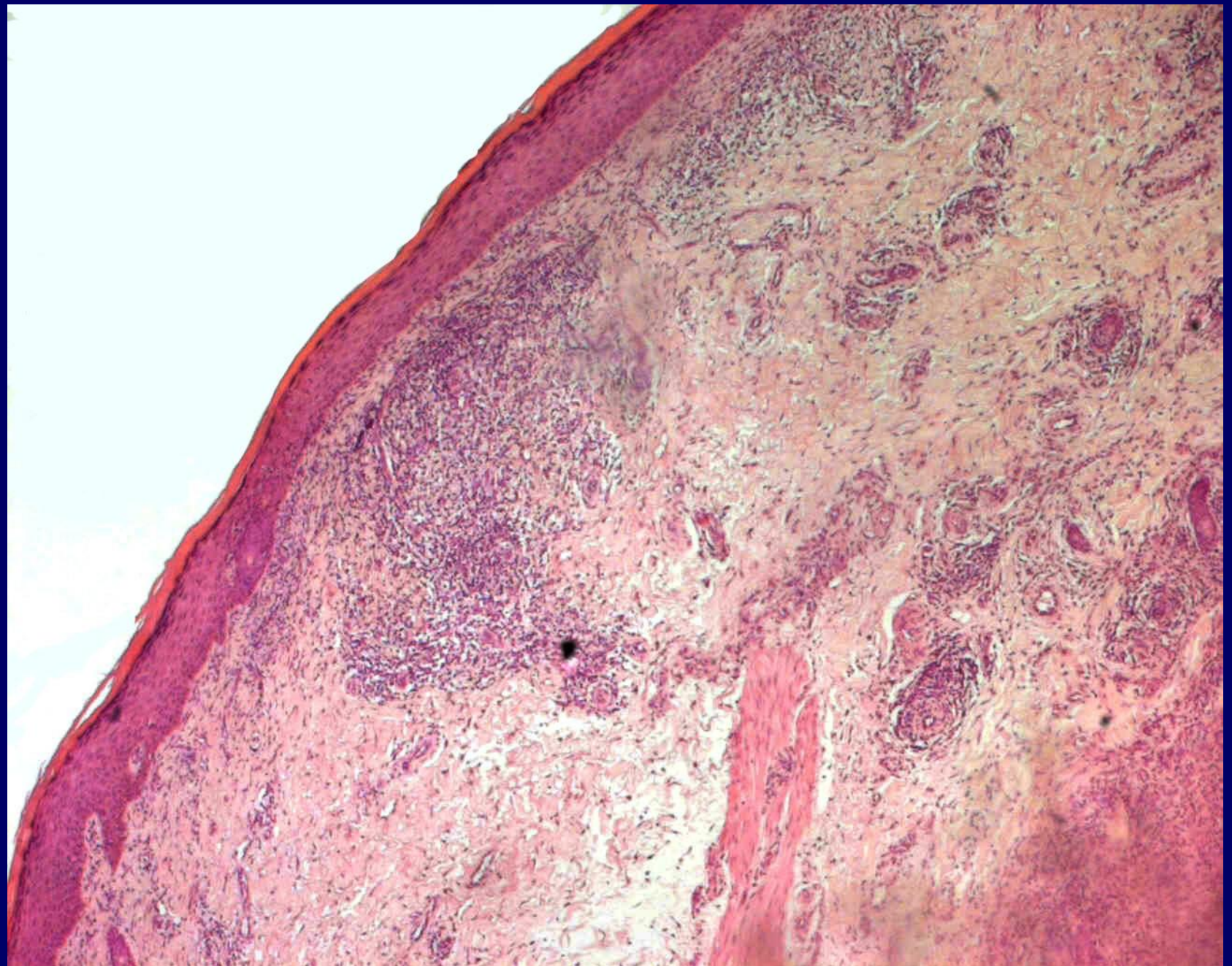
EXAMEN PHYSIQUE II

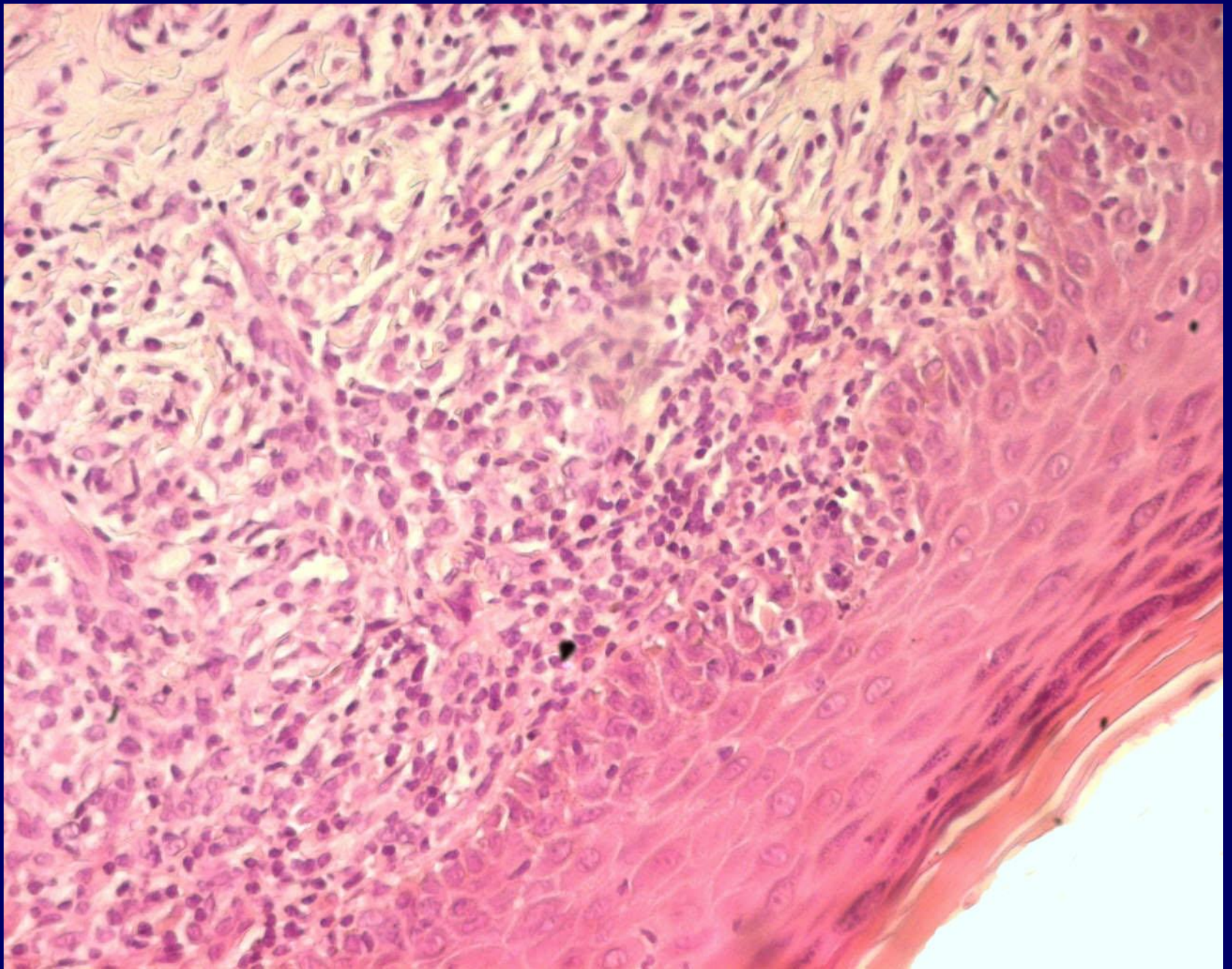
- Plaque érythémato- squameuse de 20 cm de grand axe avec au centre deux formations papuleuses infiltrées.
- Adénopathie inguinale gauche de 2 cm de taille.

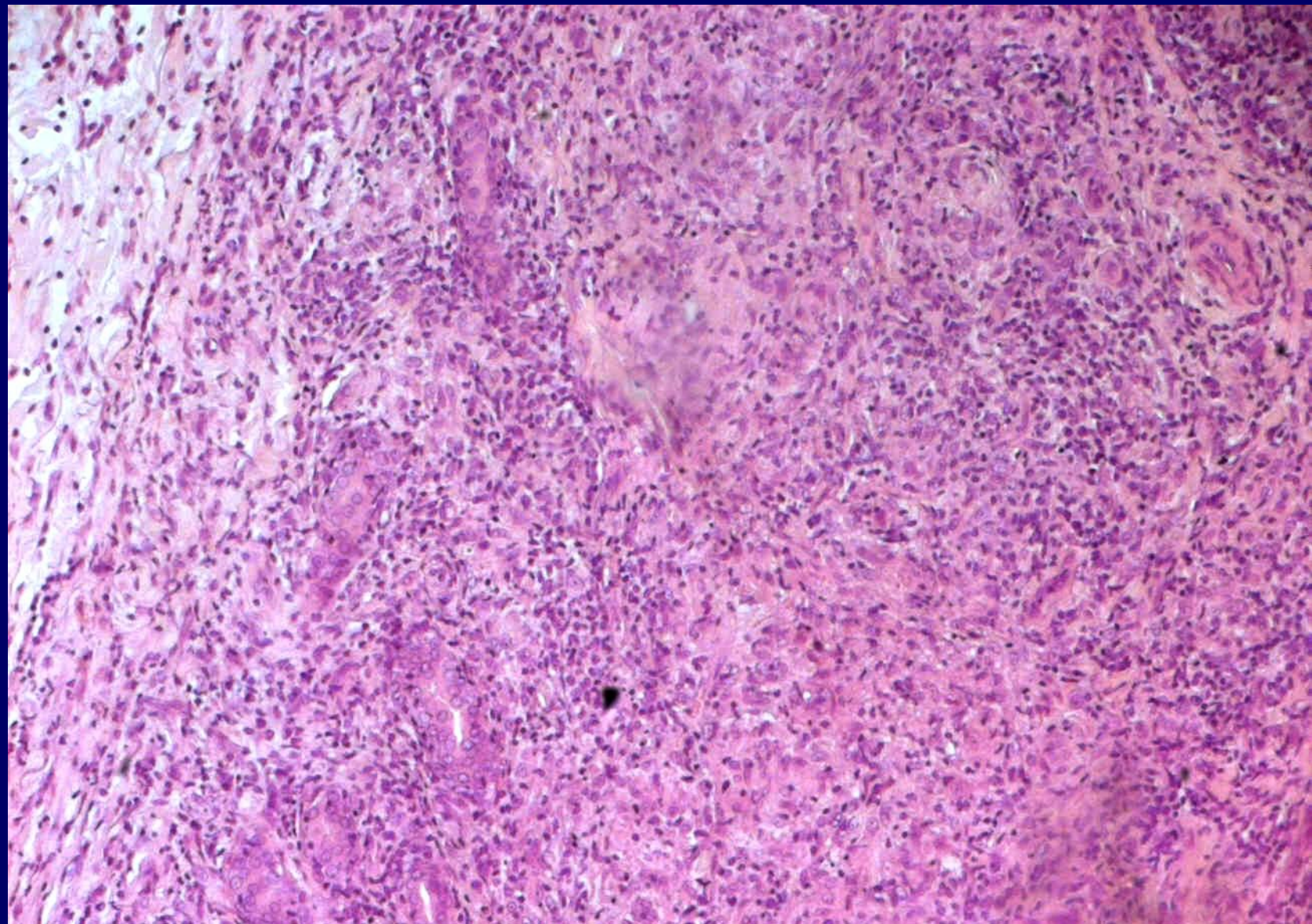
EXAMENS PARACLINIQUES IV

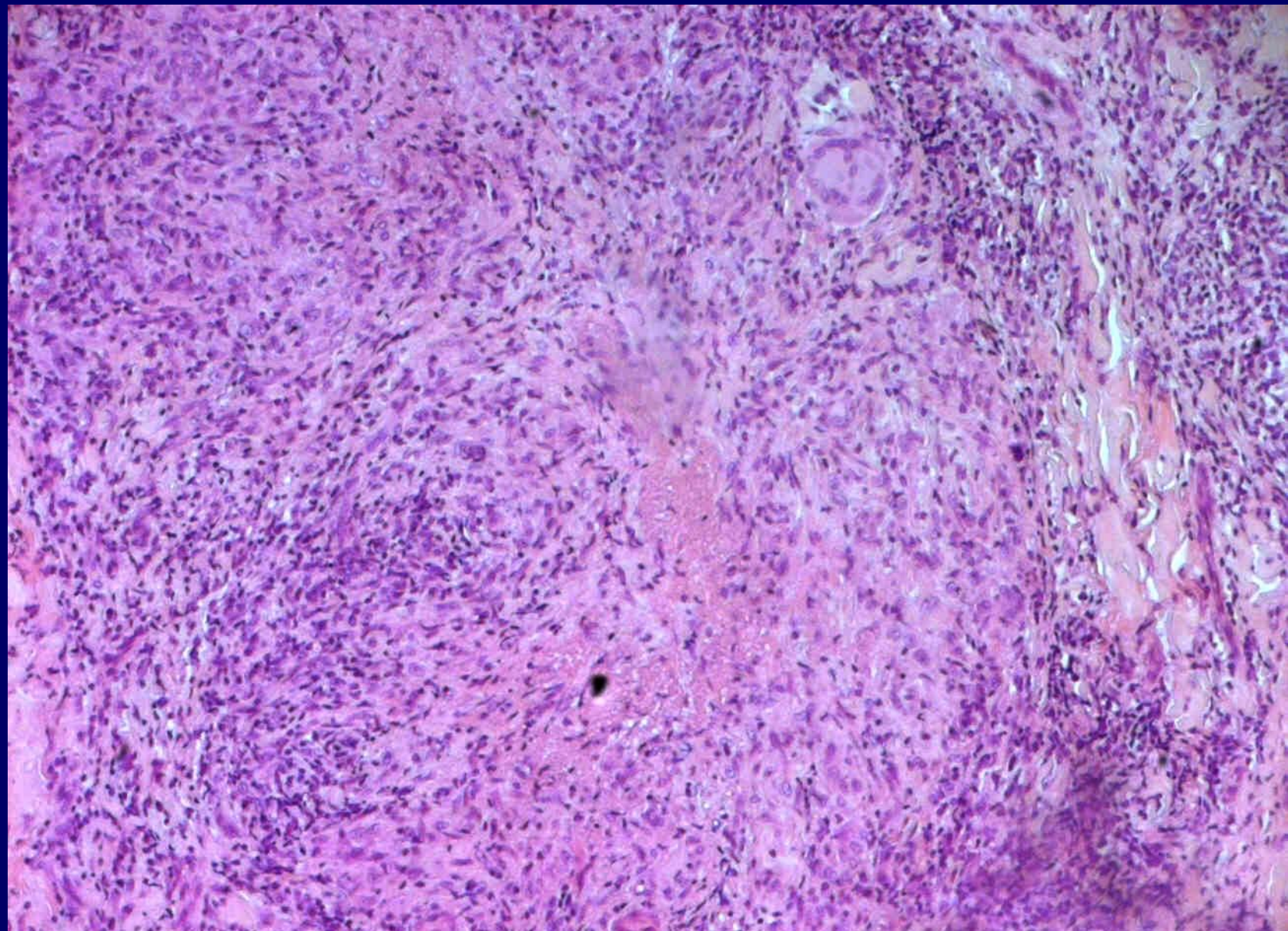
Bilan en 2007:

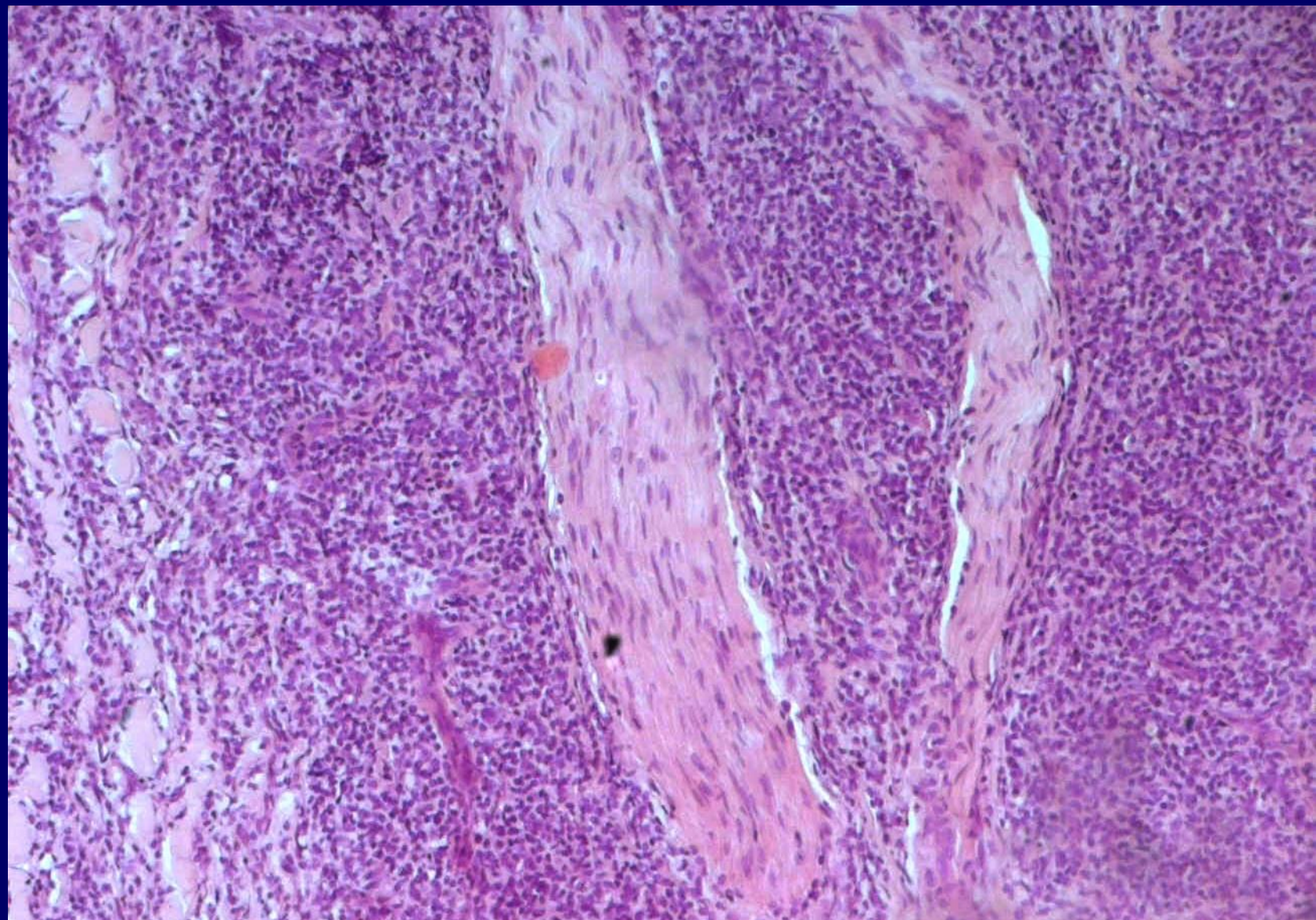
- LDH : normales
- Recherche de cellules de Sézary: négative
- Scanner : normal en dehors de l'adénopathie inguinale.
- BOM : non envahie

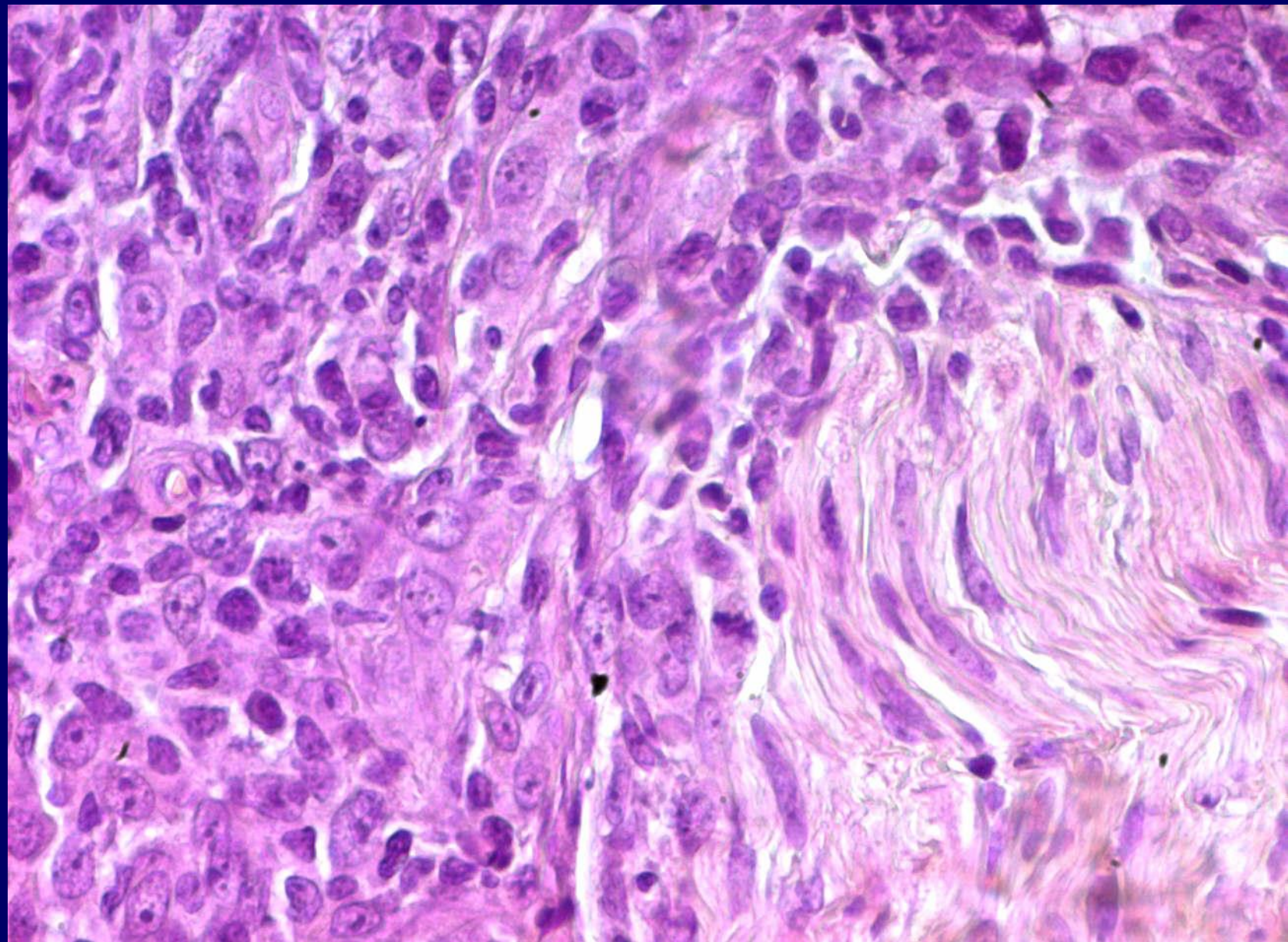


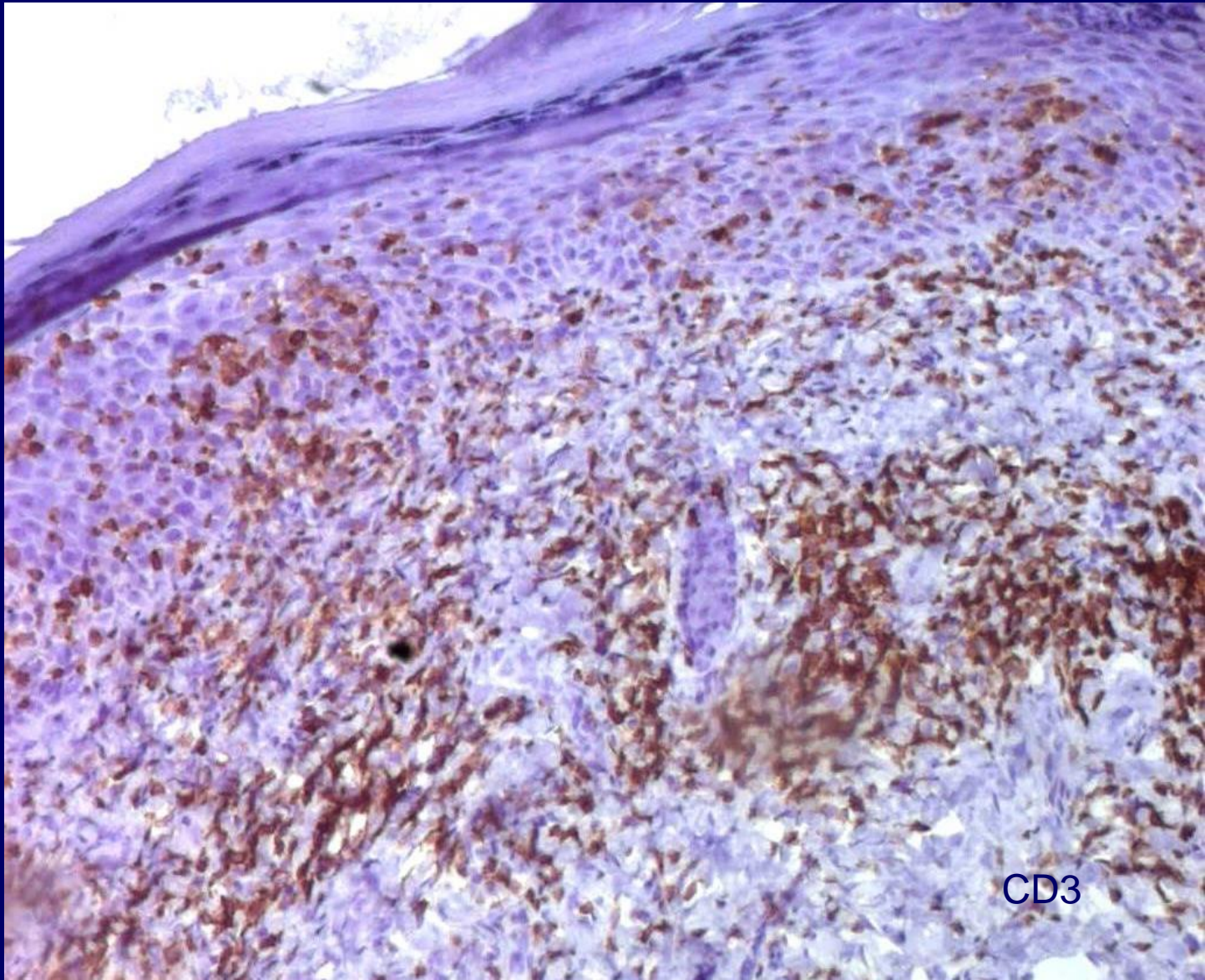


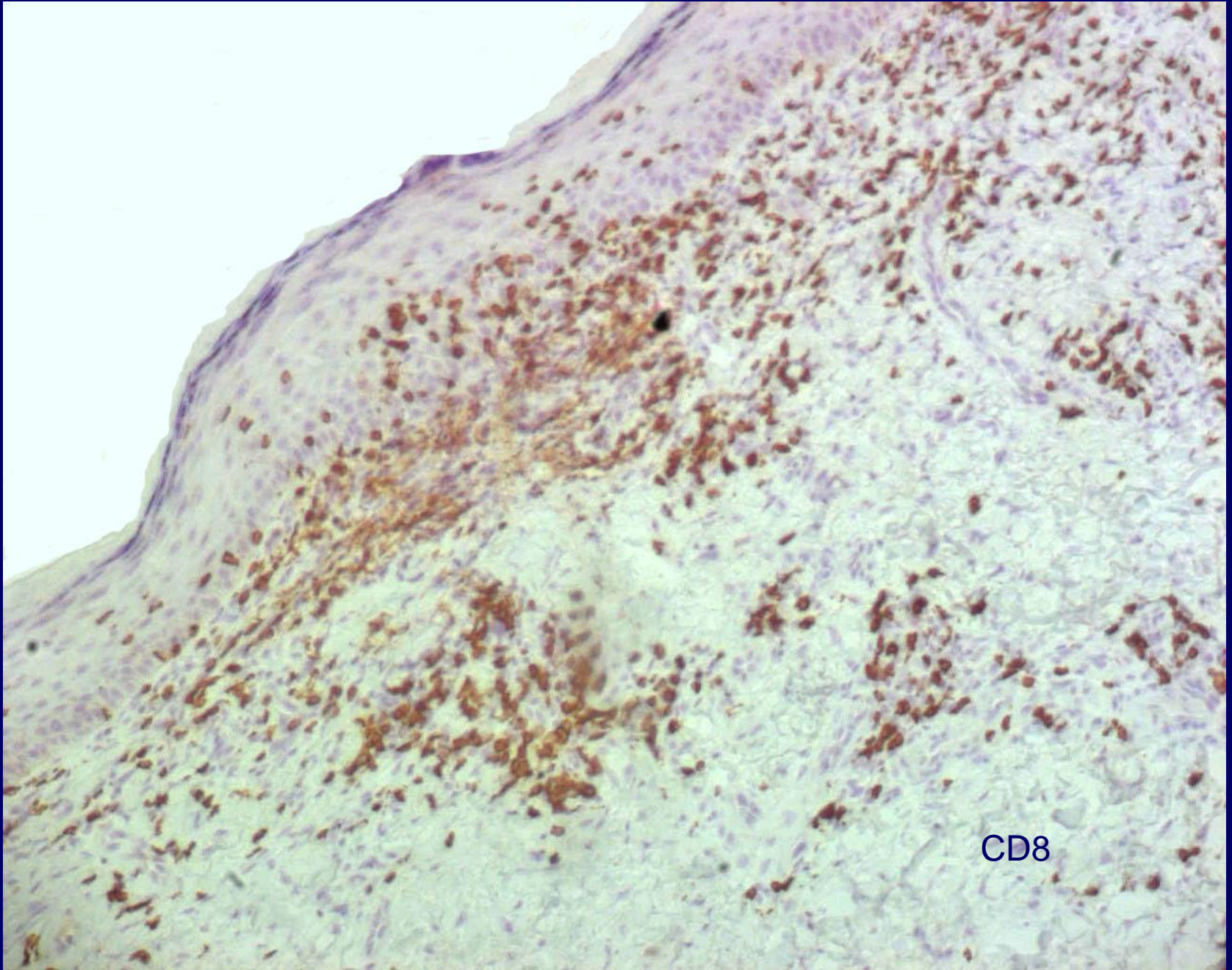




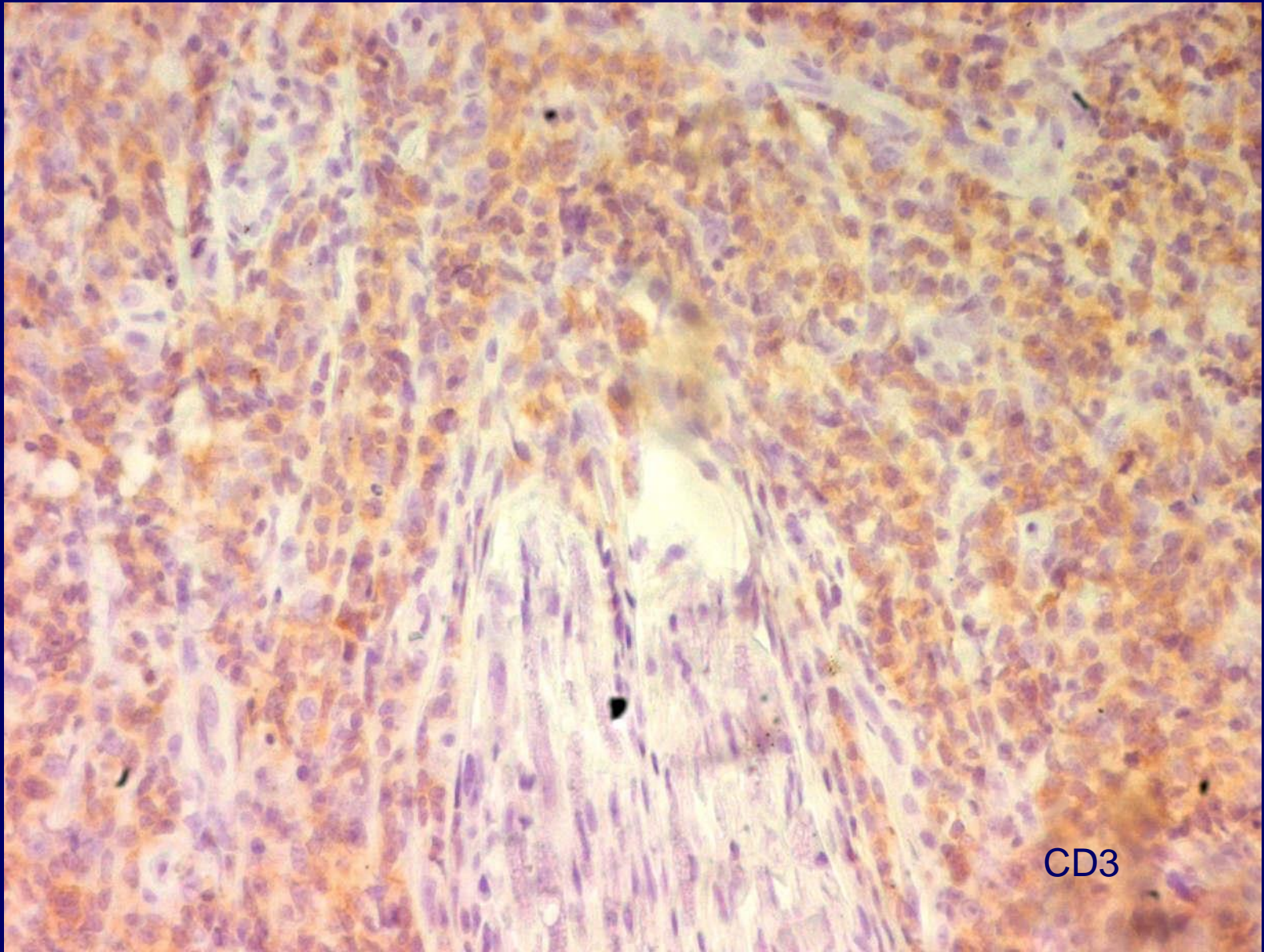




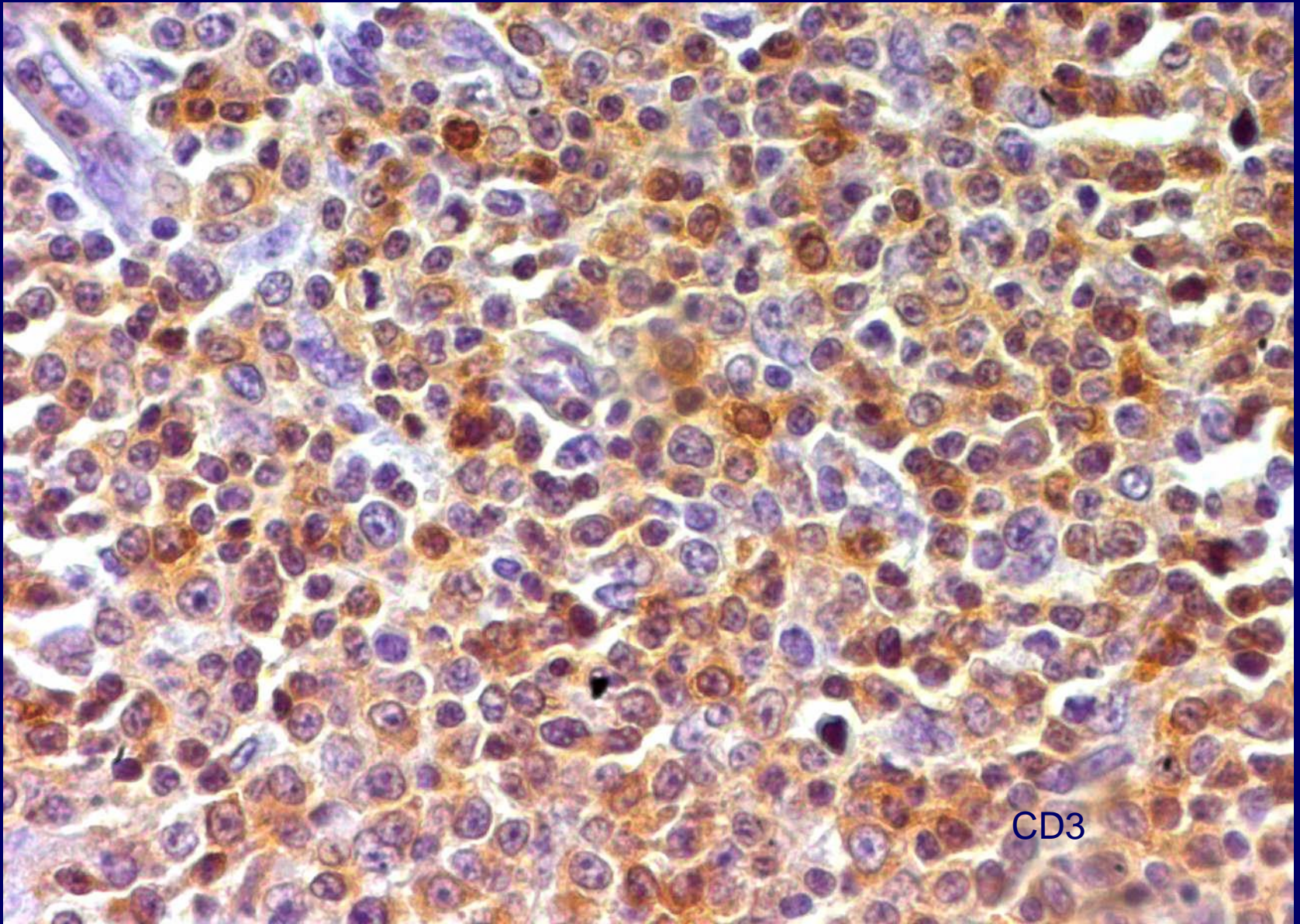




CD8



CD3



CD3

HYPOTHESES DIAGNOSTIQUES

- MF transformé?
- MF granulomateux?
- Tuberculose?

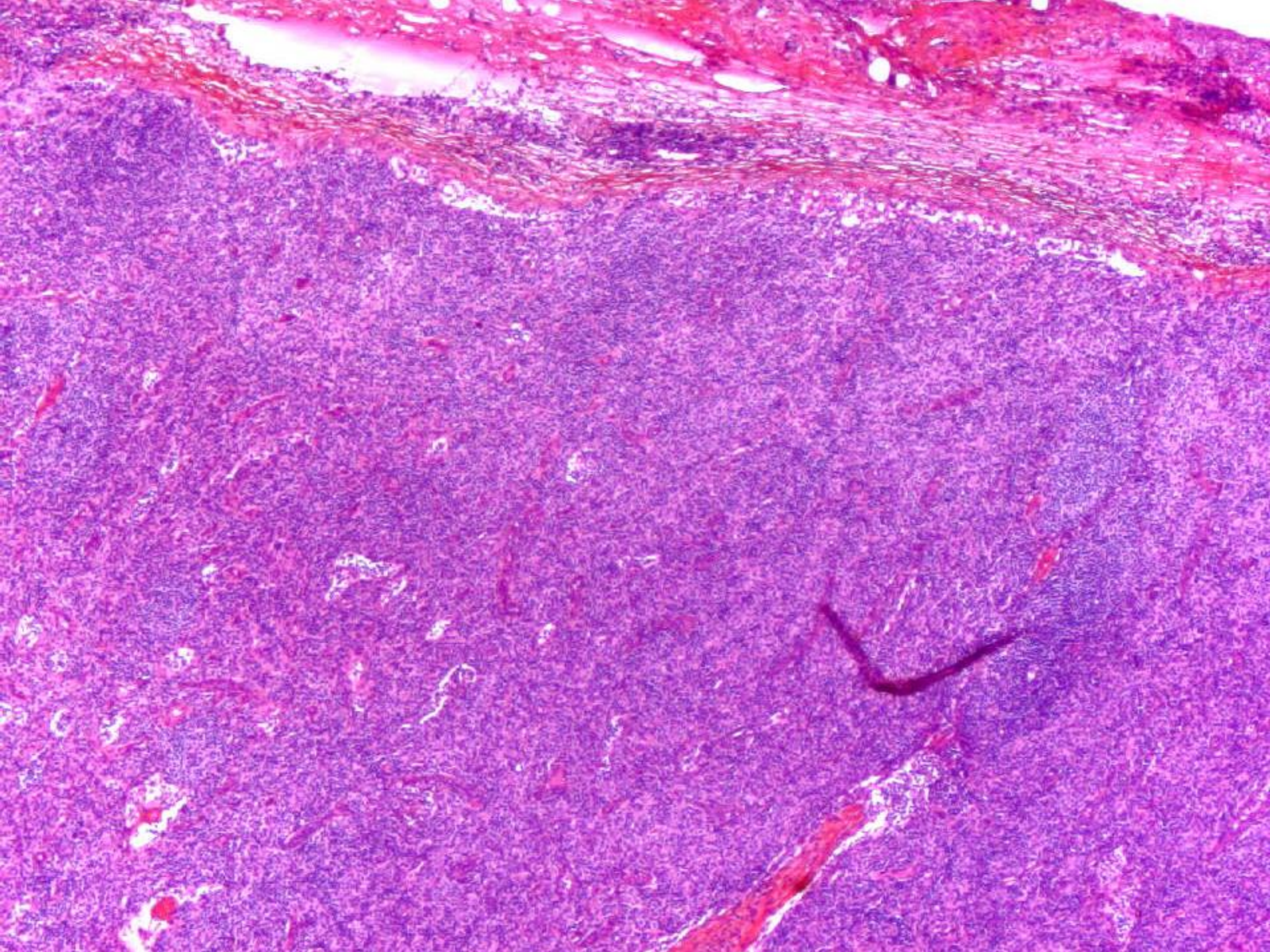
EVOLUTION IV

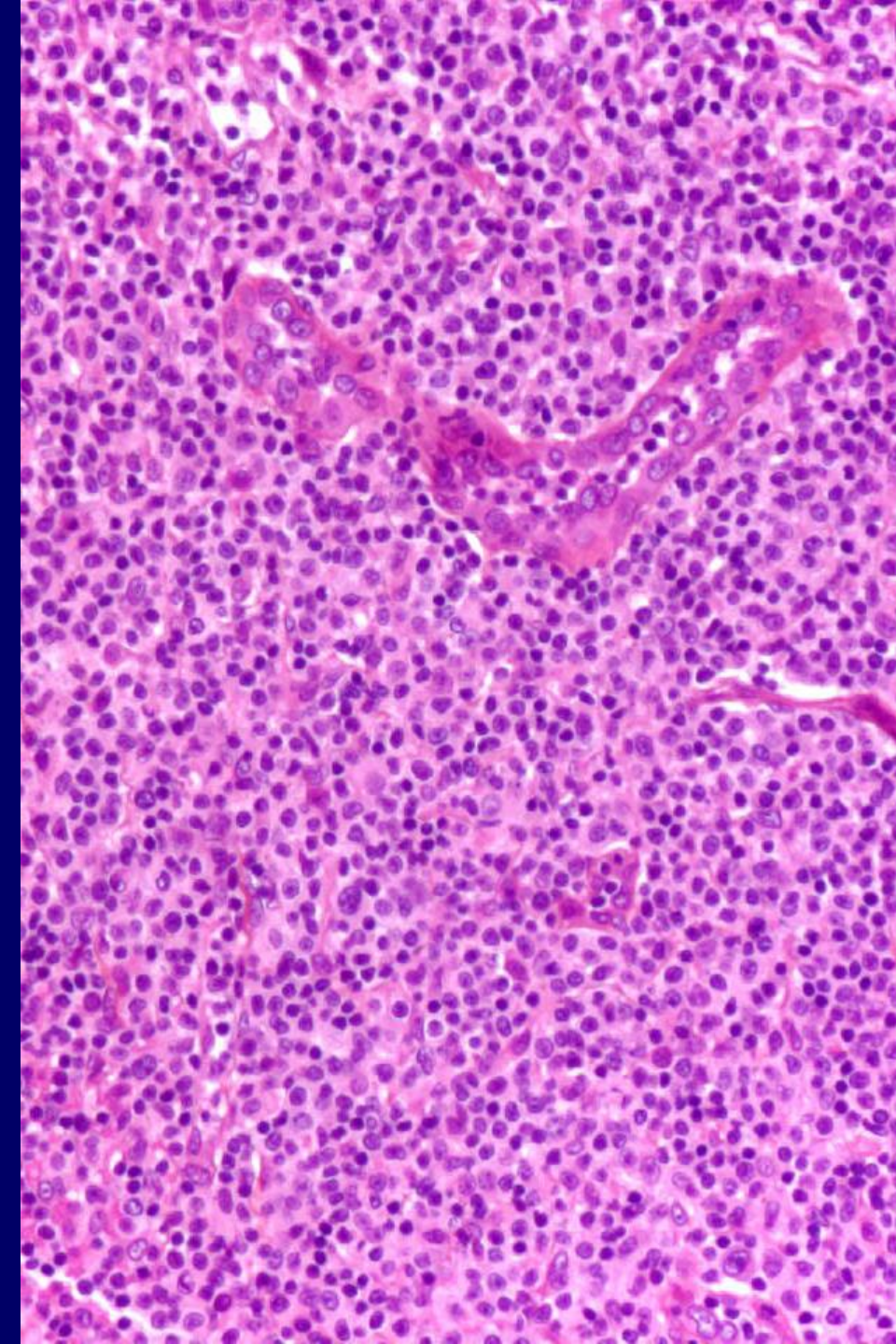
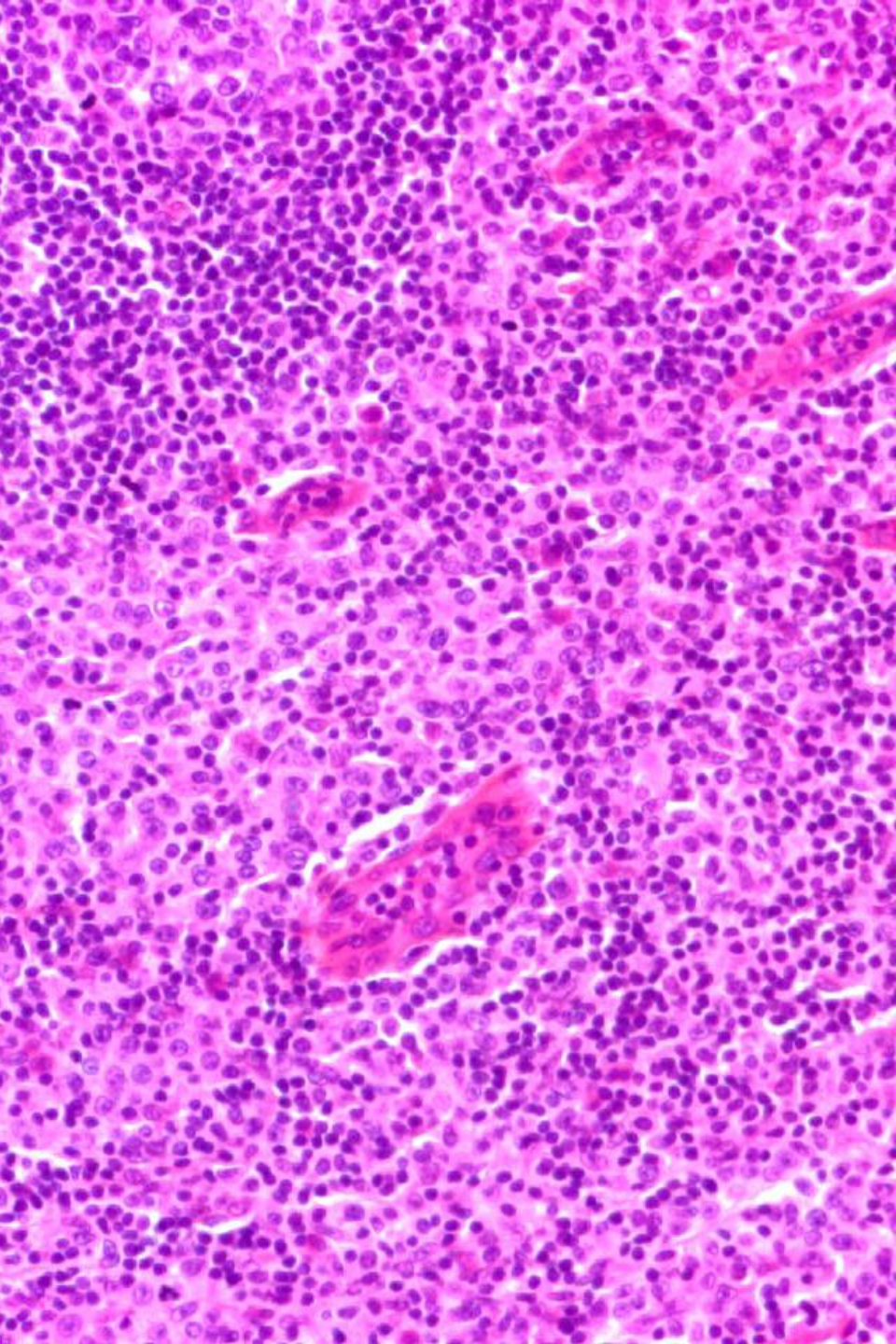
- Patiente traitée par chimiothérapie (2 cures CHOP) ,avec évolution favorable.

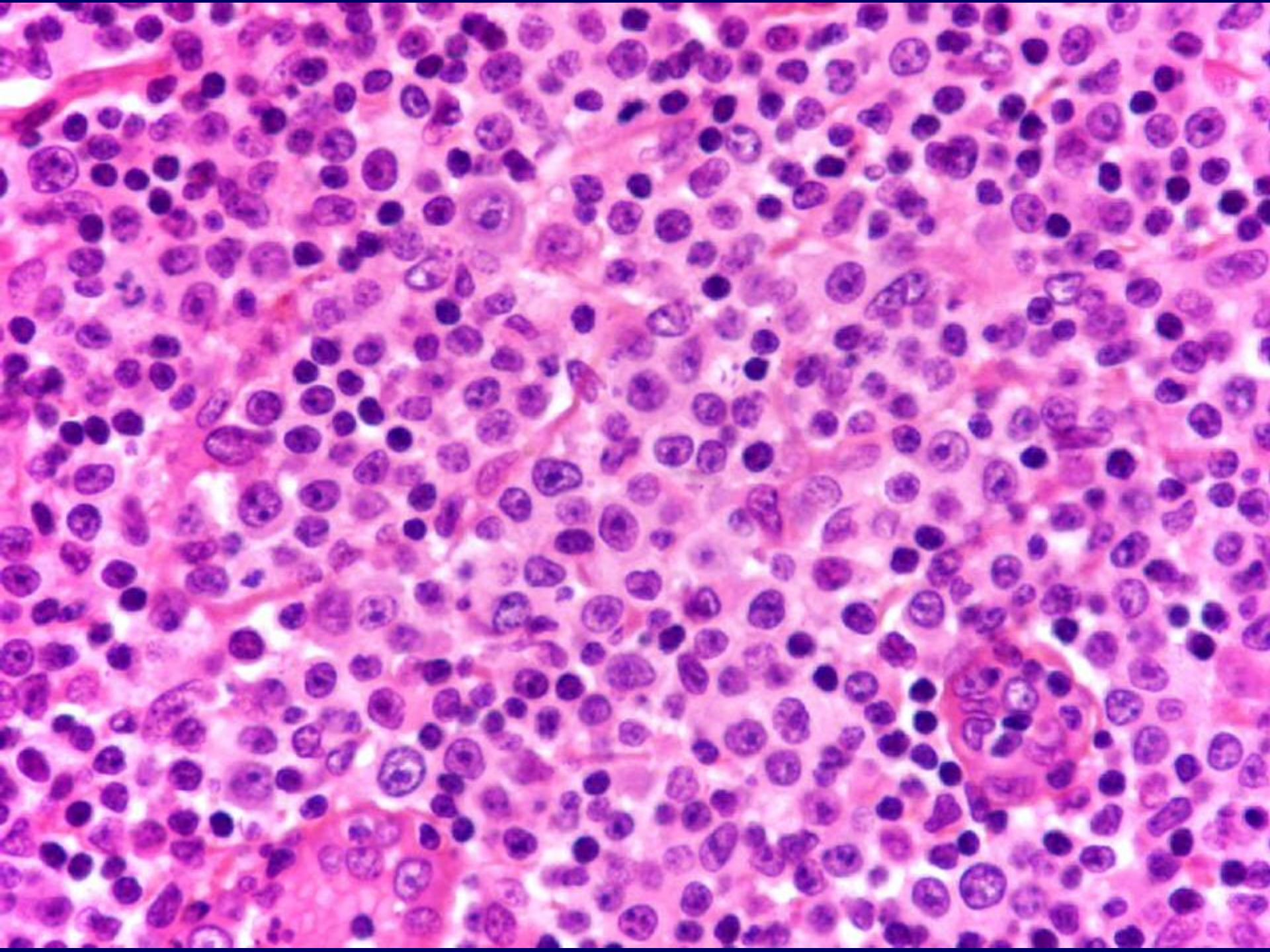
N° 12

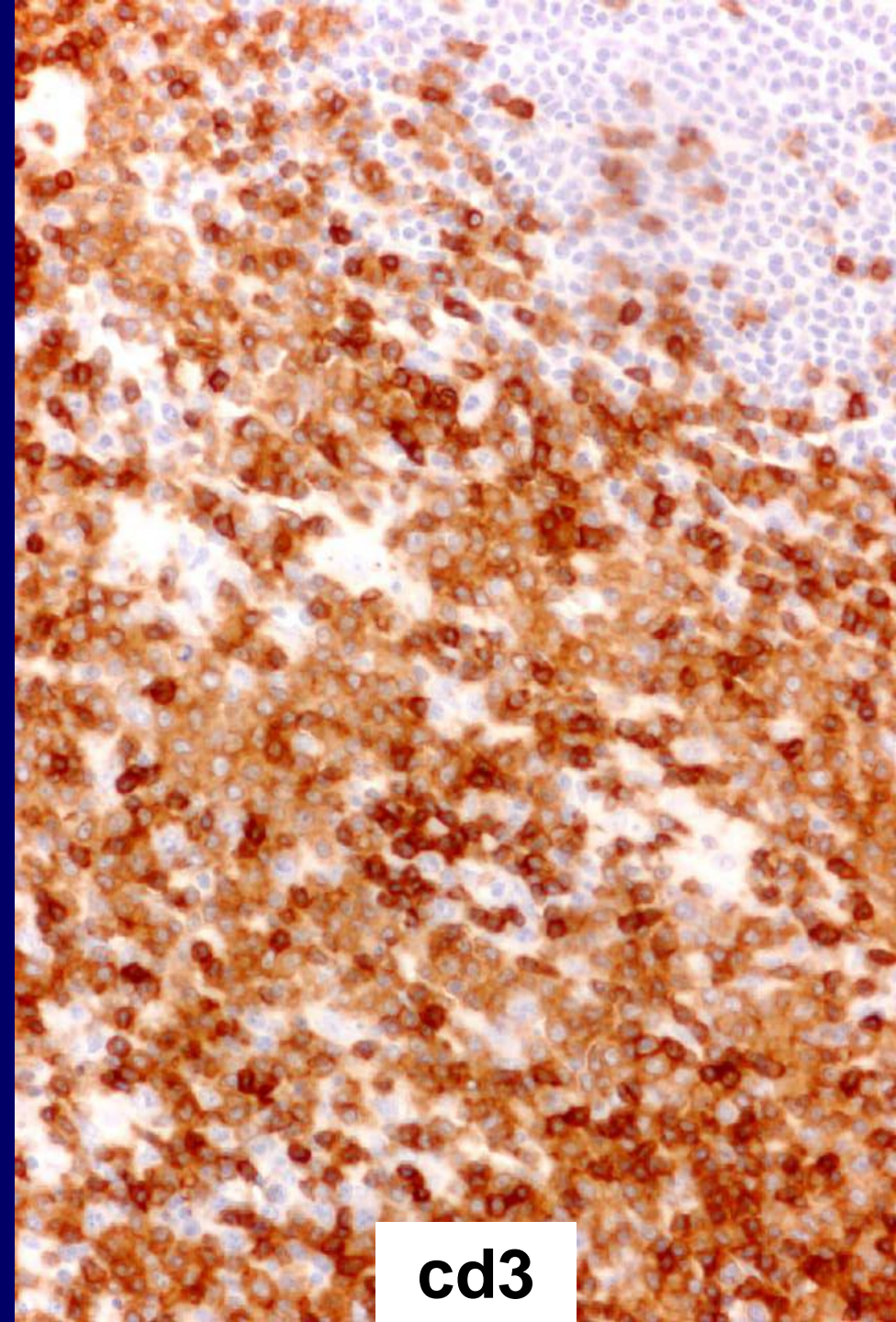
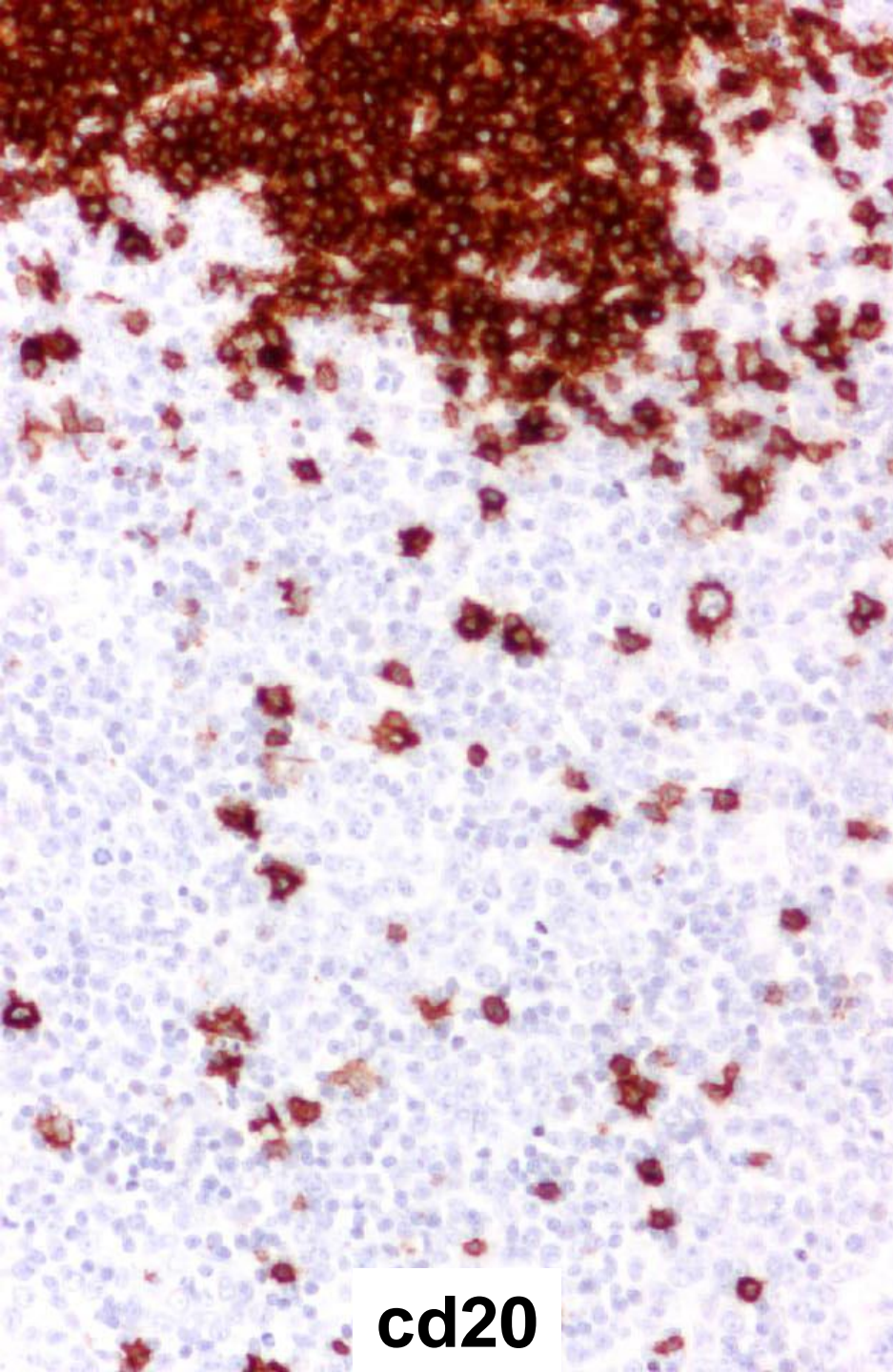
Sousse

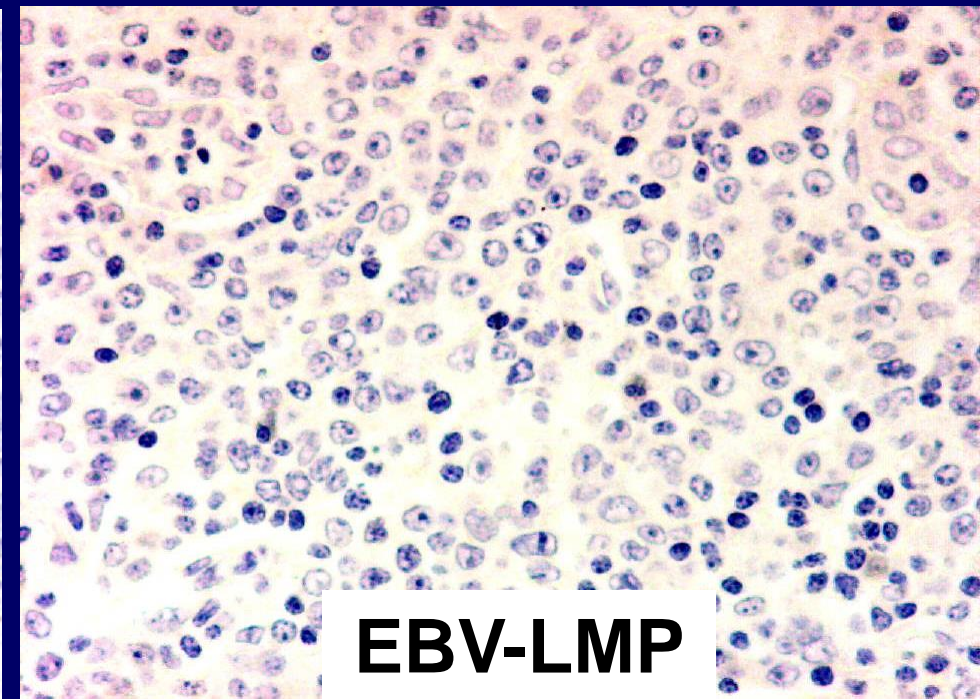
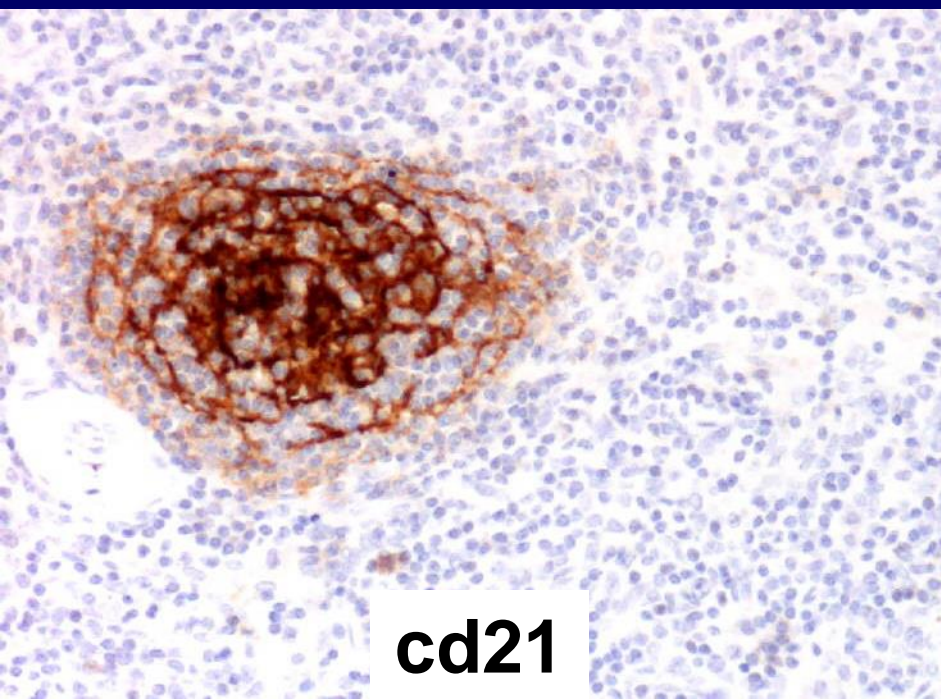
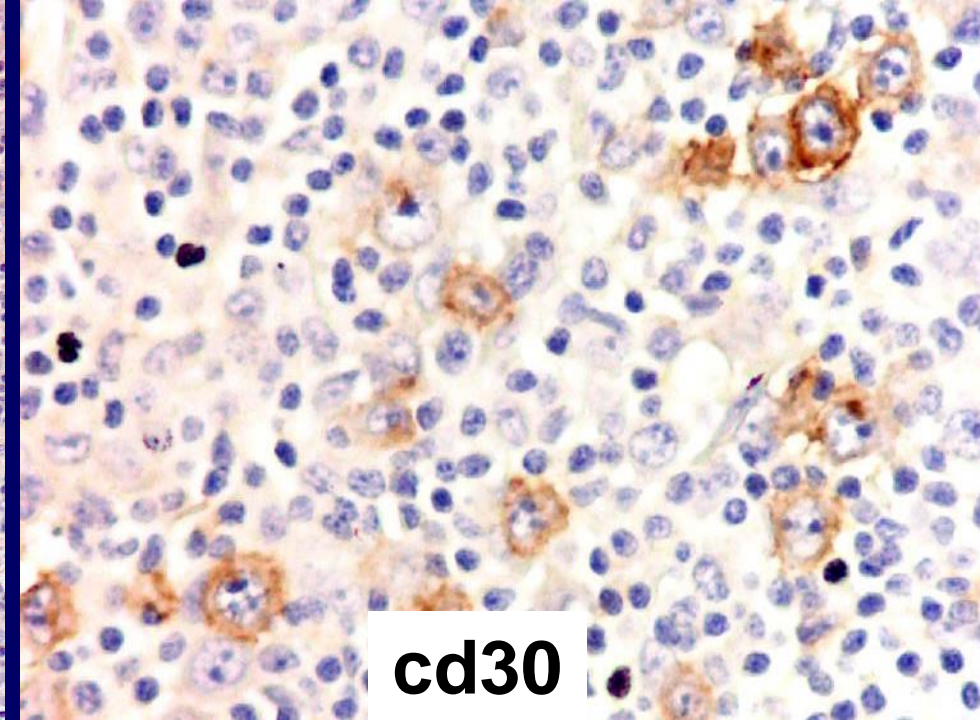
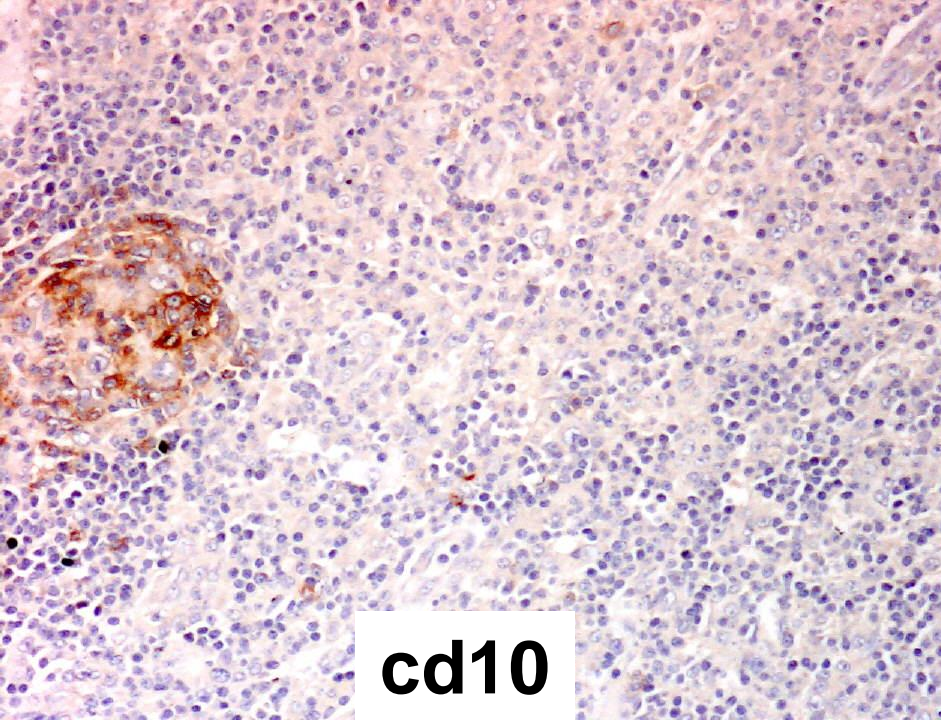
- Femme 39 ans.
- Mycosis fongoïde depuis 1992
- Atteinte ganglionnaire en 1997 (11759/97).
- Actuellement nouvelles lésions cutanées : placards érythémateux squameux et masse tumorale sus-jacente (10728/07)

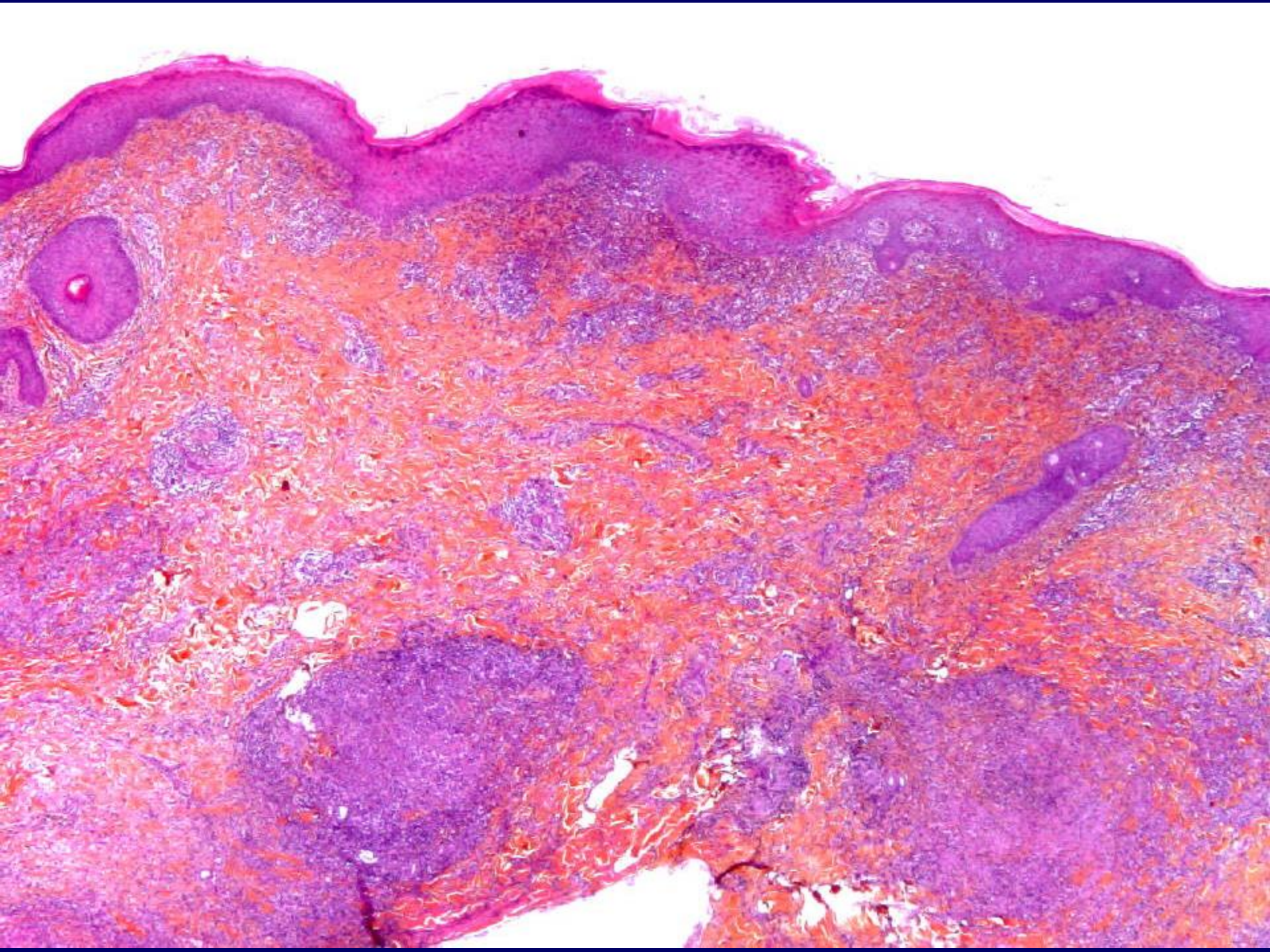


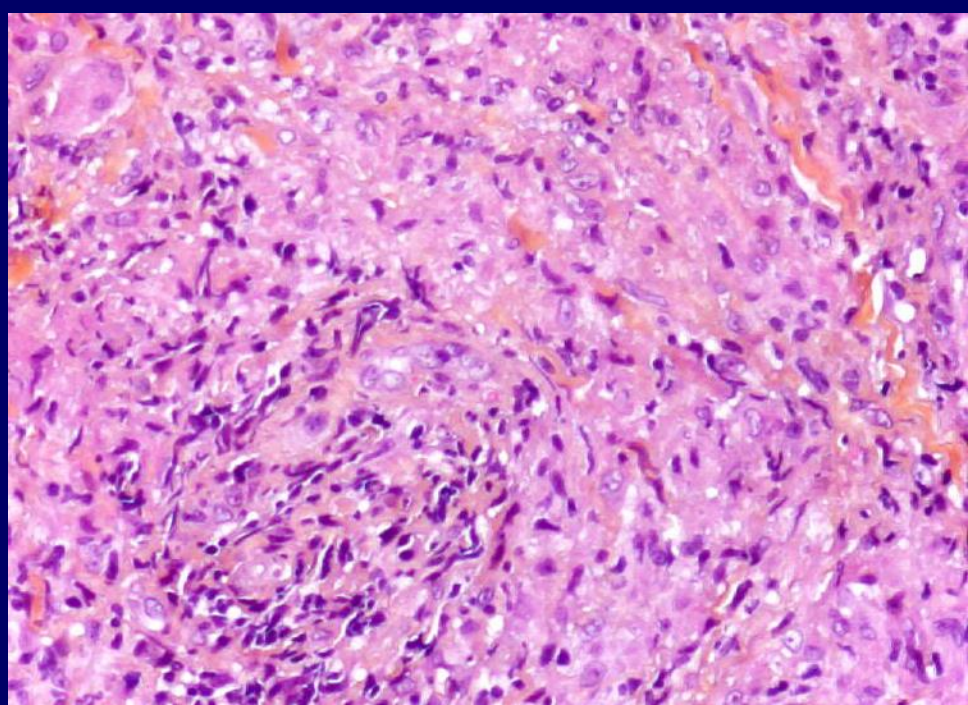
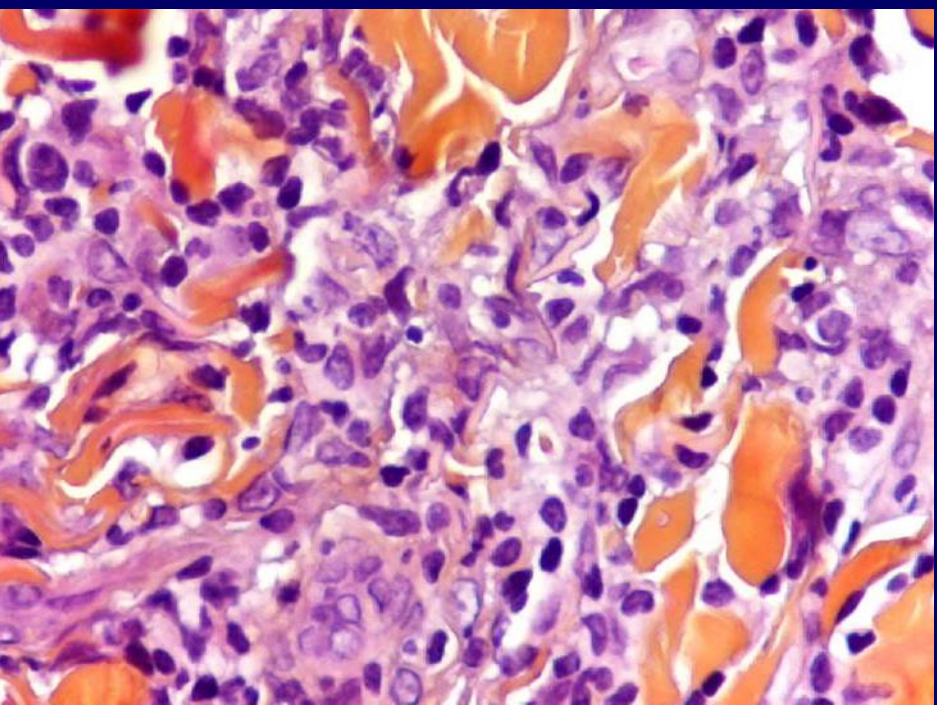
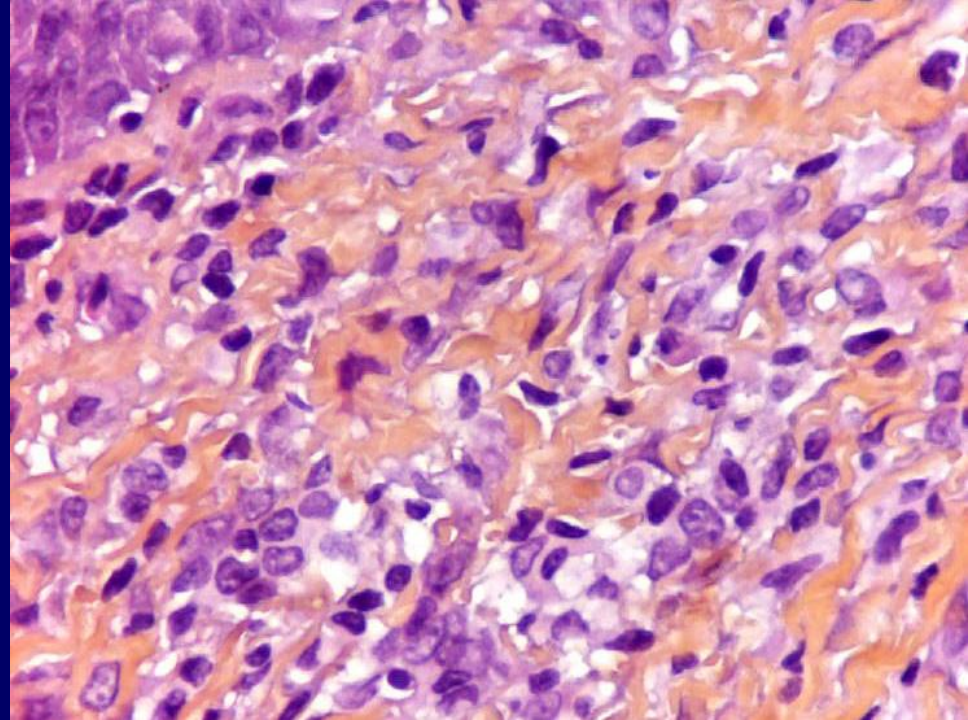
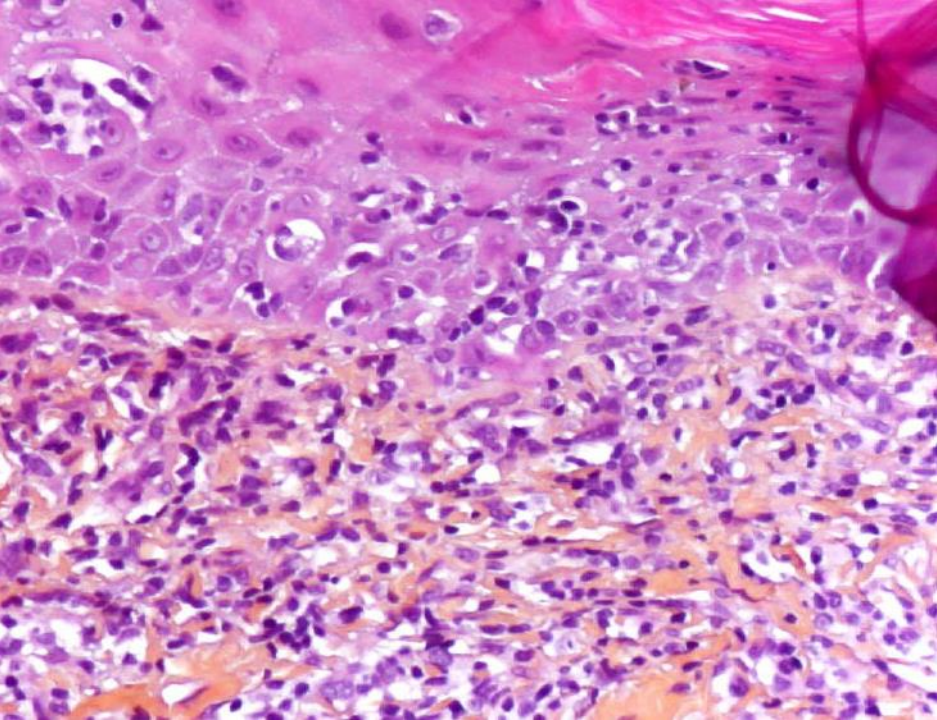


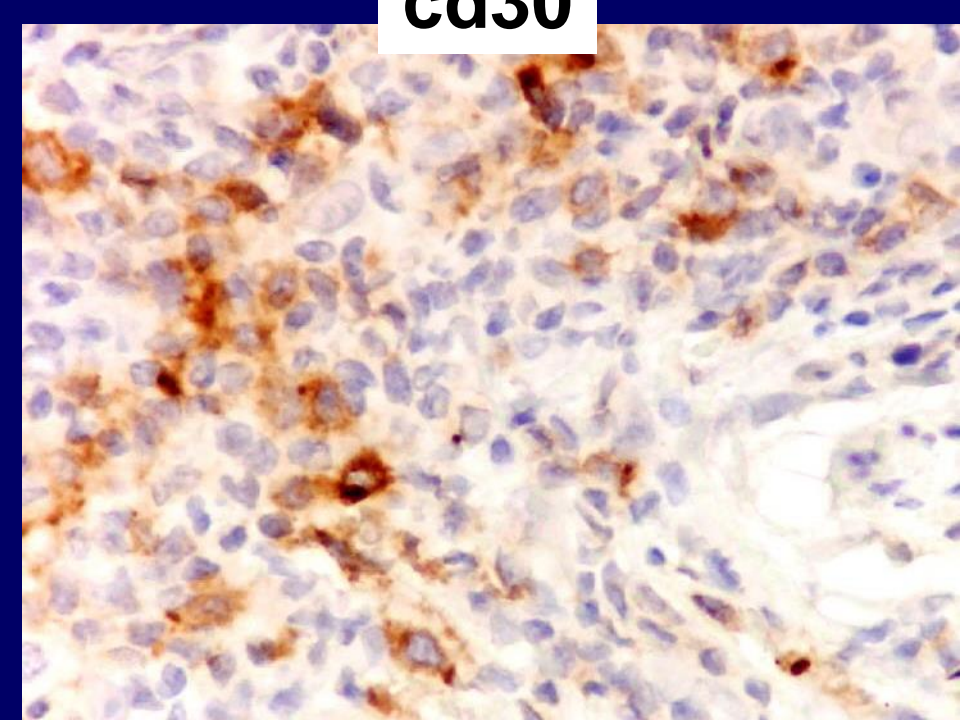
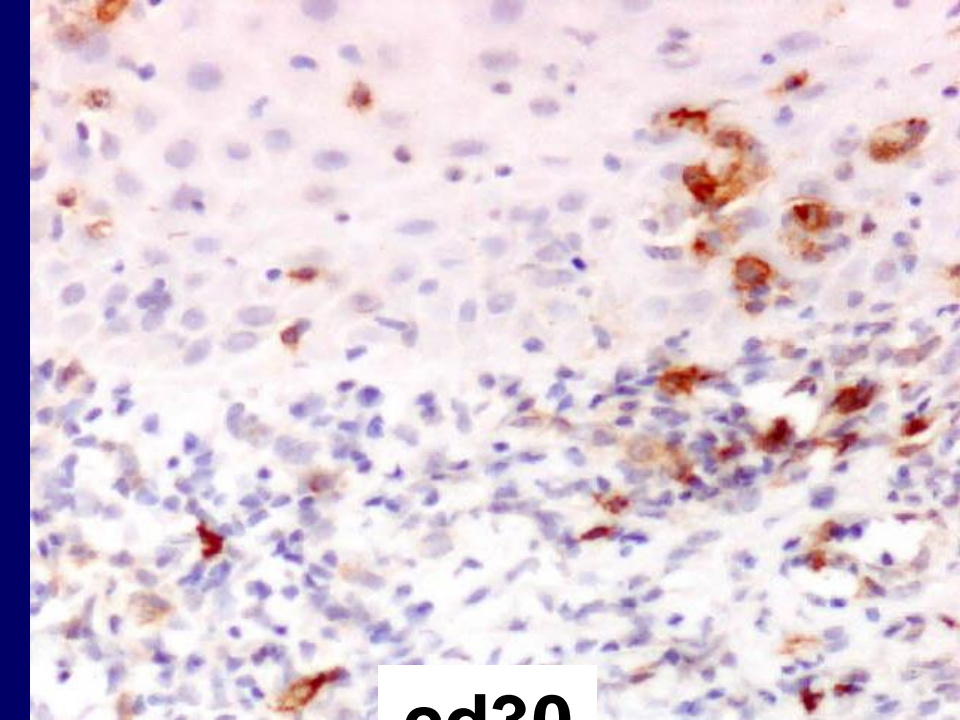
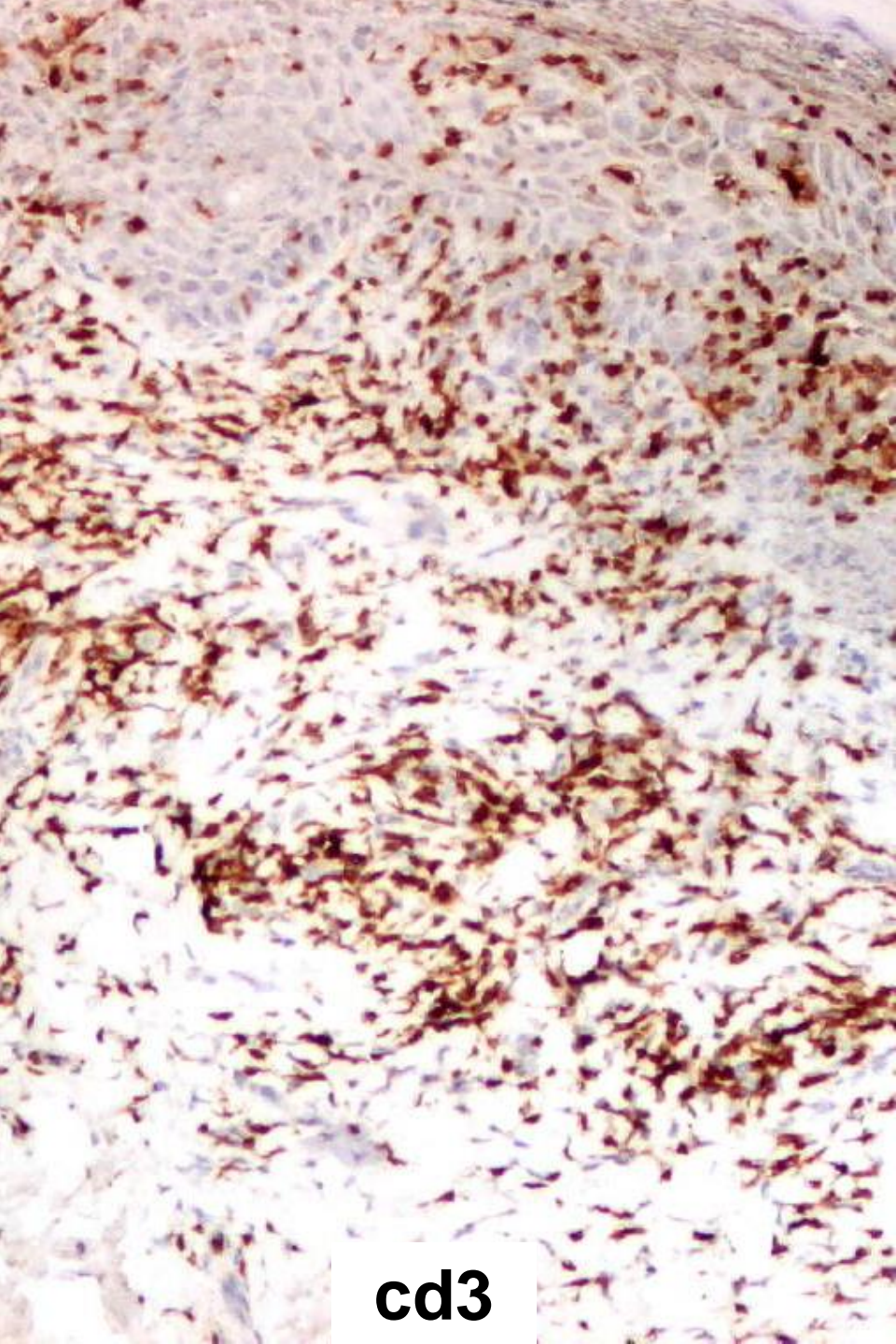












N° 12

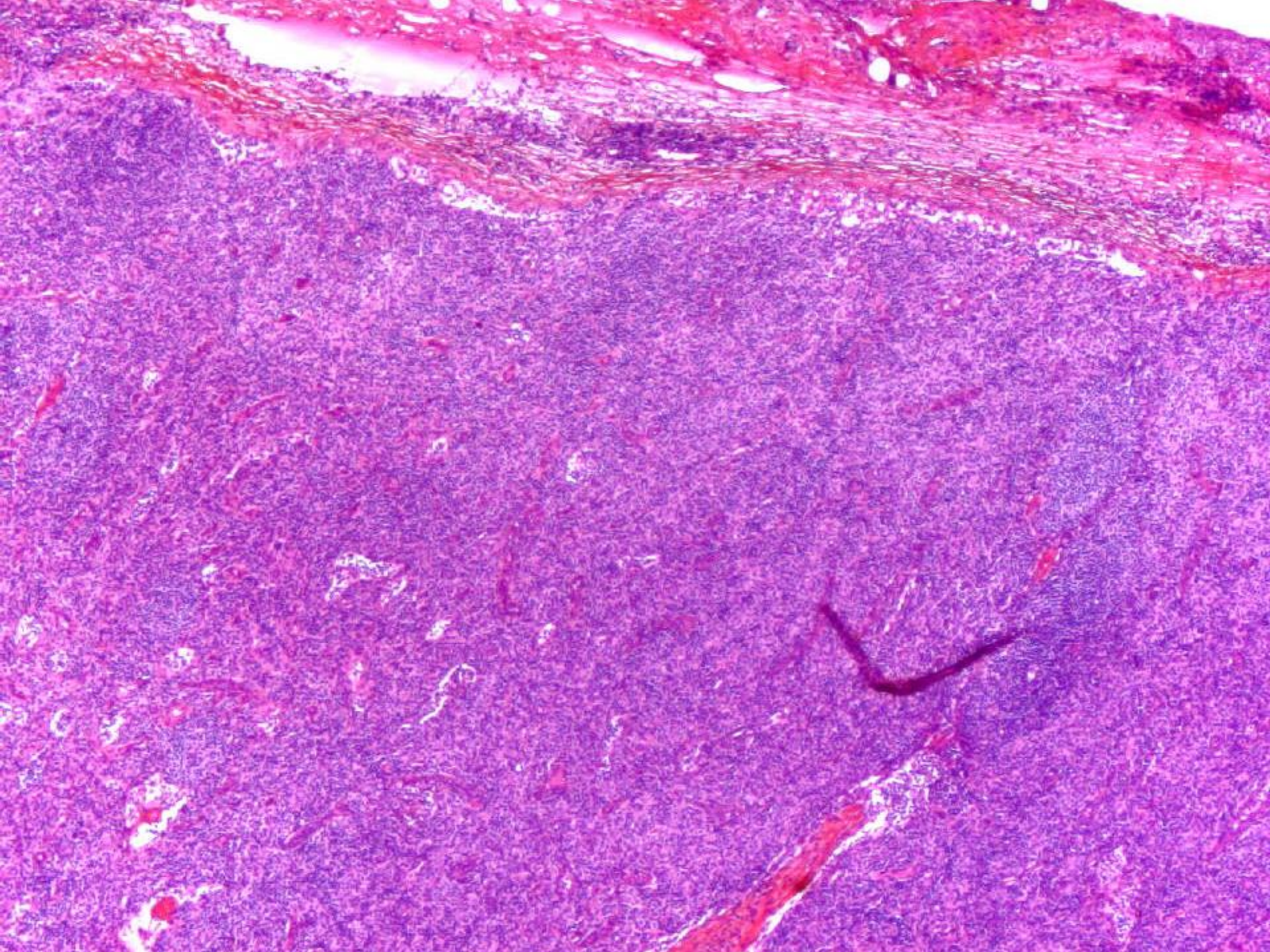
1997 : localisation ganglionnaire du MF transformé

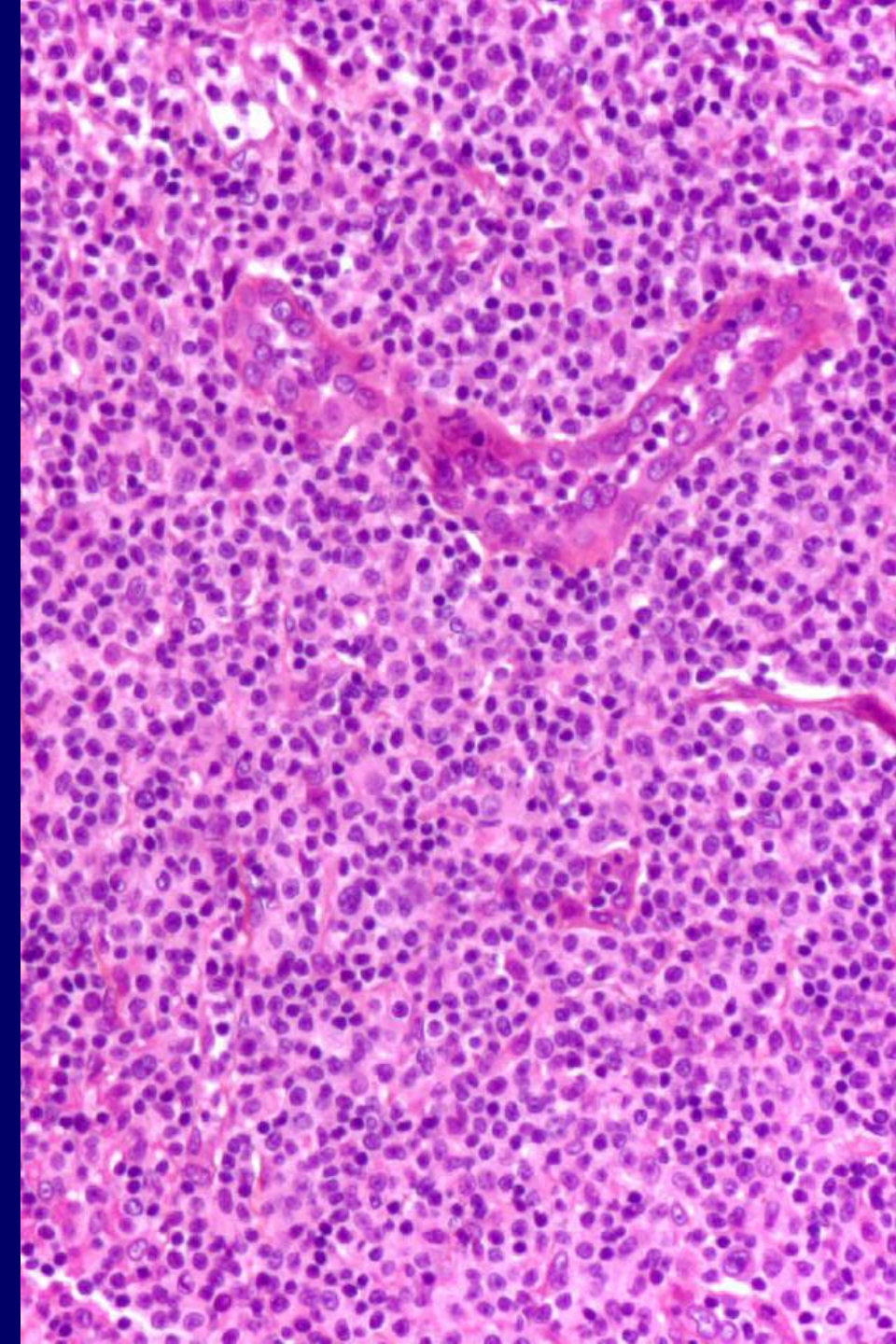
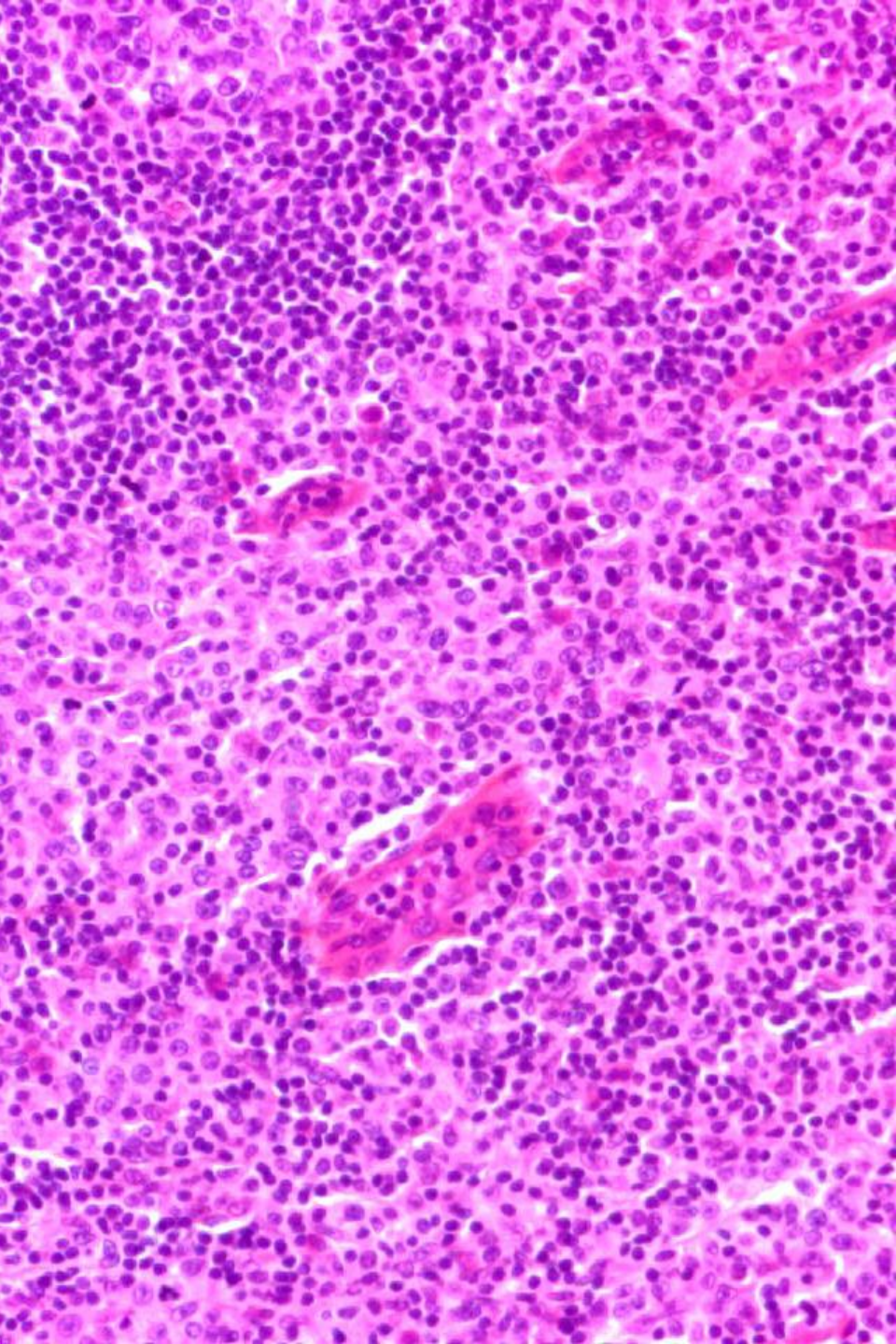
2007 peau : MF transformé avec grandes c/ T cd30 + , intra-épidermiques et dermiques, granulome épithélioïde à rattacher au MF (Zielh -)

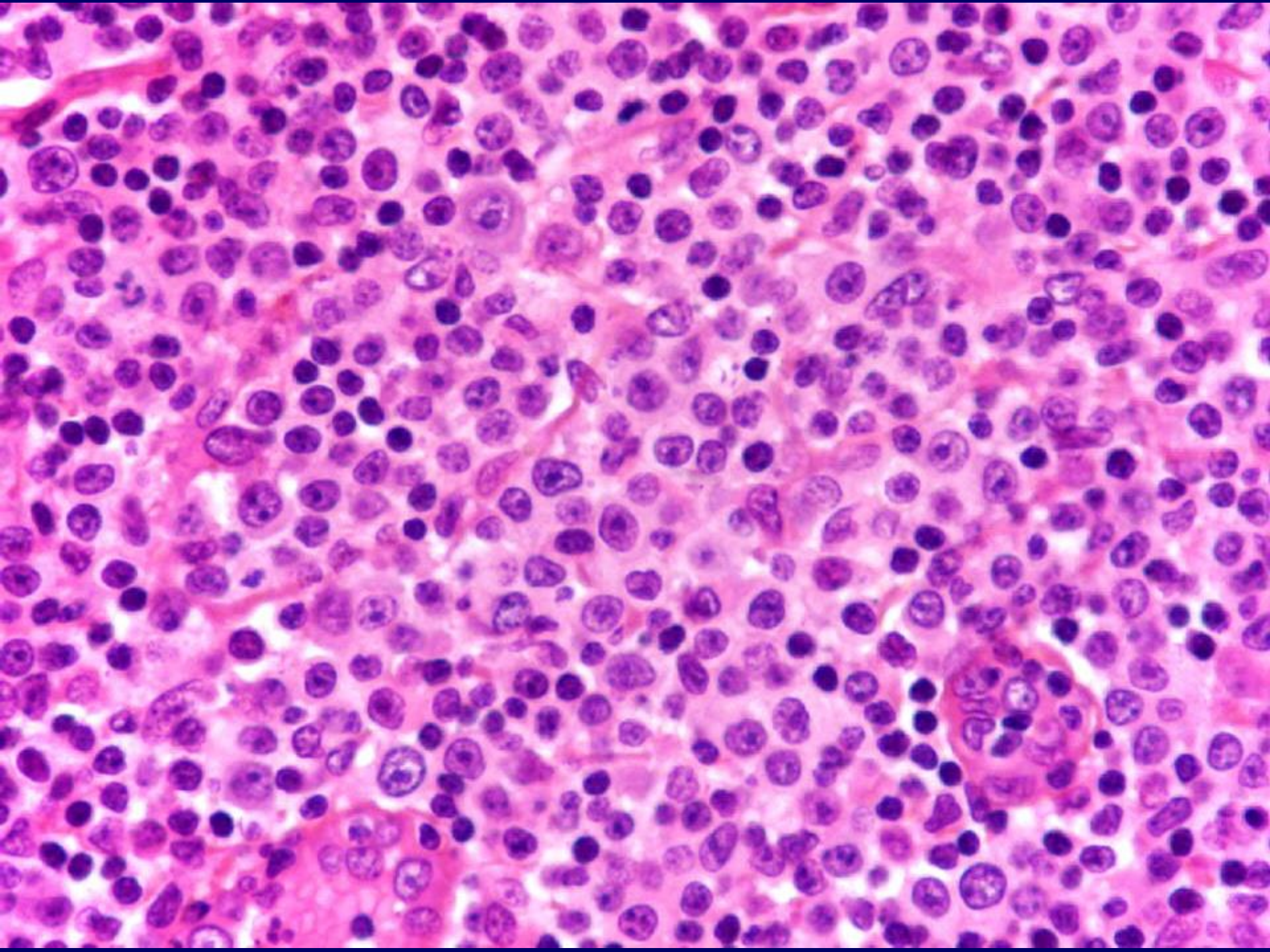
N° 12

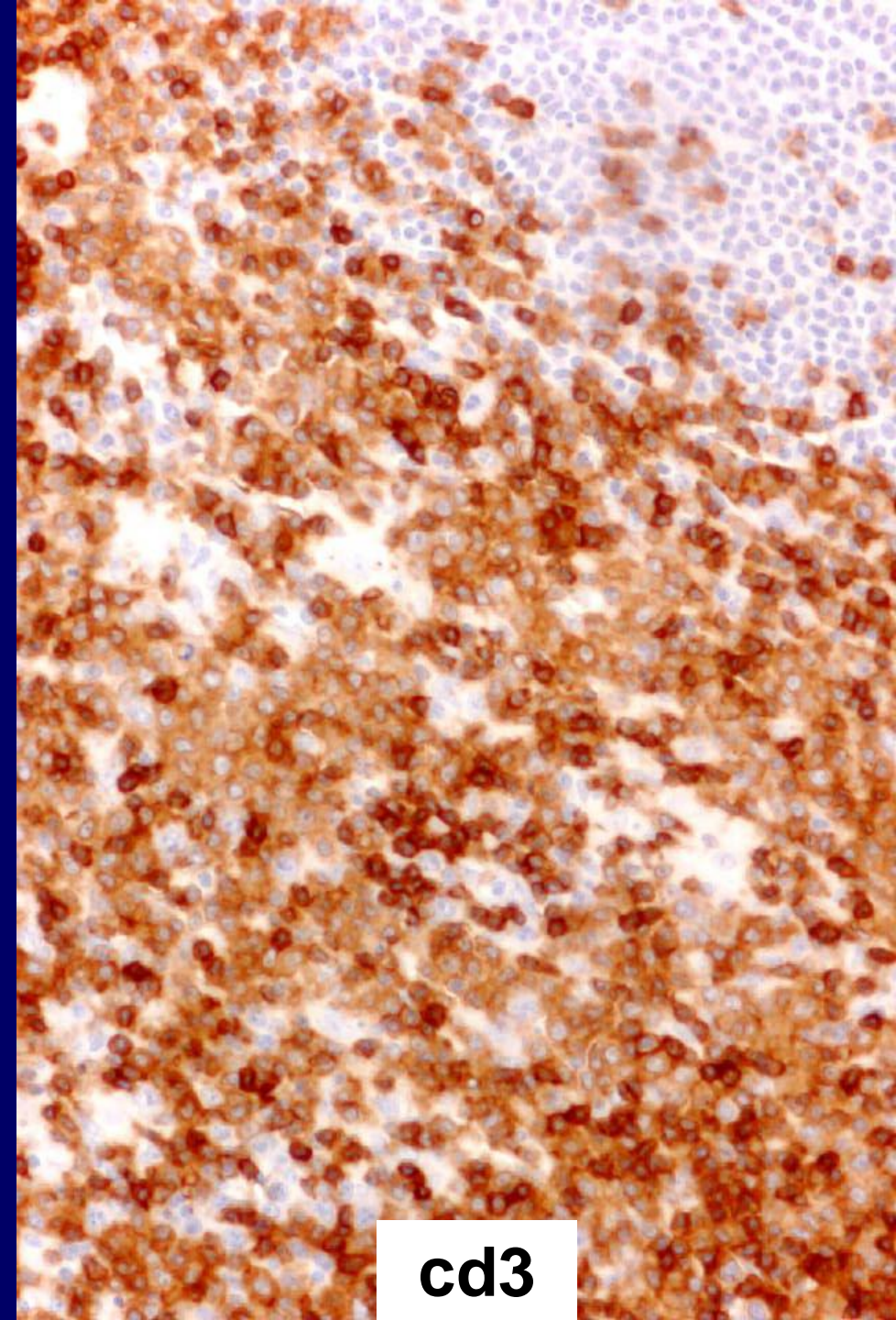
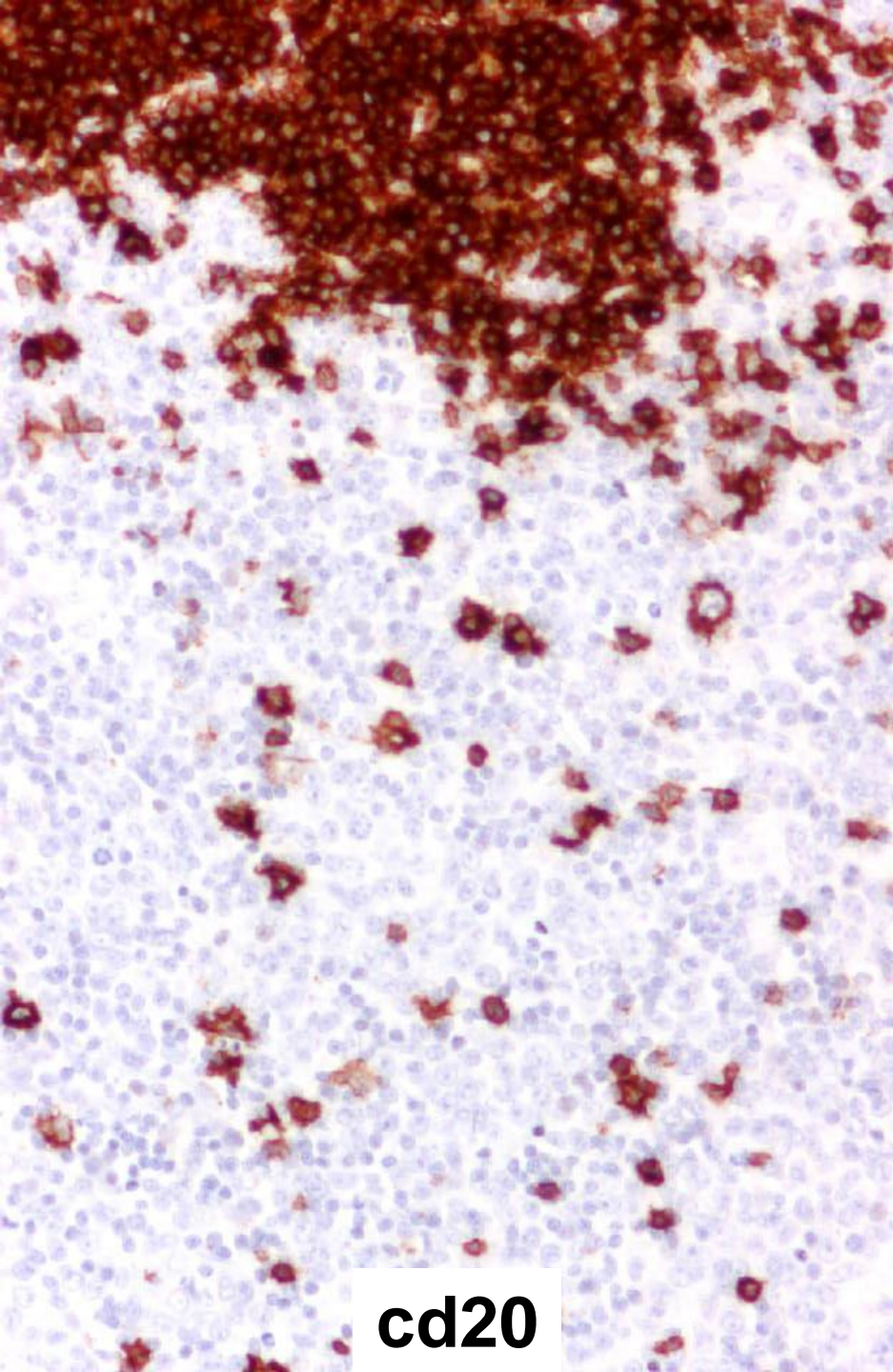
Sousse

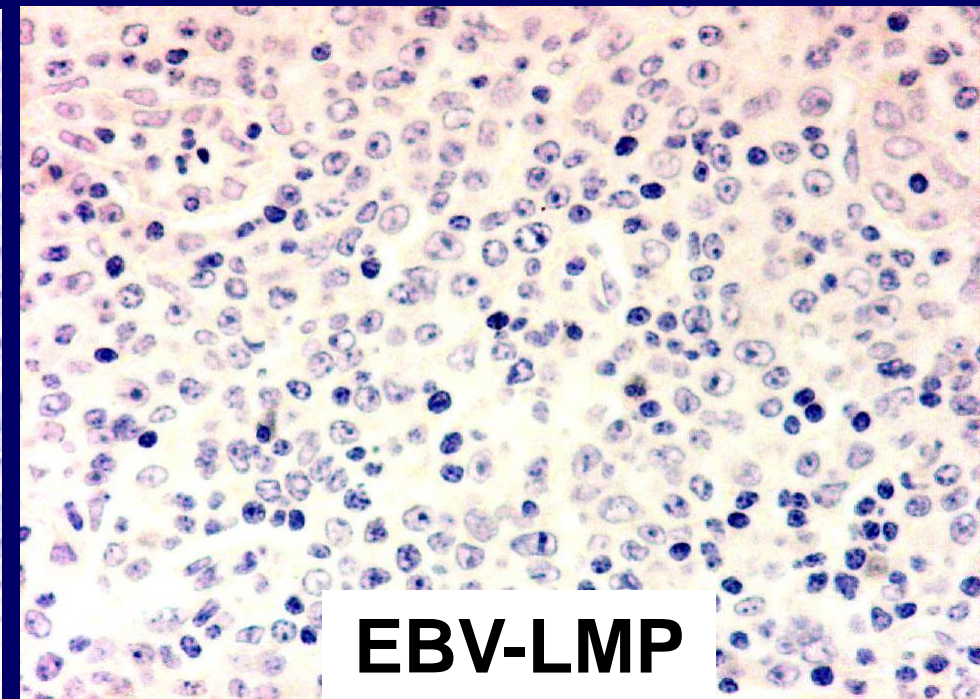
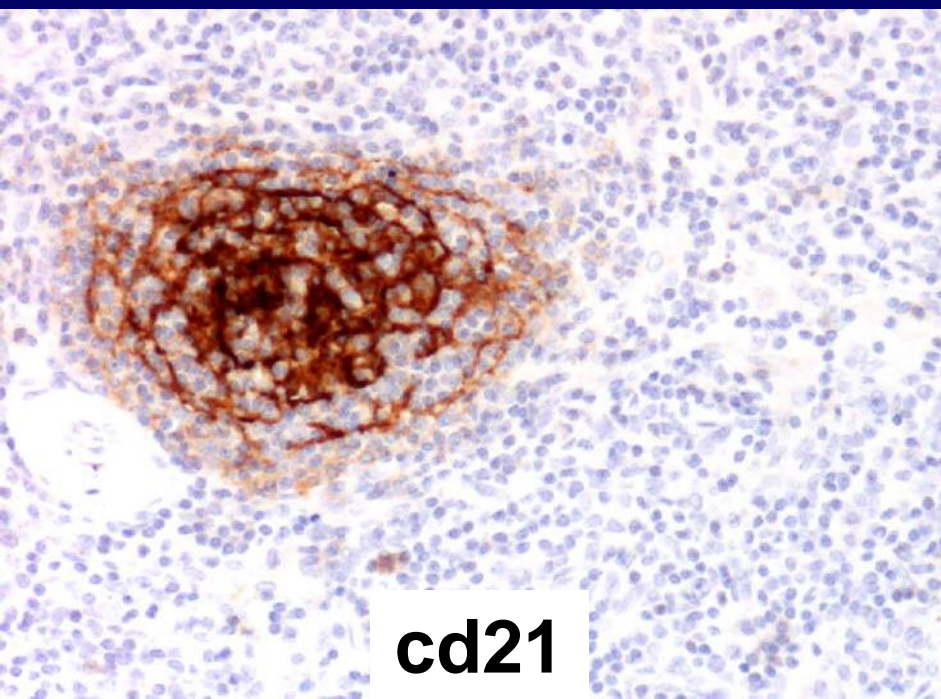
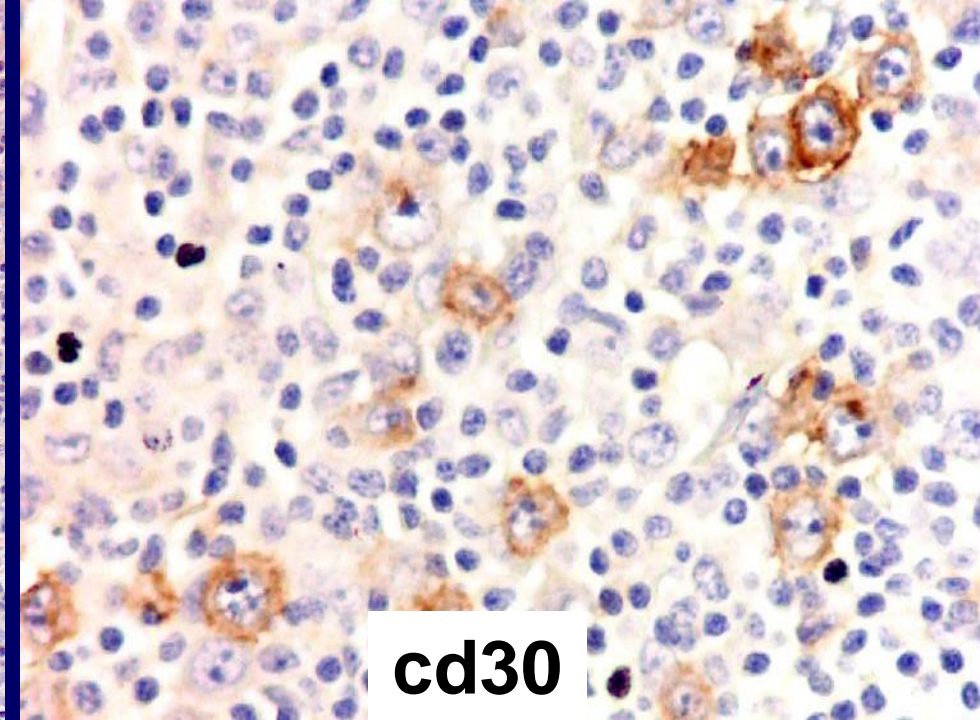
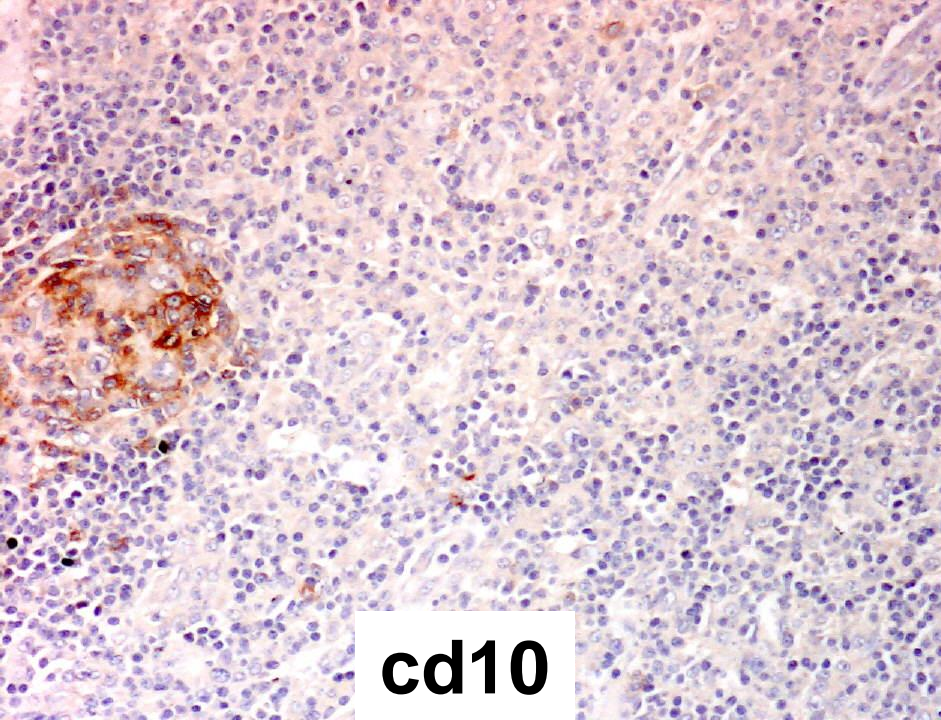
- Femme 39 ans.
- Mycosis fongoïde depuis 1992
- Atteinte ganglionnaire en 1997 (11759/97).
- Actuellement nouvelles lésions cutanées : placards érythémateux squameux et masse tumorale sus-jacente (10728/07)

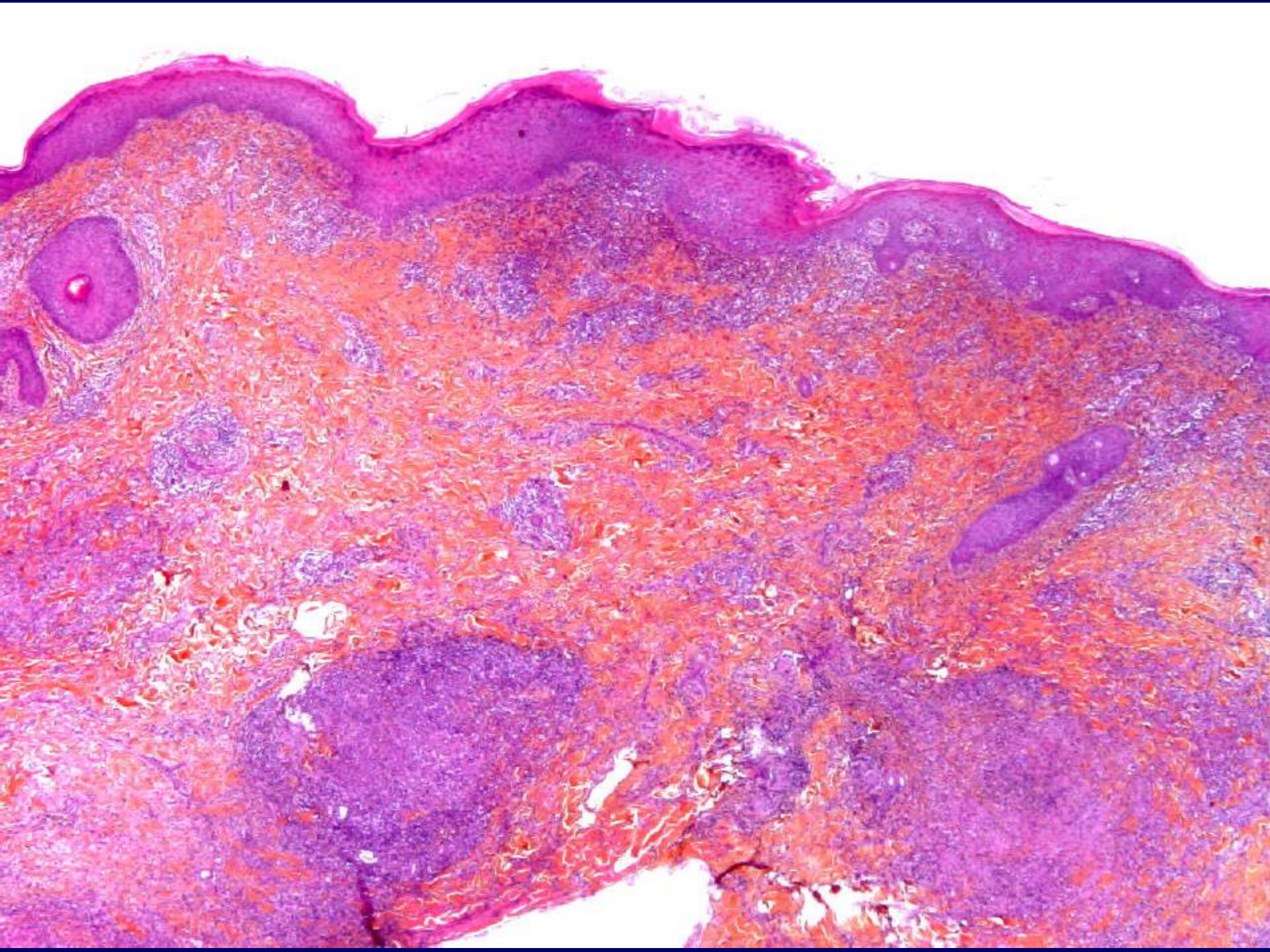


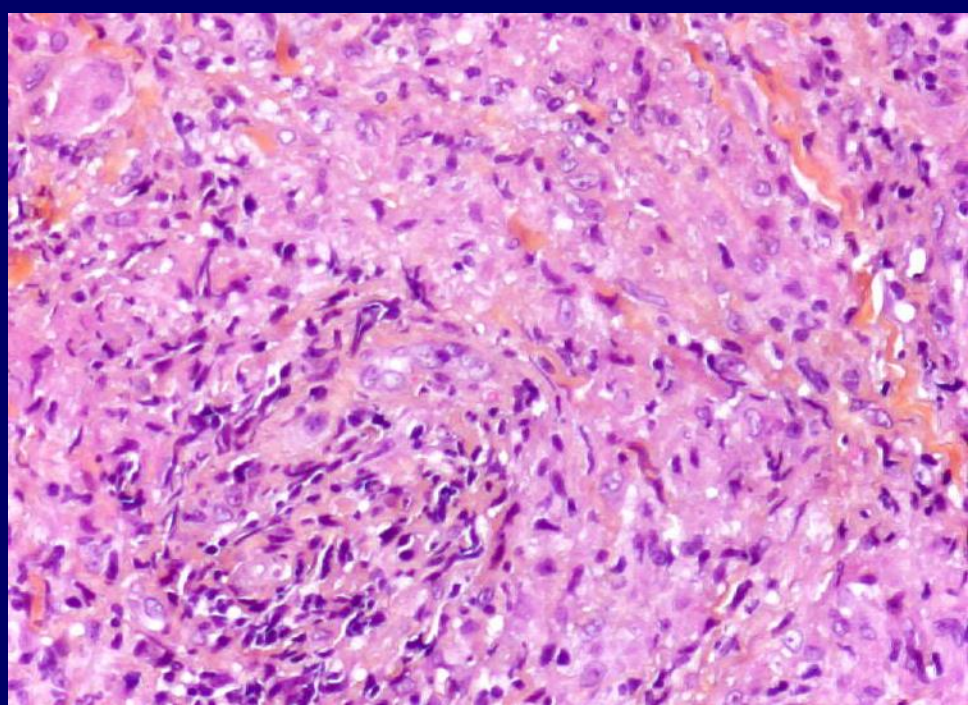
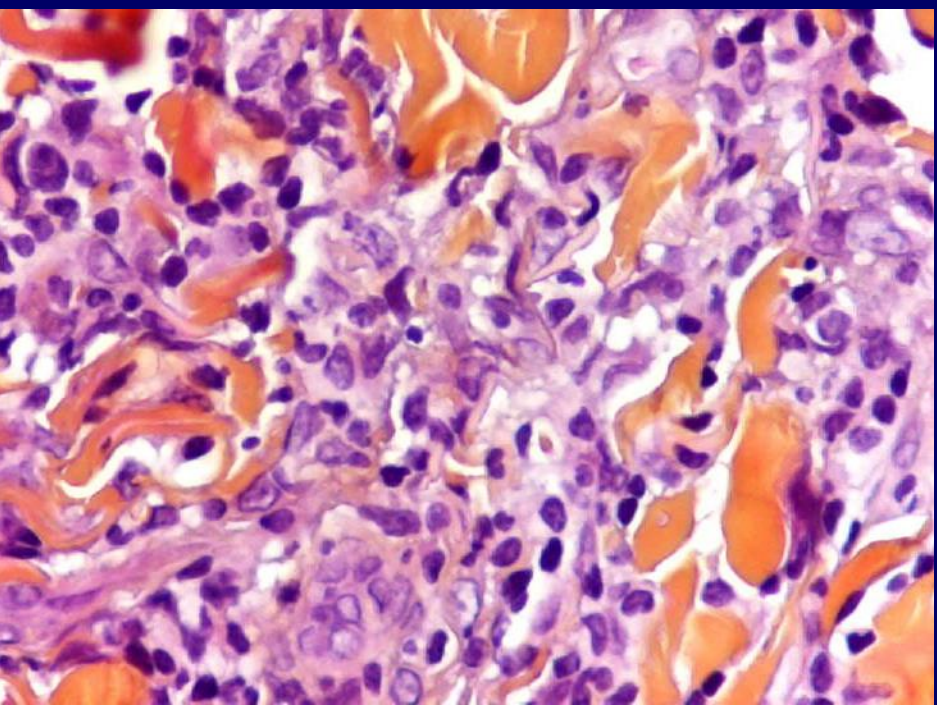
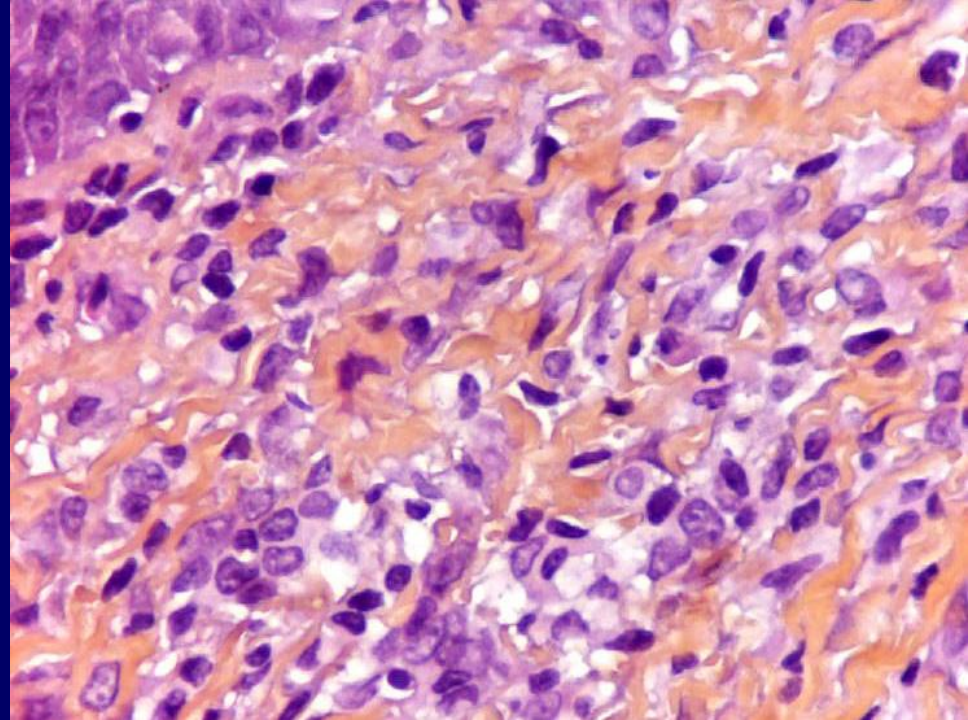
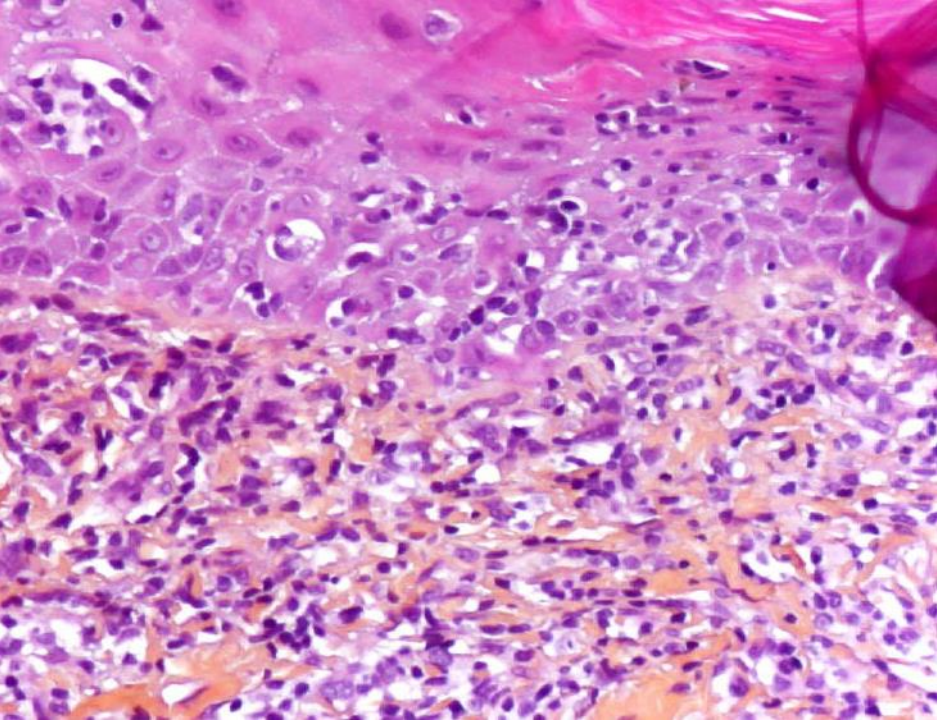


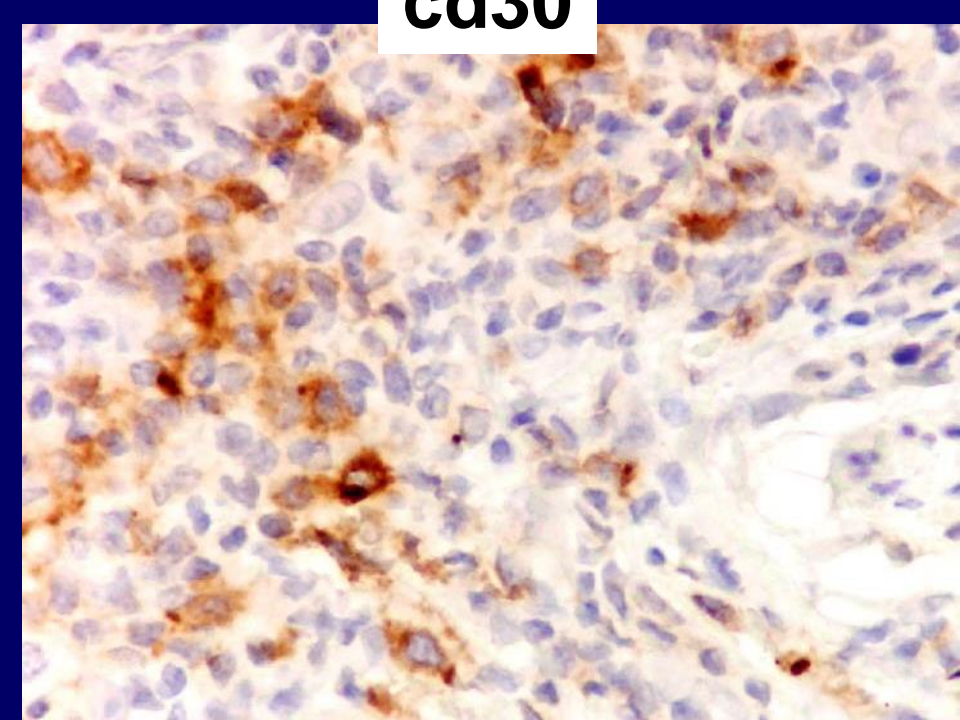
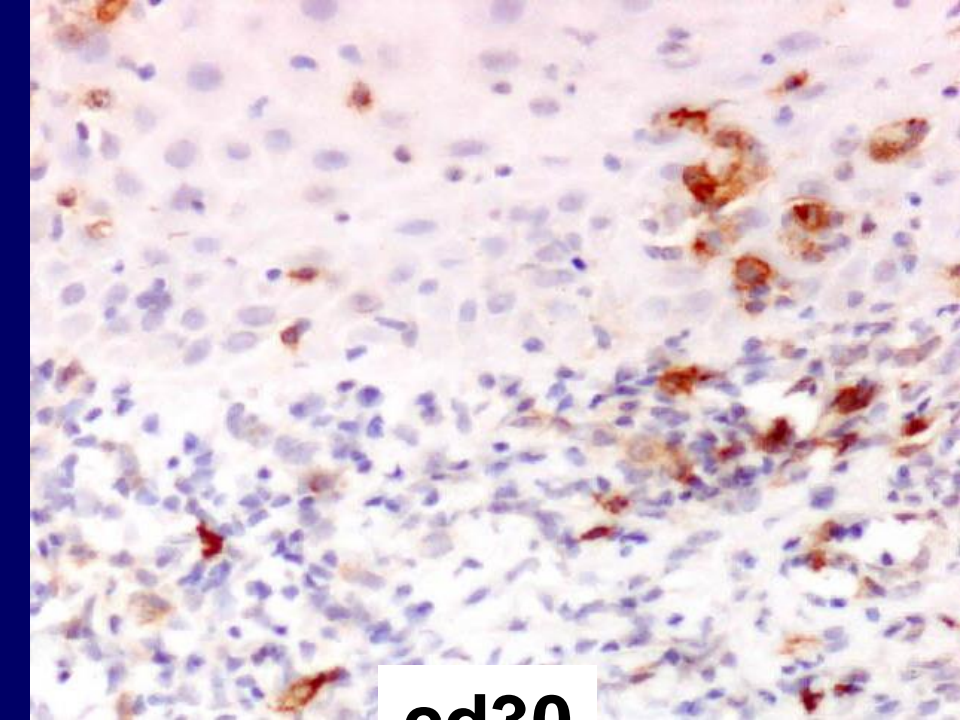
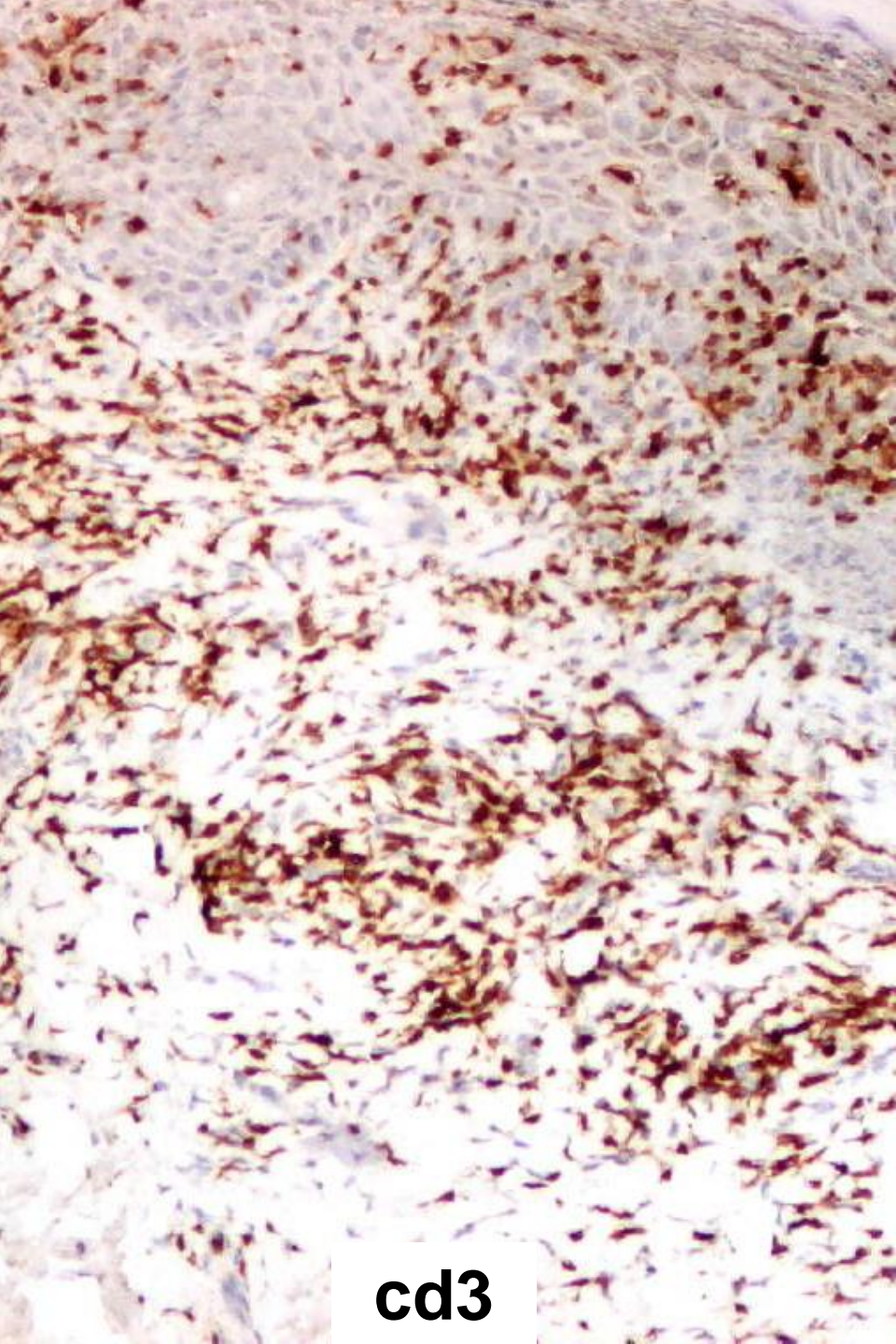










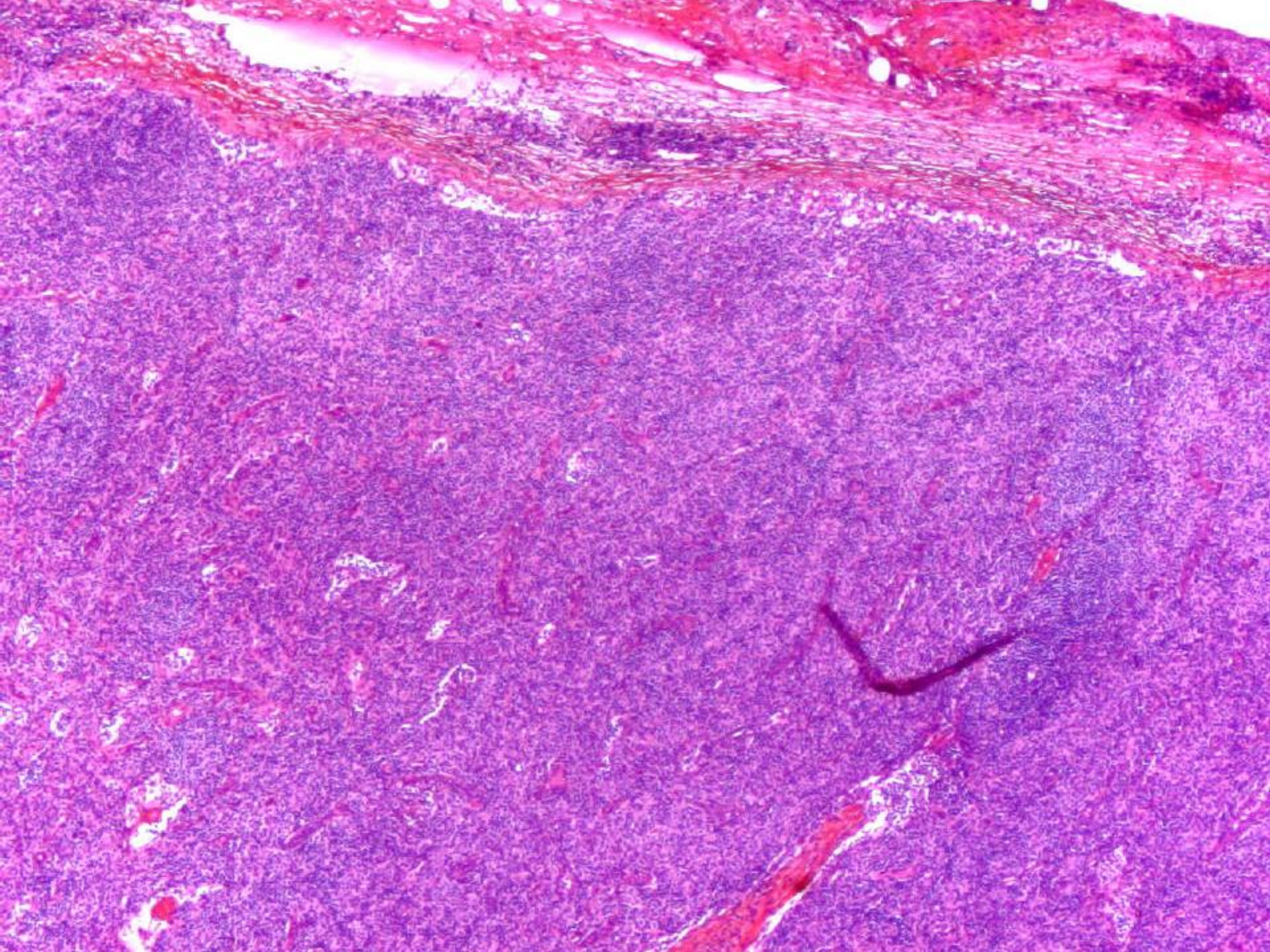


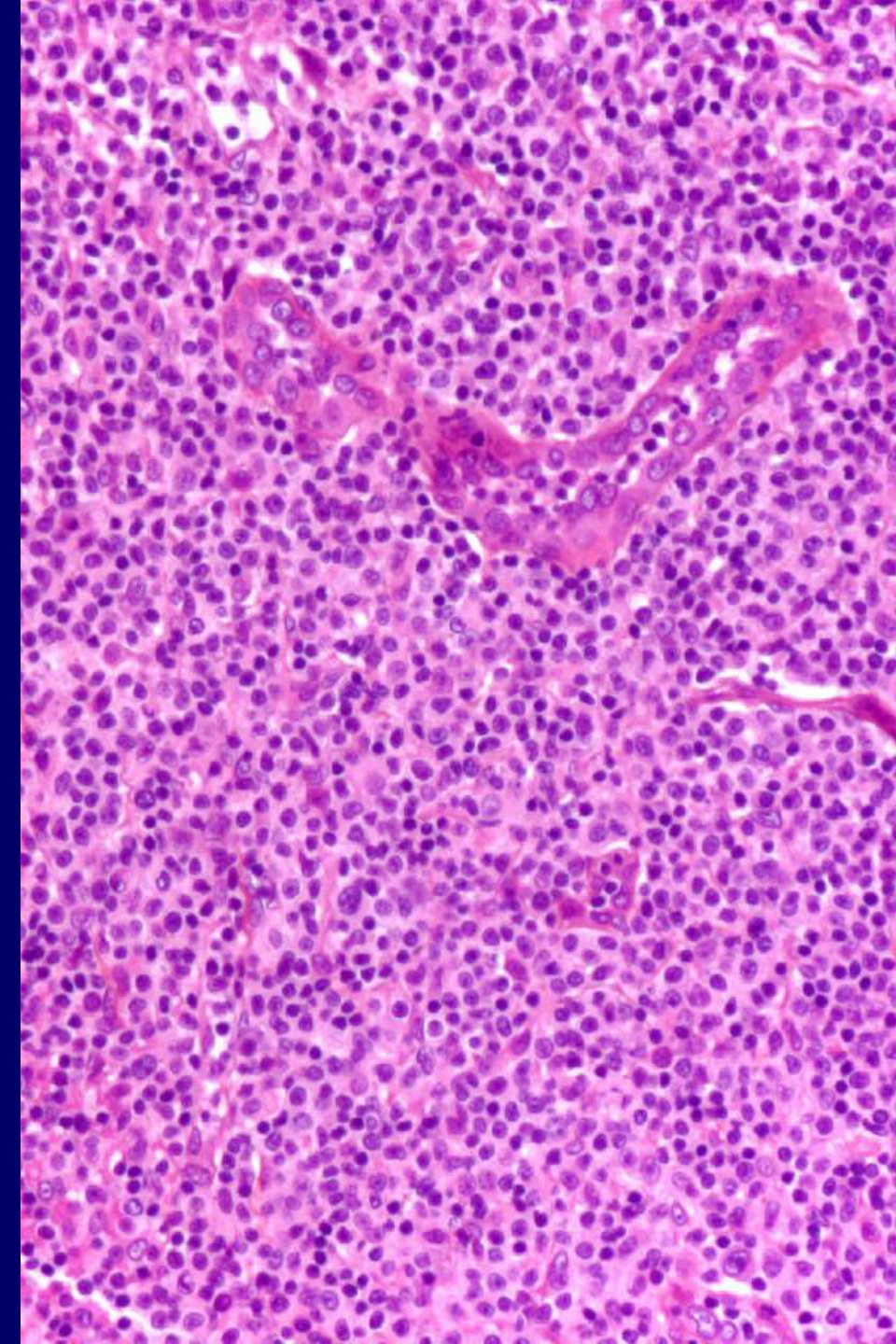
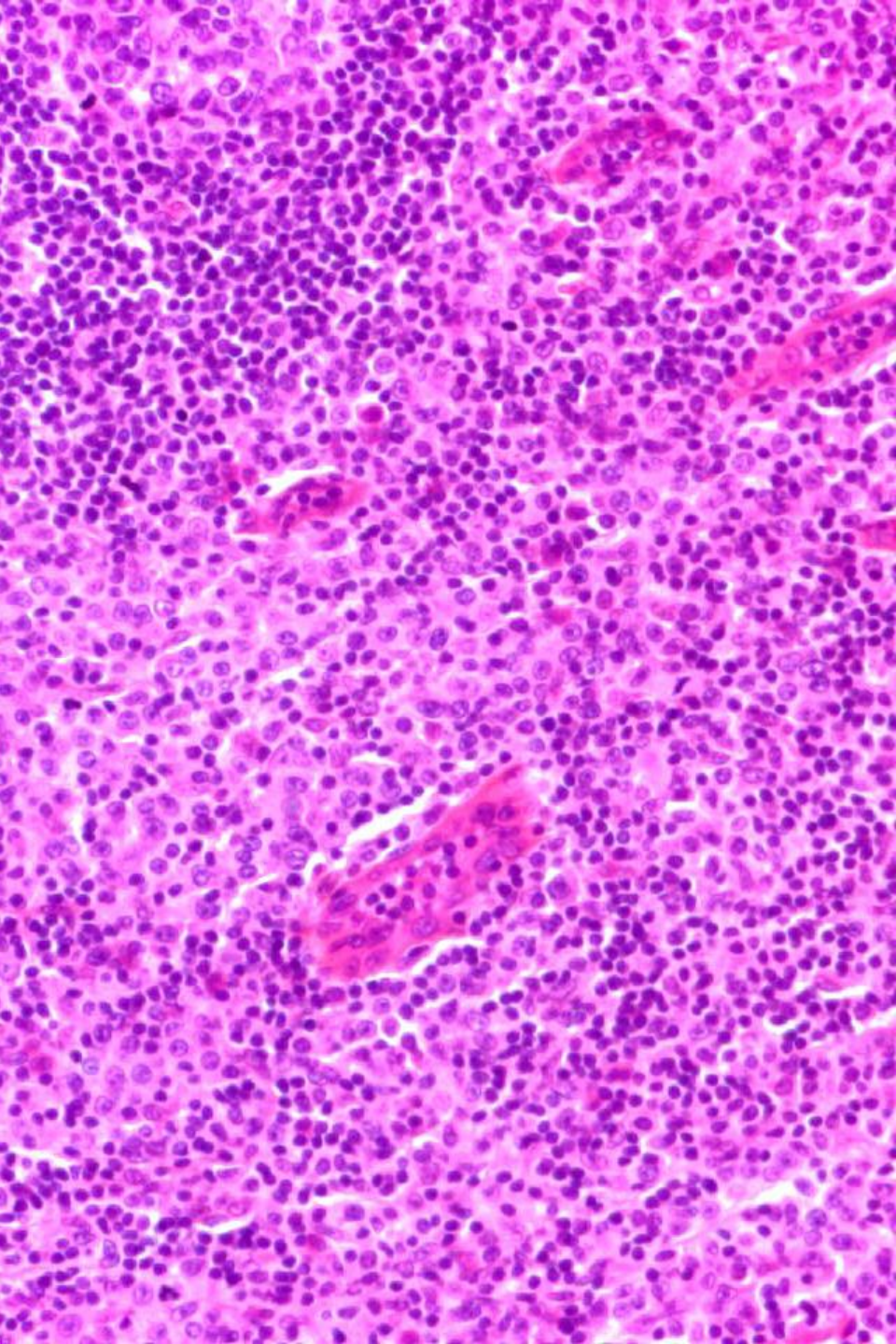
N° 12

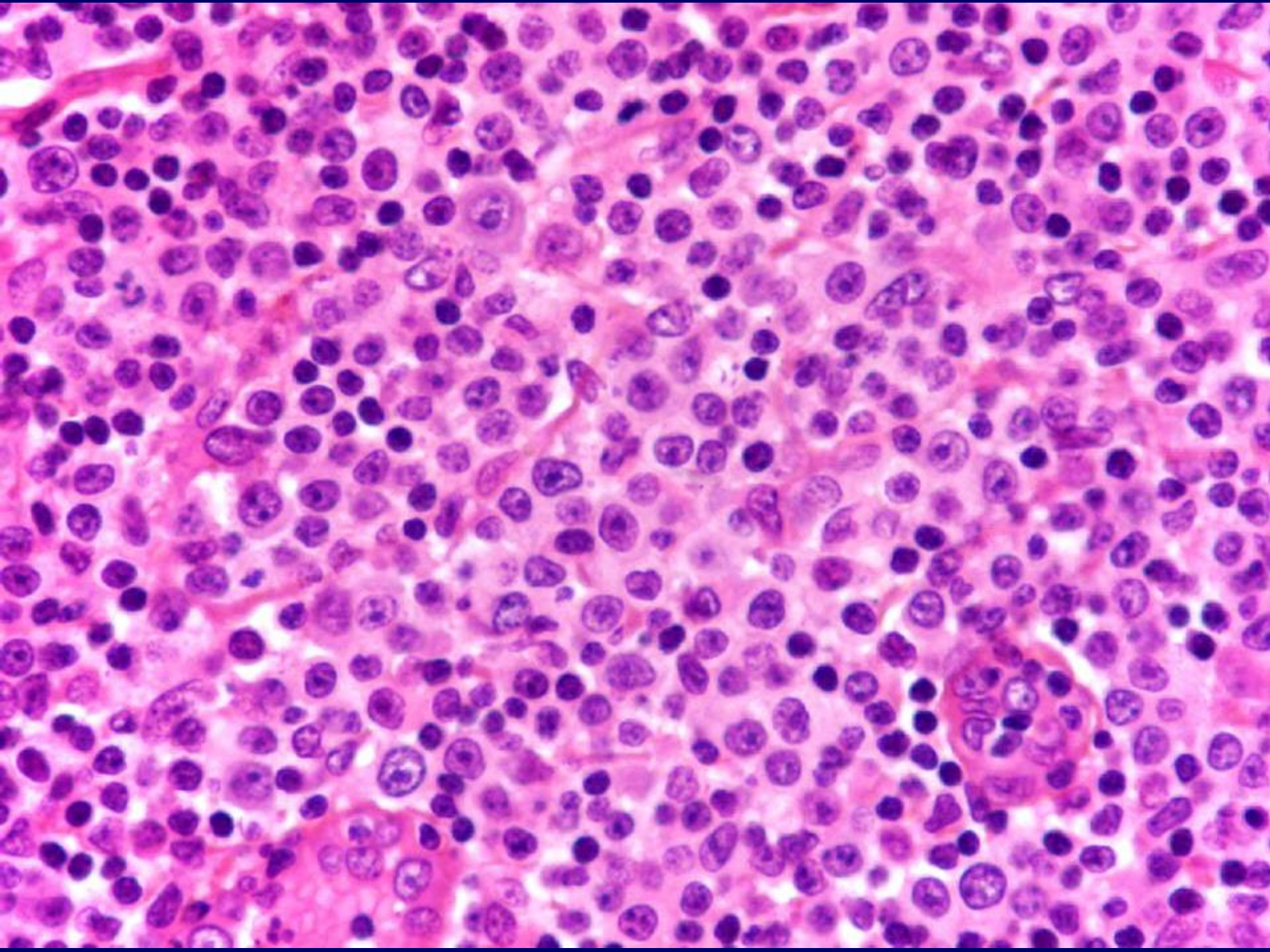
1997 : localisation ganglionnaire du MF transformé

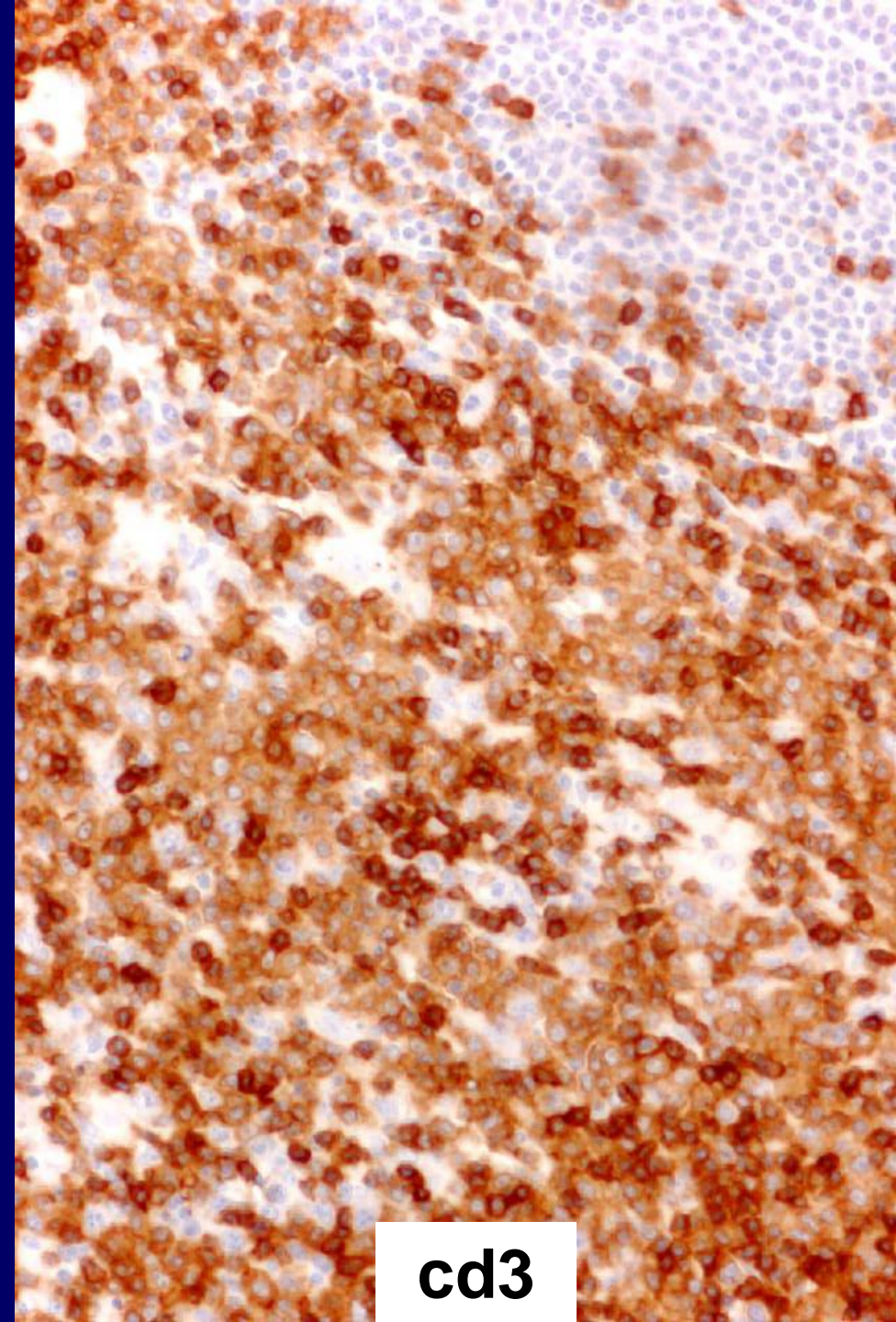
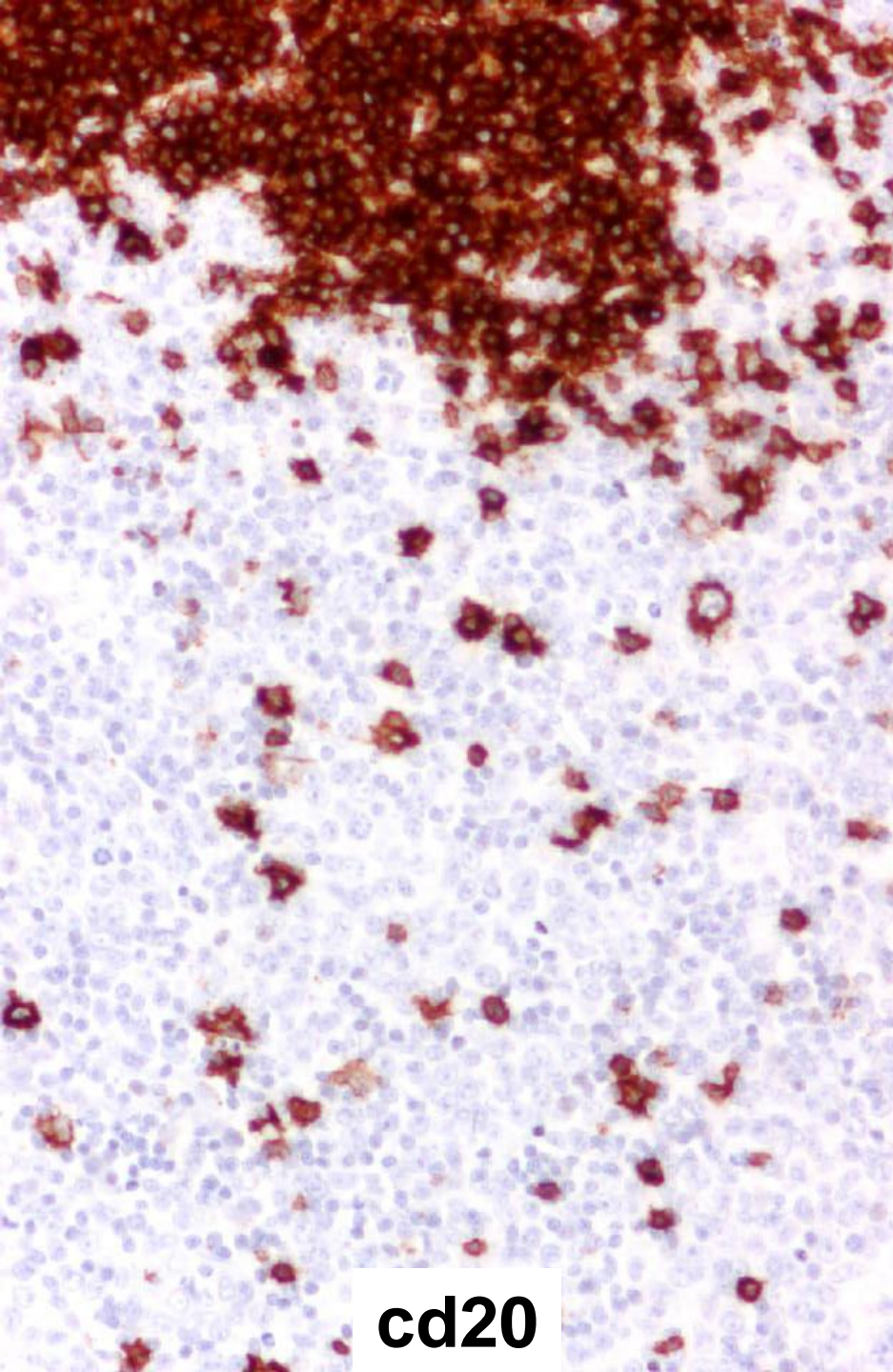
2007 peau : MF transformé avec grandes c/ T cd30 + , intra-épidermiques et dermiques, granulome épithélioïde à rattacher au MF (Zielh -)

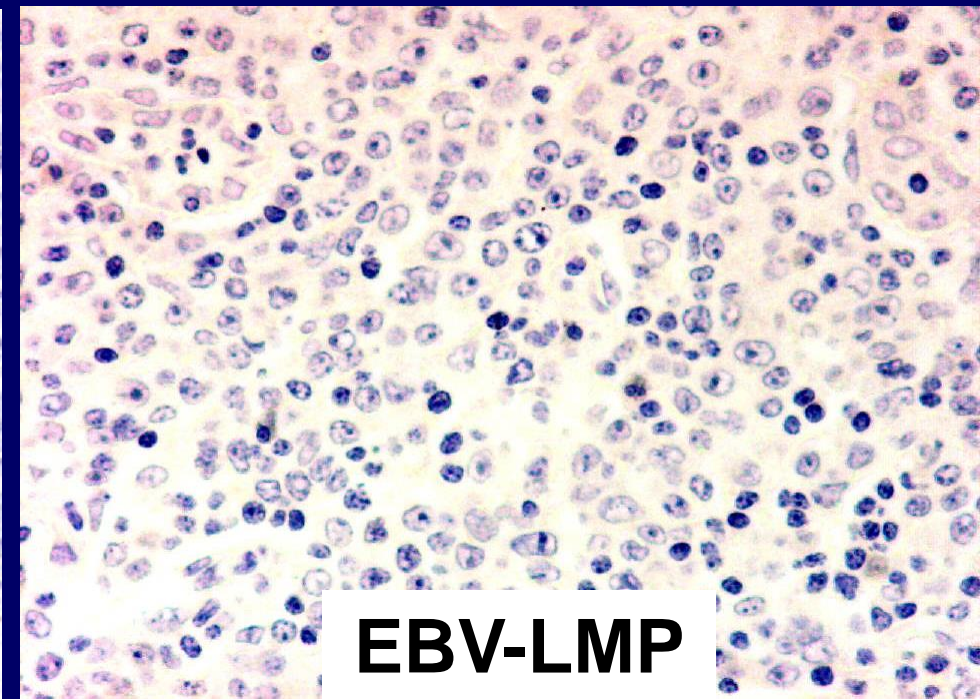
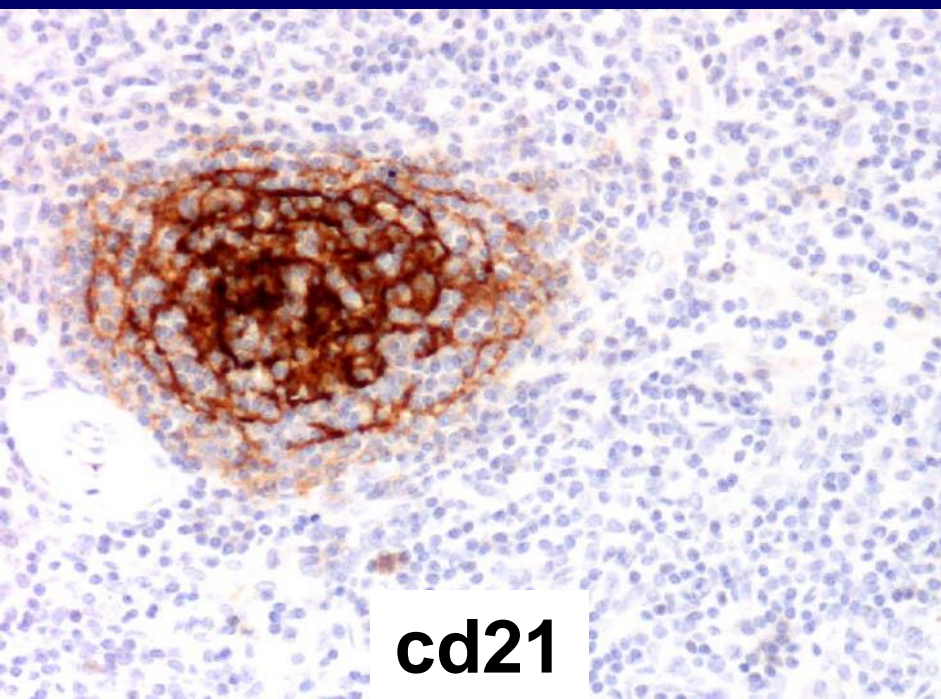
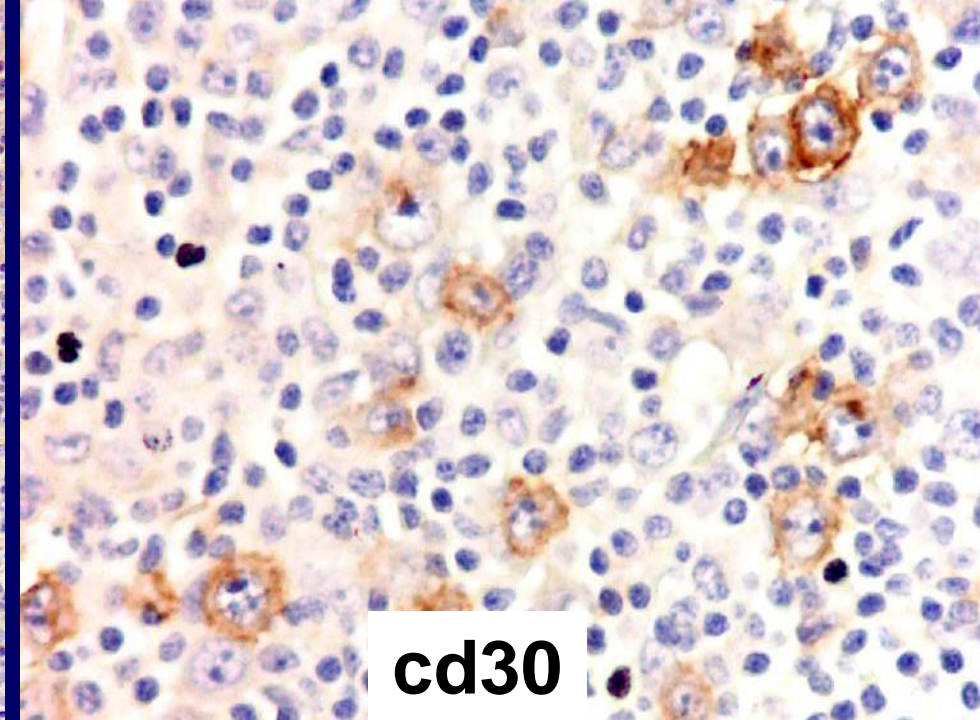
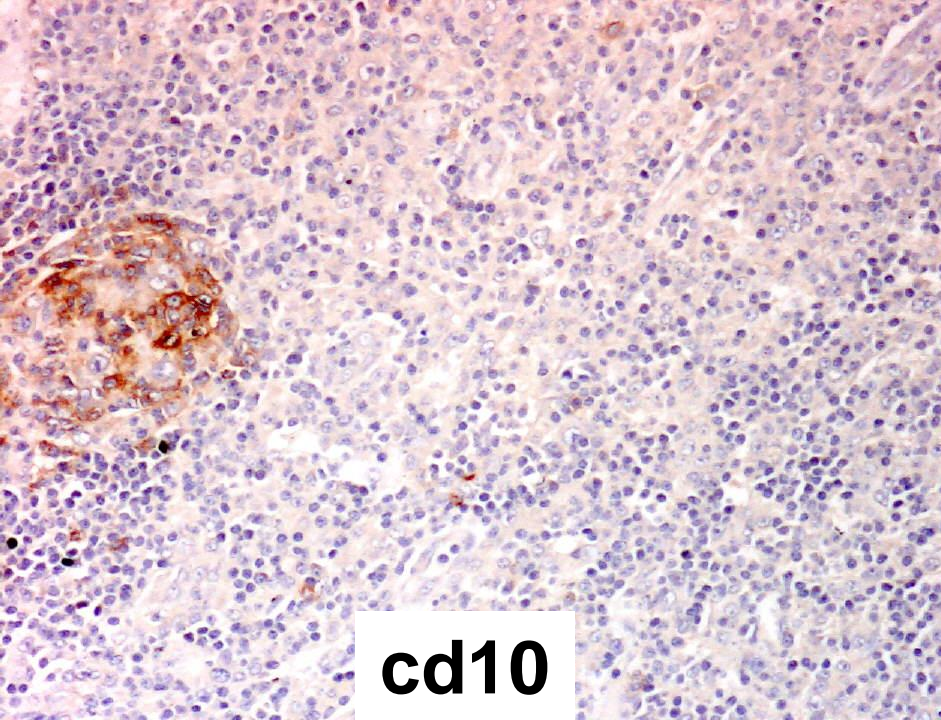
Avis Pr De mascarel

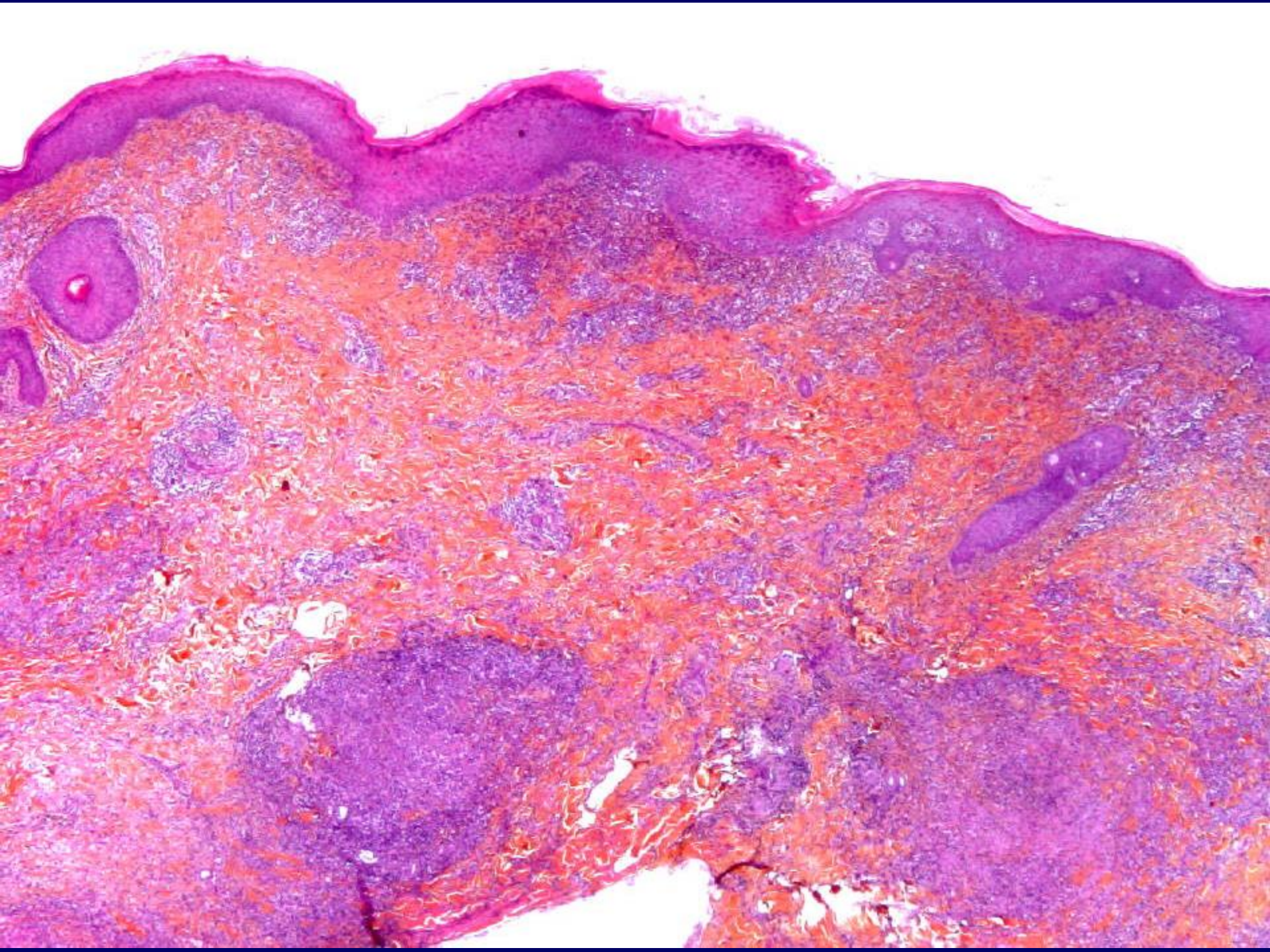


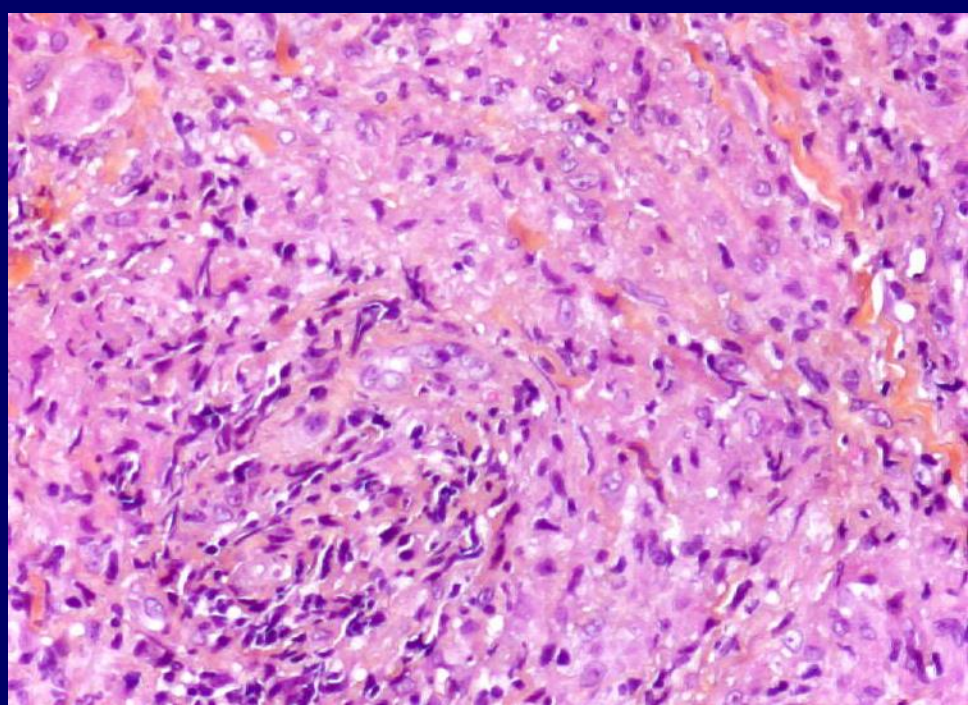
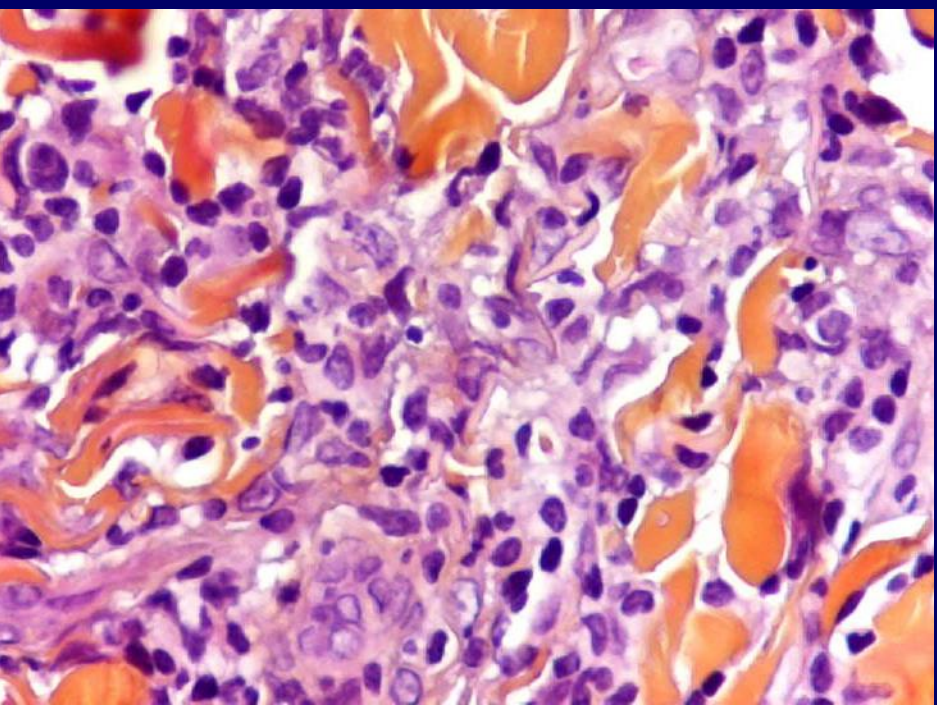
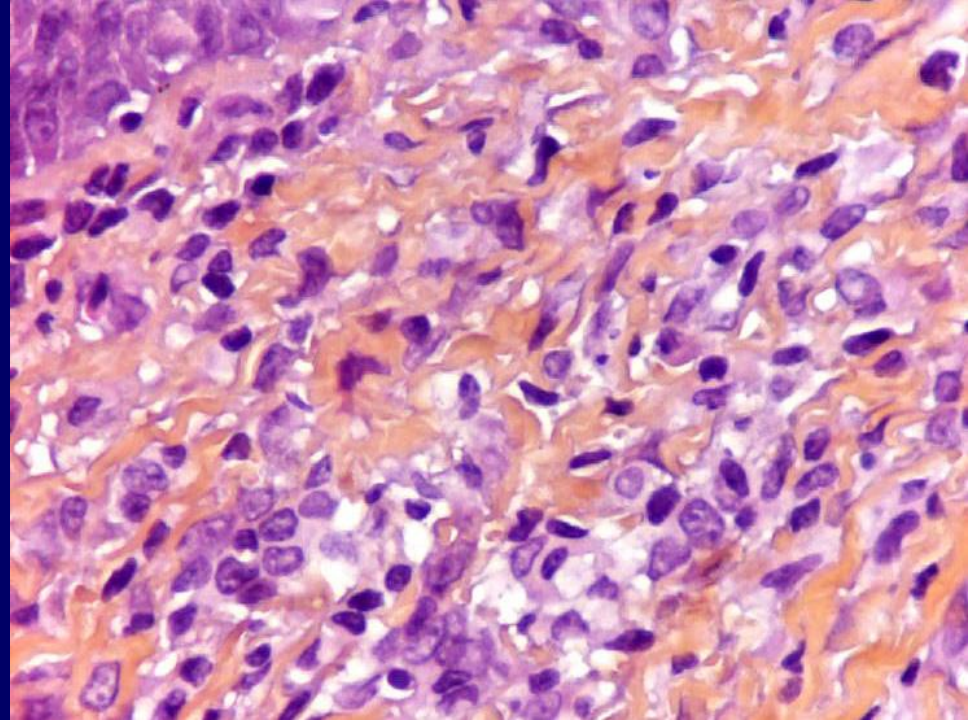
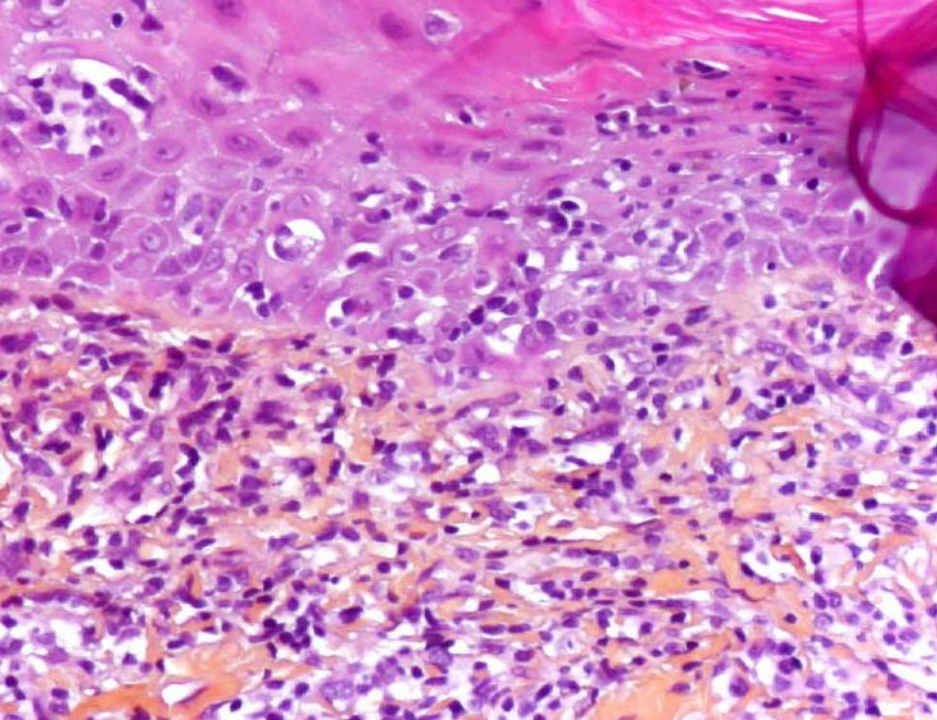


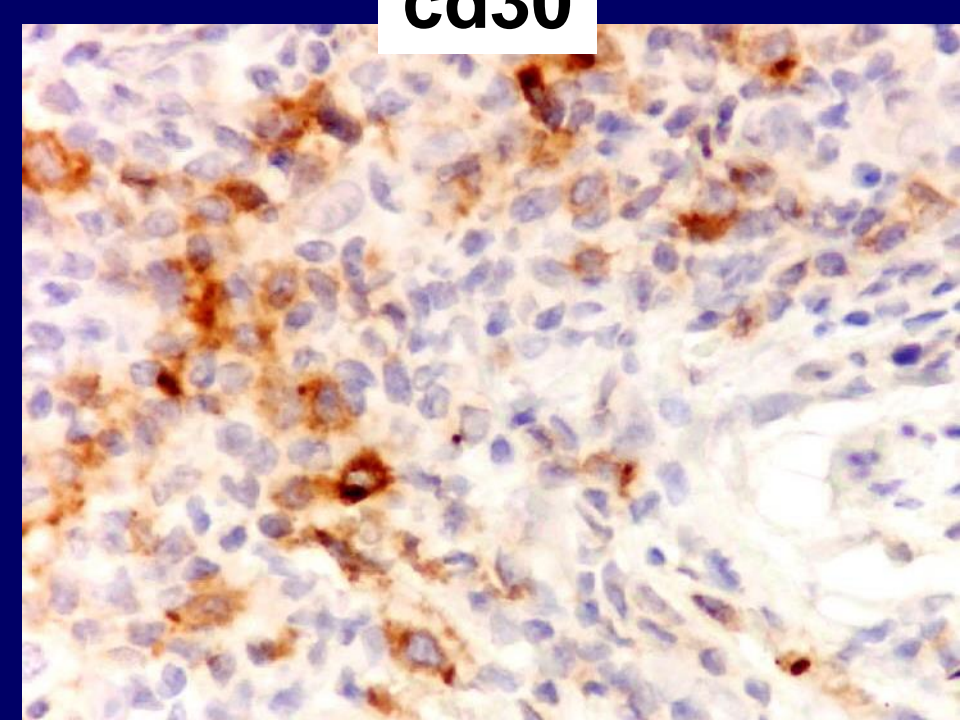
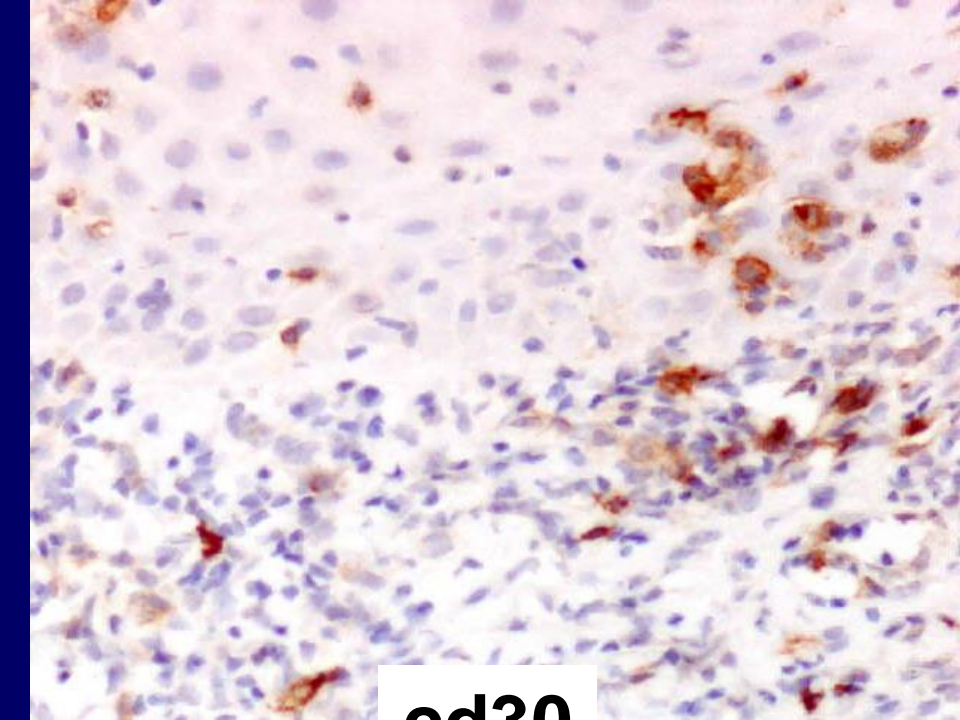
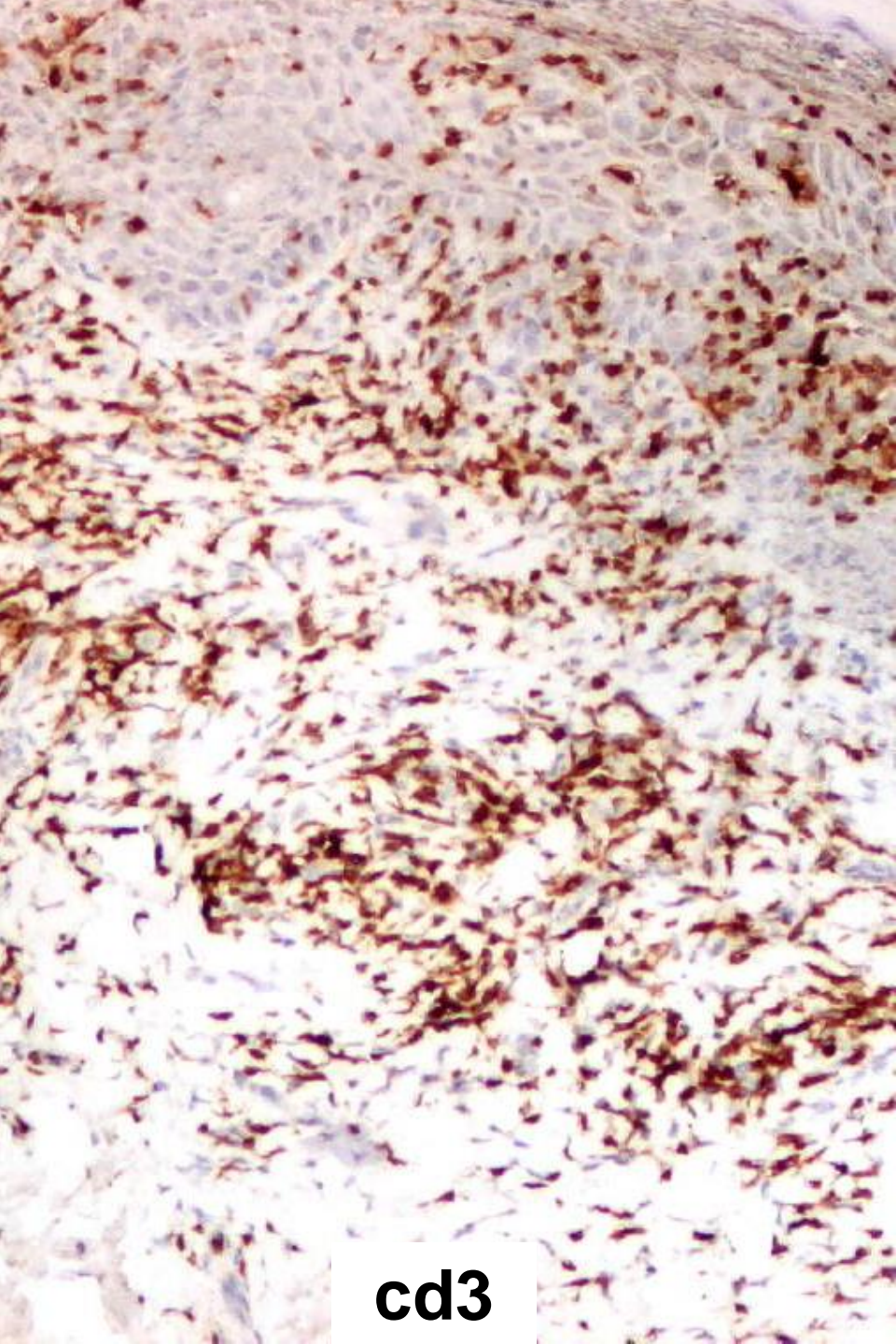












Diagnostic retenu par Pr De Mascarel

**1997 : localisation ganglionnaire du
MF transformé**

**2007 peau : MF transformé avec
grandes c/ T cd30 + , intra-
épidermiques et dermiques,
granulome épithélioïde à rattacher
au MF (Zielh -)**