

Cas clinique

Kalai K, Mezlini A, El May
A

Institut Salah Azaiz

Observation

- Mr A.A., 59 ans, atcds de diabète type 2, ancien tabagique
- Consulte pour tuméfaction latérocervicale droite de 6cm de GA évoluant depuis 3 mois

Clinique

- **Examen:** Adénopathie jugulo carotidienne droite haute de 6cm de GA, fixe, indolore
Reste des aires ganglionnaires: libre
Pas d'hépatosplénomégalie
- PS à 1
- **Panendoscopie:** larynx, œsophage, cavum : libres

Biologie

- VS à 12/ 38
- GB=8410/mm³, Hb=13.7g/dl
plt=242000/mm³
- LDH = 328
- uricémie: nle

1ère biopsie ganglionnaire

- Persistance de follicules lymphoïdes, des amas de cellules histiocytaïres, cellules de grandes taille à noyau nucléolé (immunoblastes?) .
- I.H.C : CD15, CD 30: négatifs.
Pan B, Pan T: marquage non

Evolution: (3 mois)

- apparition d'adp cervicales bilatérales et axillaires de 1 à 2 cm de GA.

2ème biopsie ganglionnaire

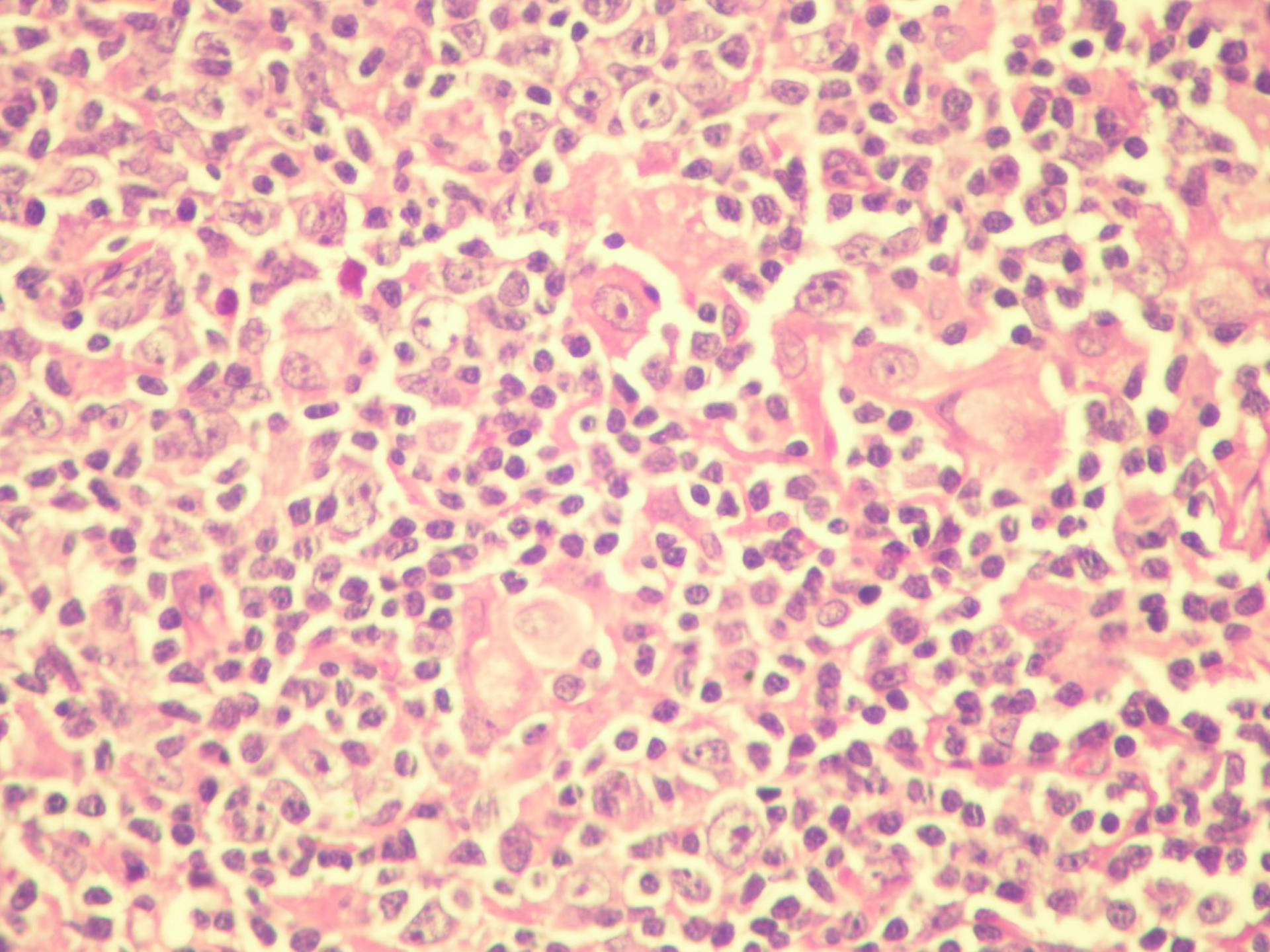
- Aspect de prolifération cellulaire de type B de siège périfolliculaire avec des cellules lymphoplasmocytaires et des cellules de plus grande taille
- I.H.C: CD 20, Bcl2: positifs
CD 15, CD 30, CD 21, CD 23:

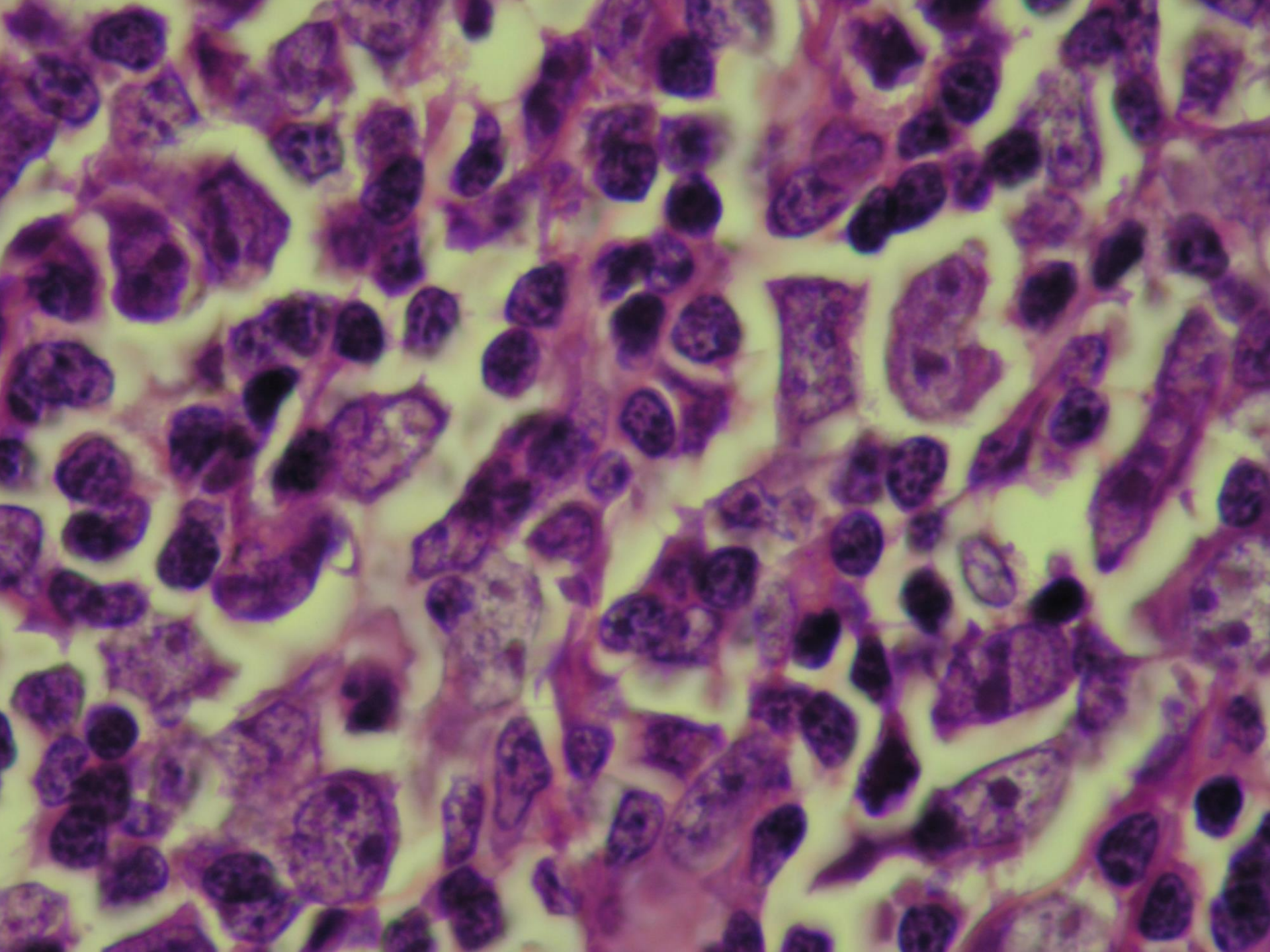
Bilan d'extension

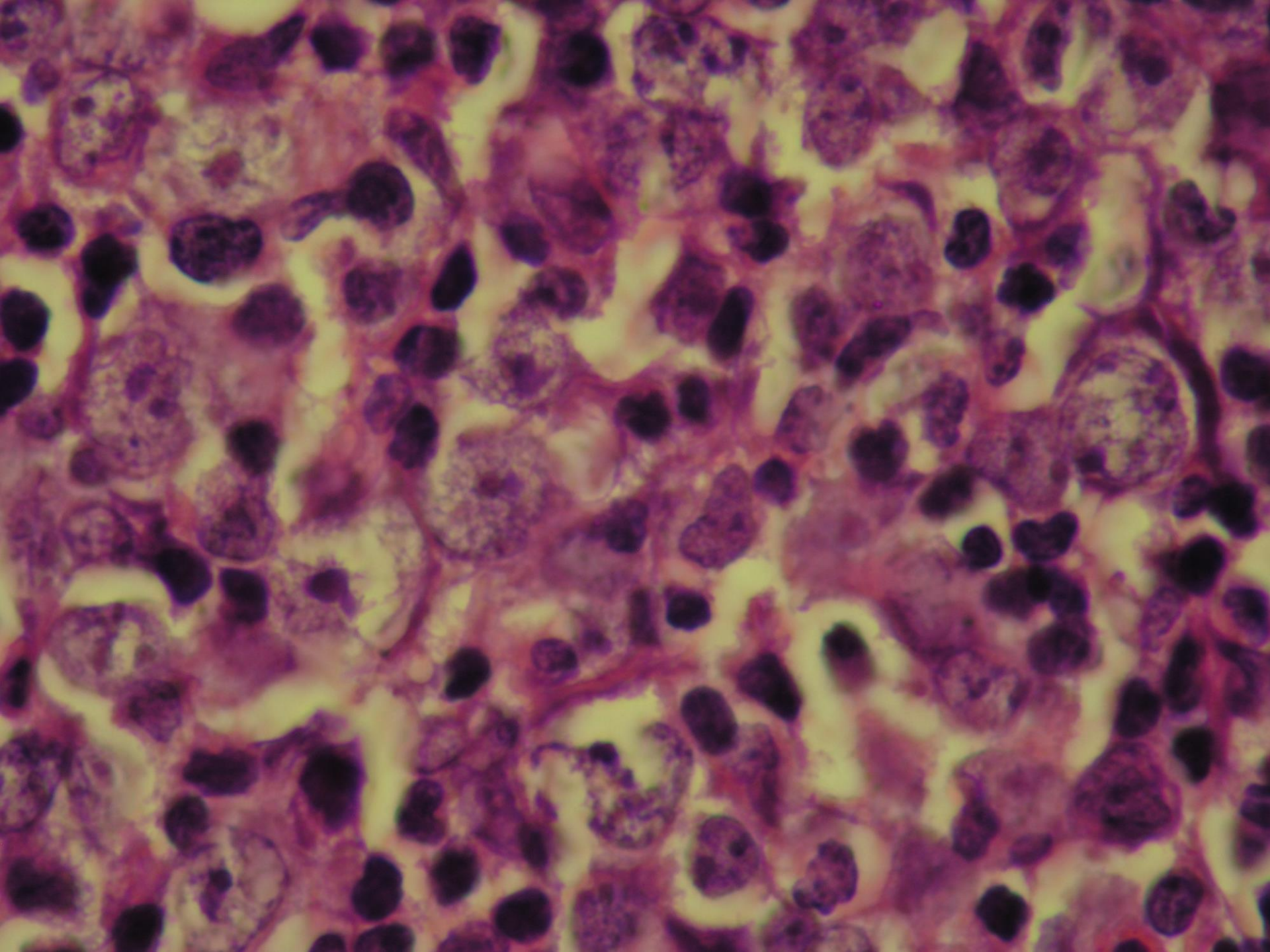
- **FOGD**: gastropathie congestive fundique, biopsies: pangastrite chronique HP (1+)
- **Panendoscopie**: RAS , biopsie du cavum: négative
- **BOM**: RAS
- **TDM thoraco-abdominale**: pas de localisation ganglionnaire profonde ni viscérale

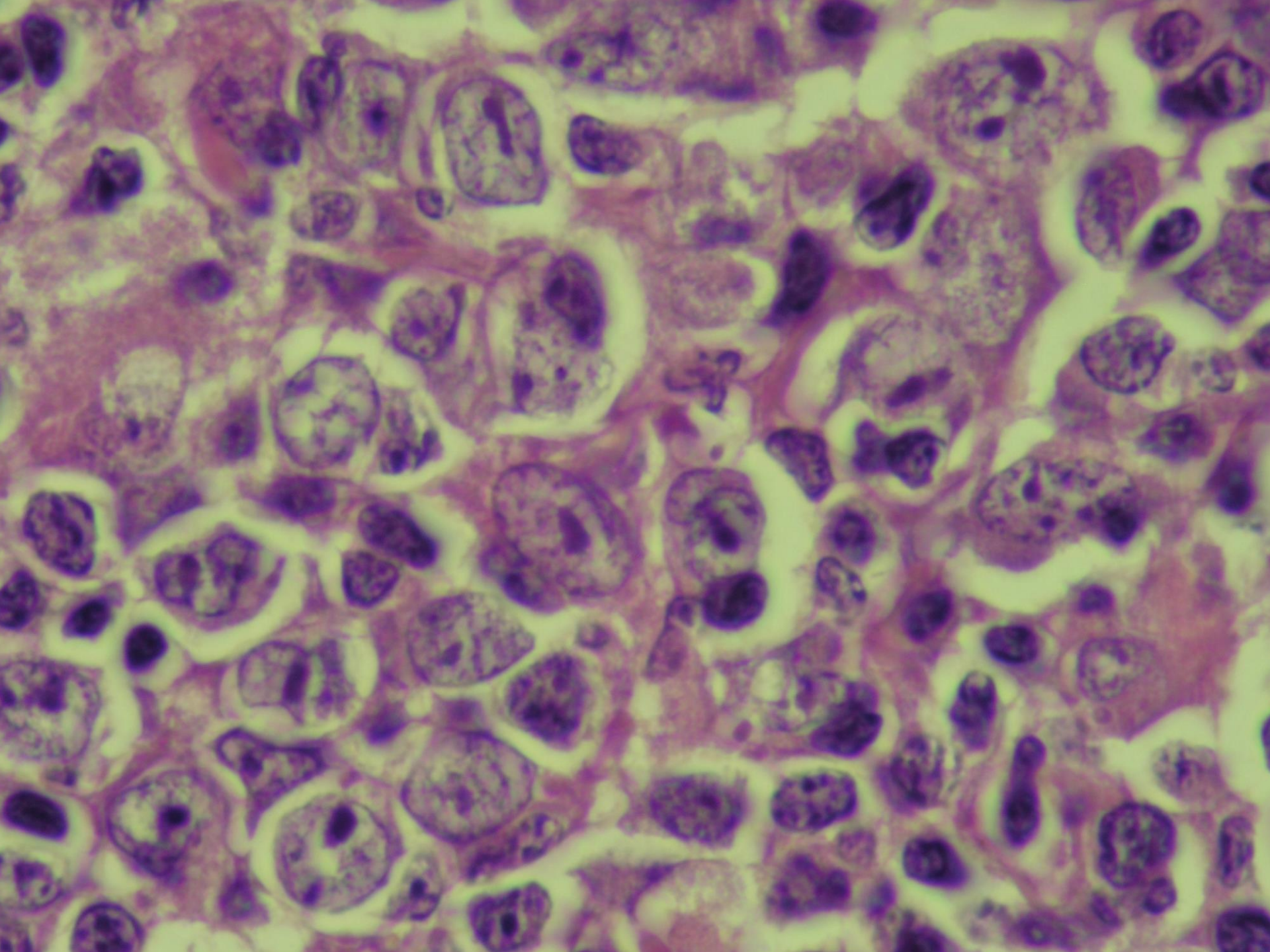
Question :

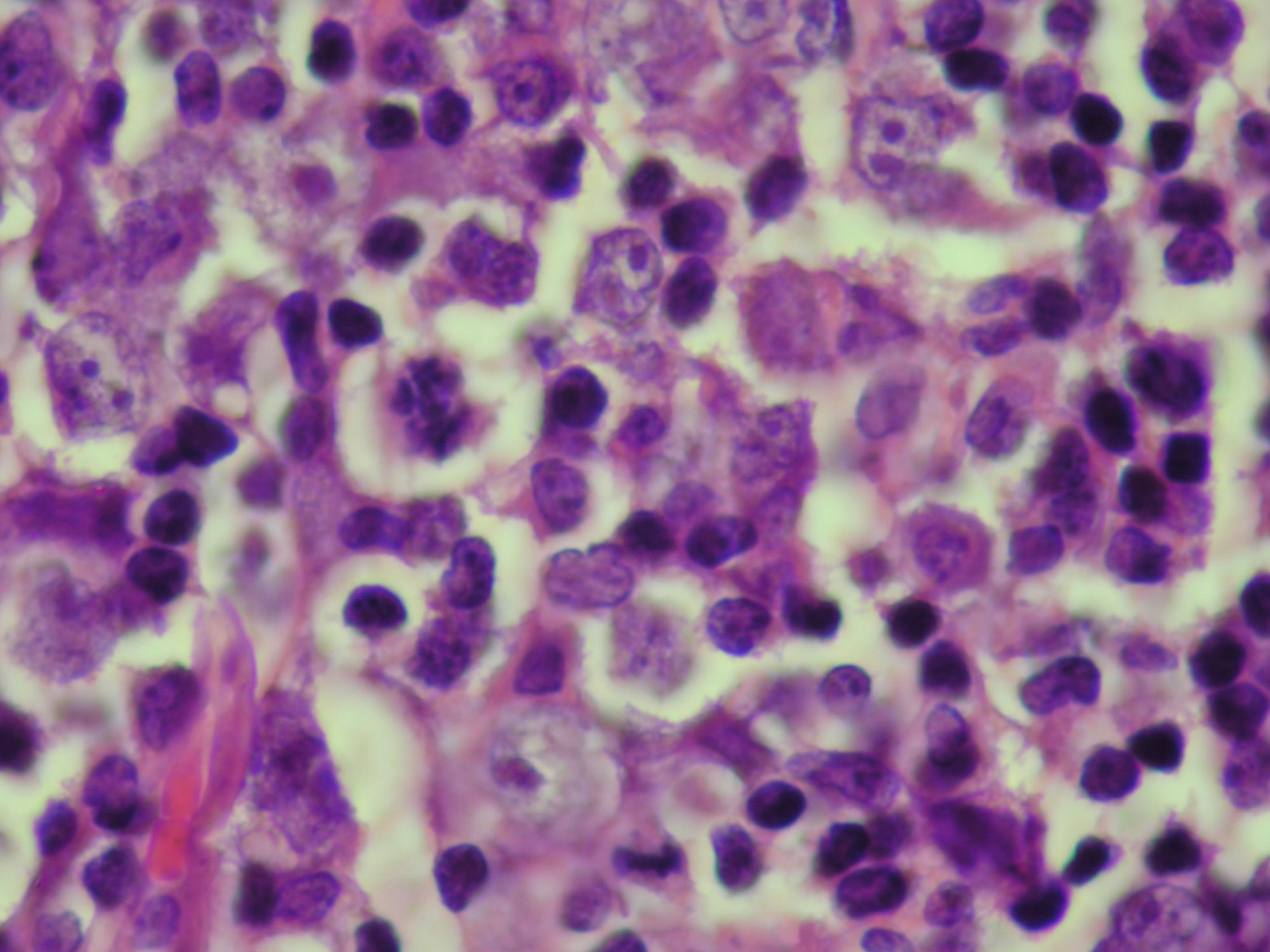
- *S'agit-il d'un lymphome des zones marginales ganglionnaires cervicales ou d'une pathologie du système des phagocytes mononucléés?*

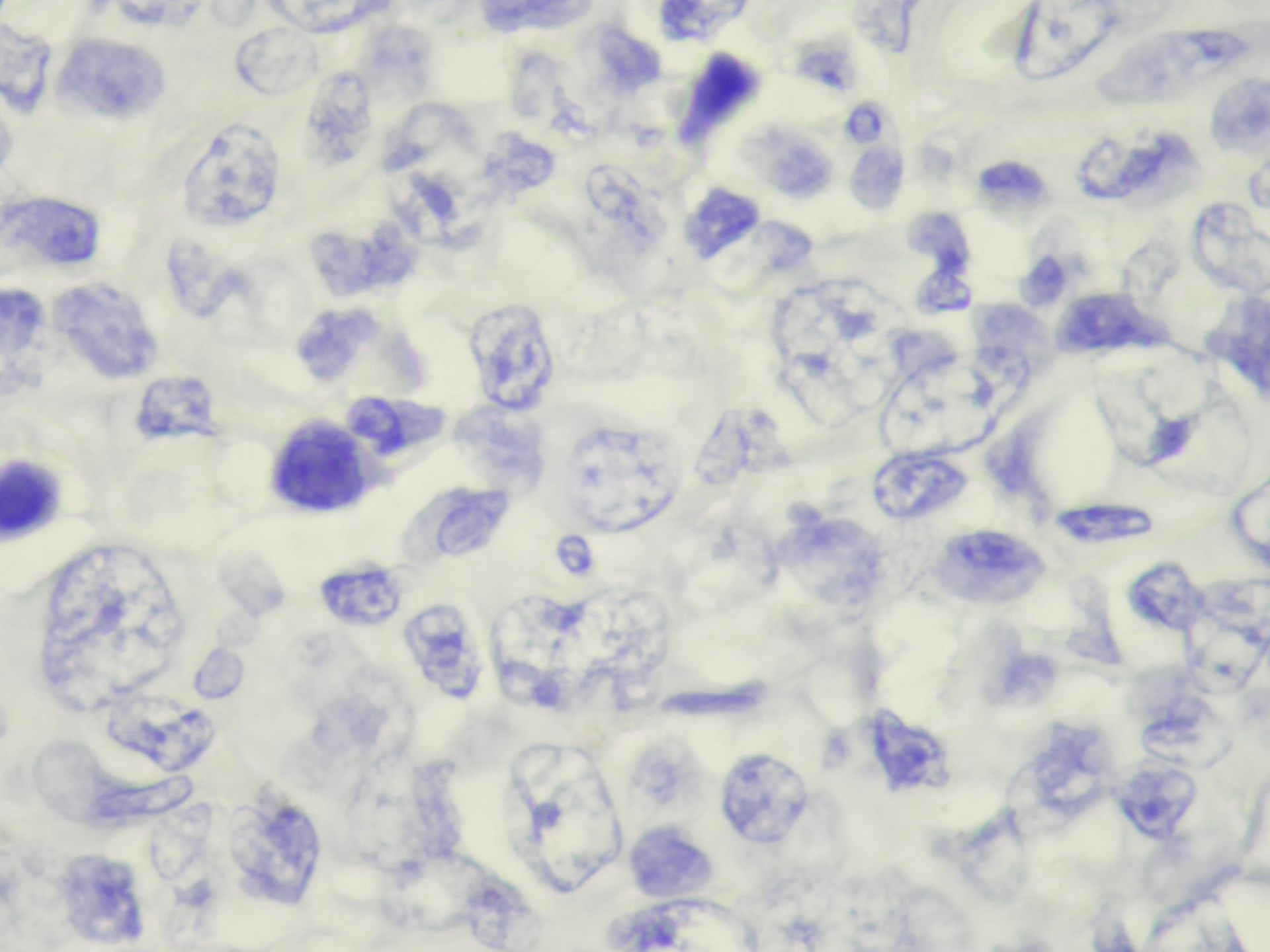


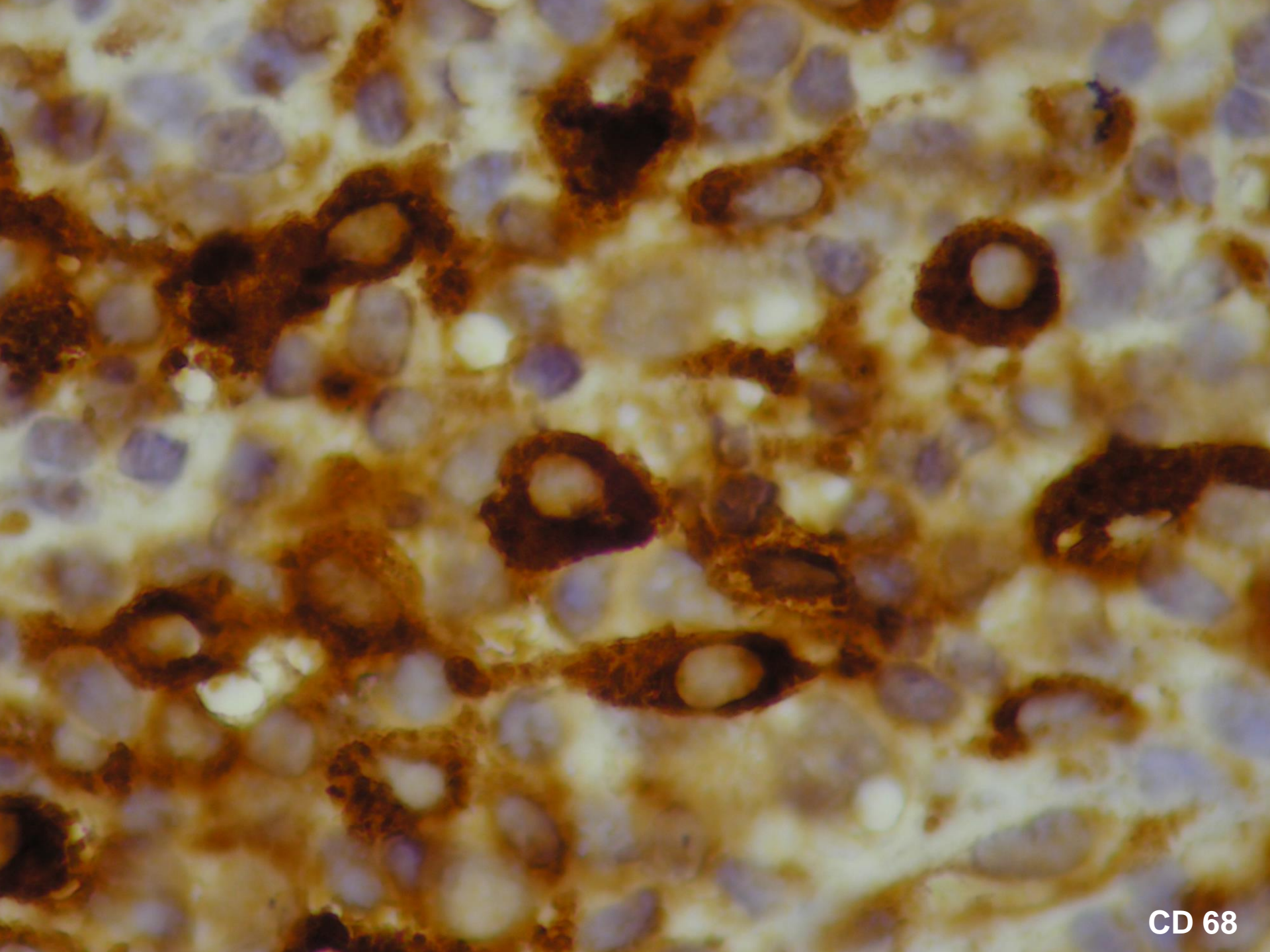




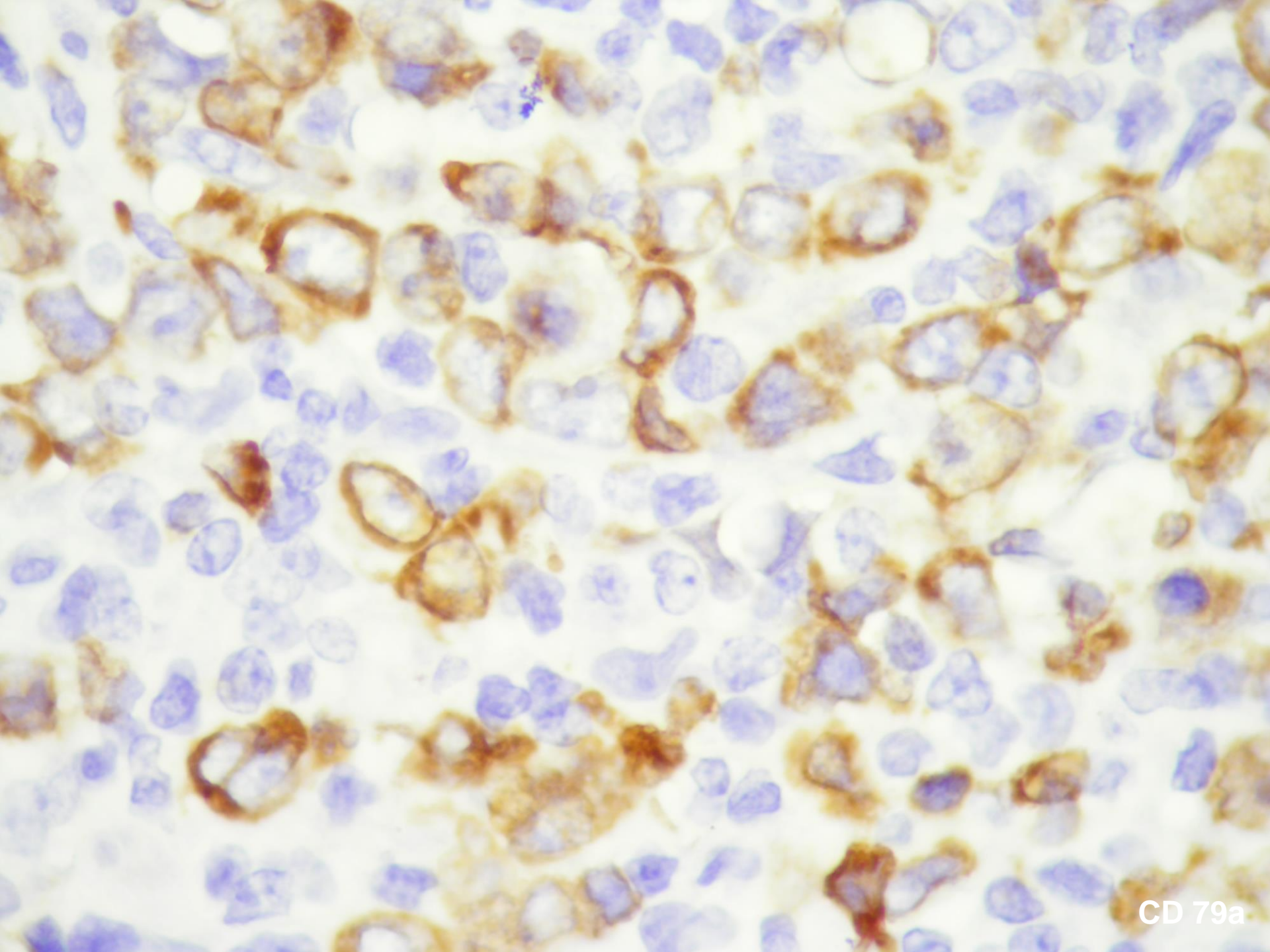




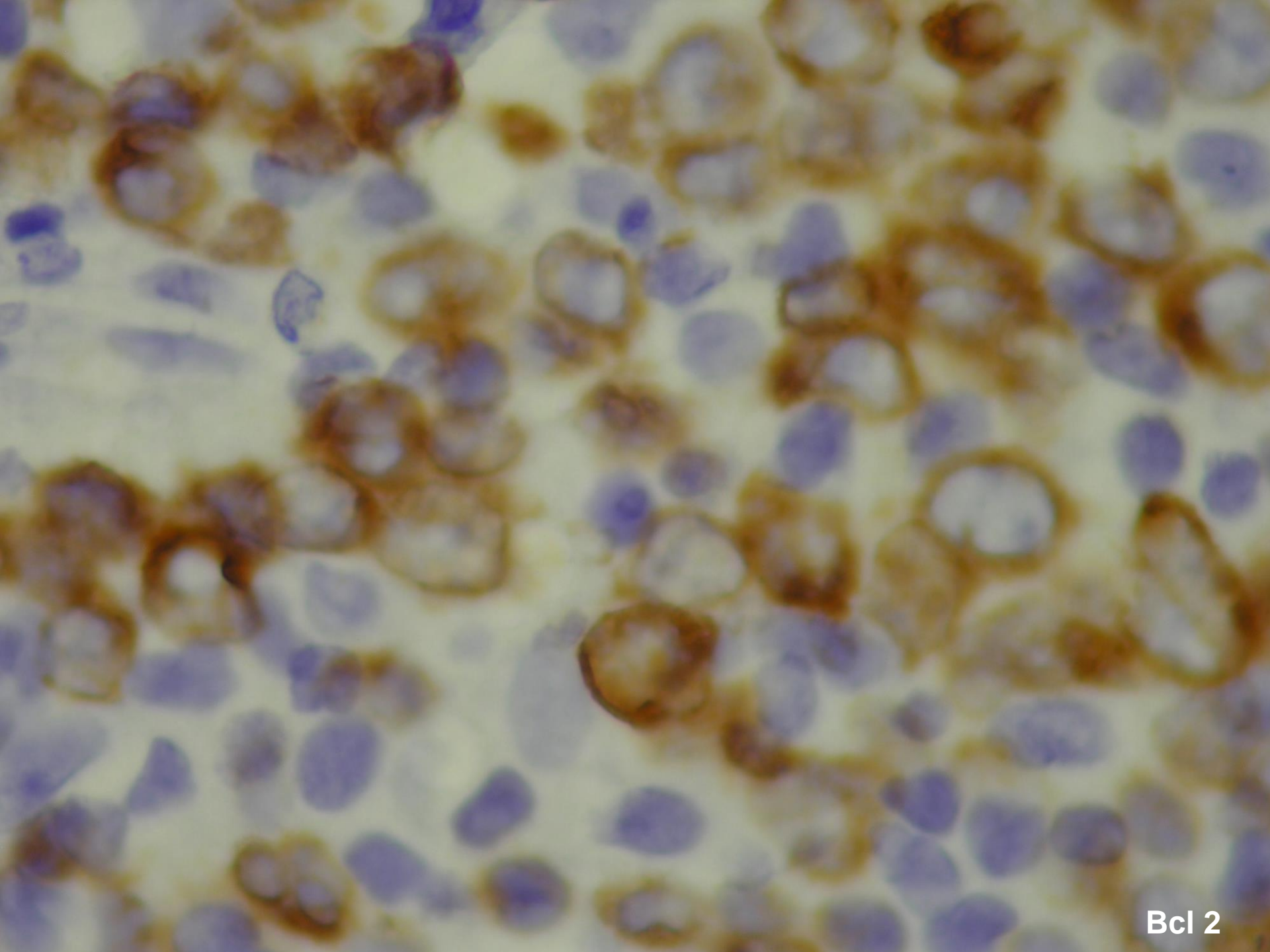




CD 68



CD 79a

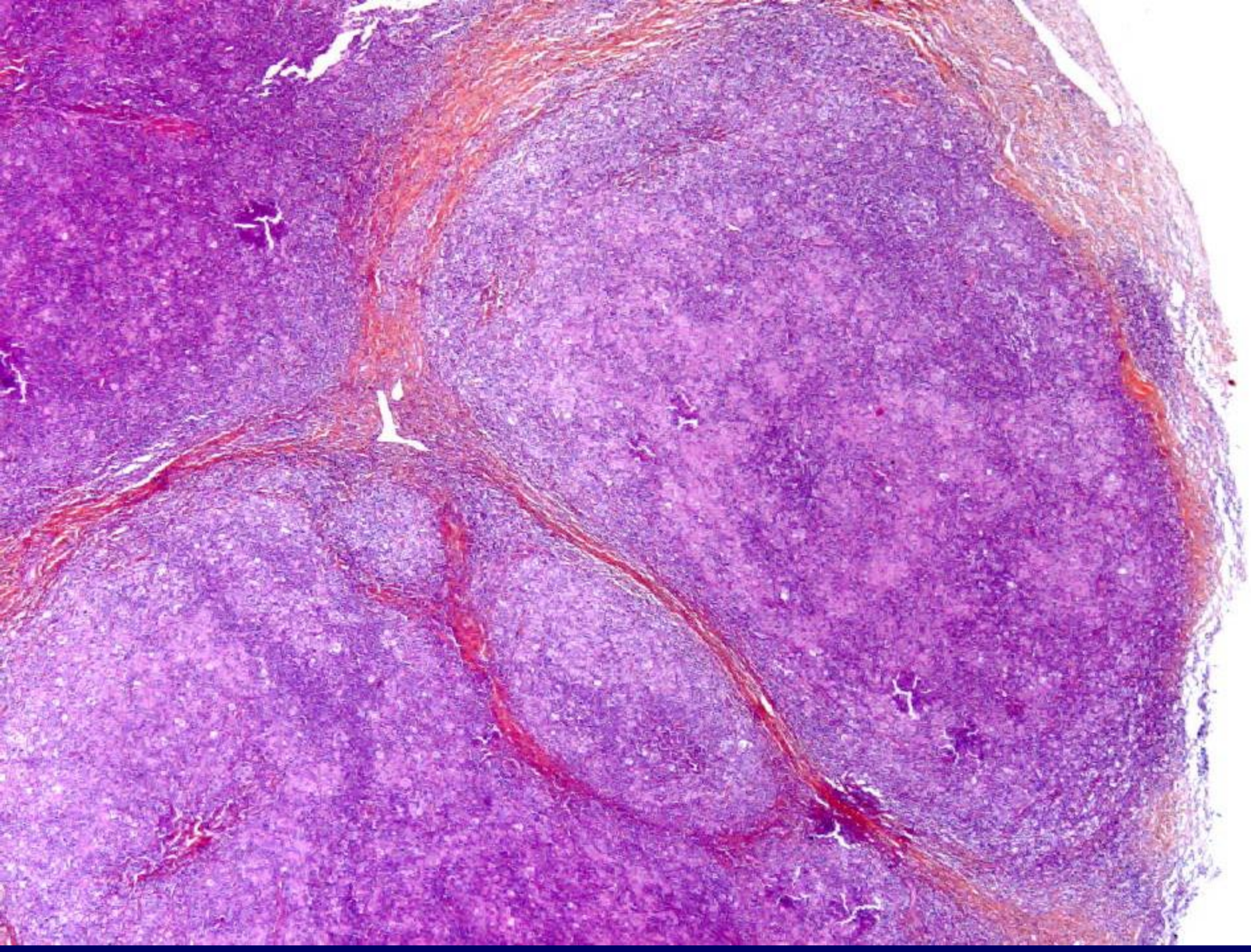


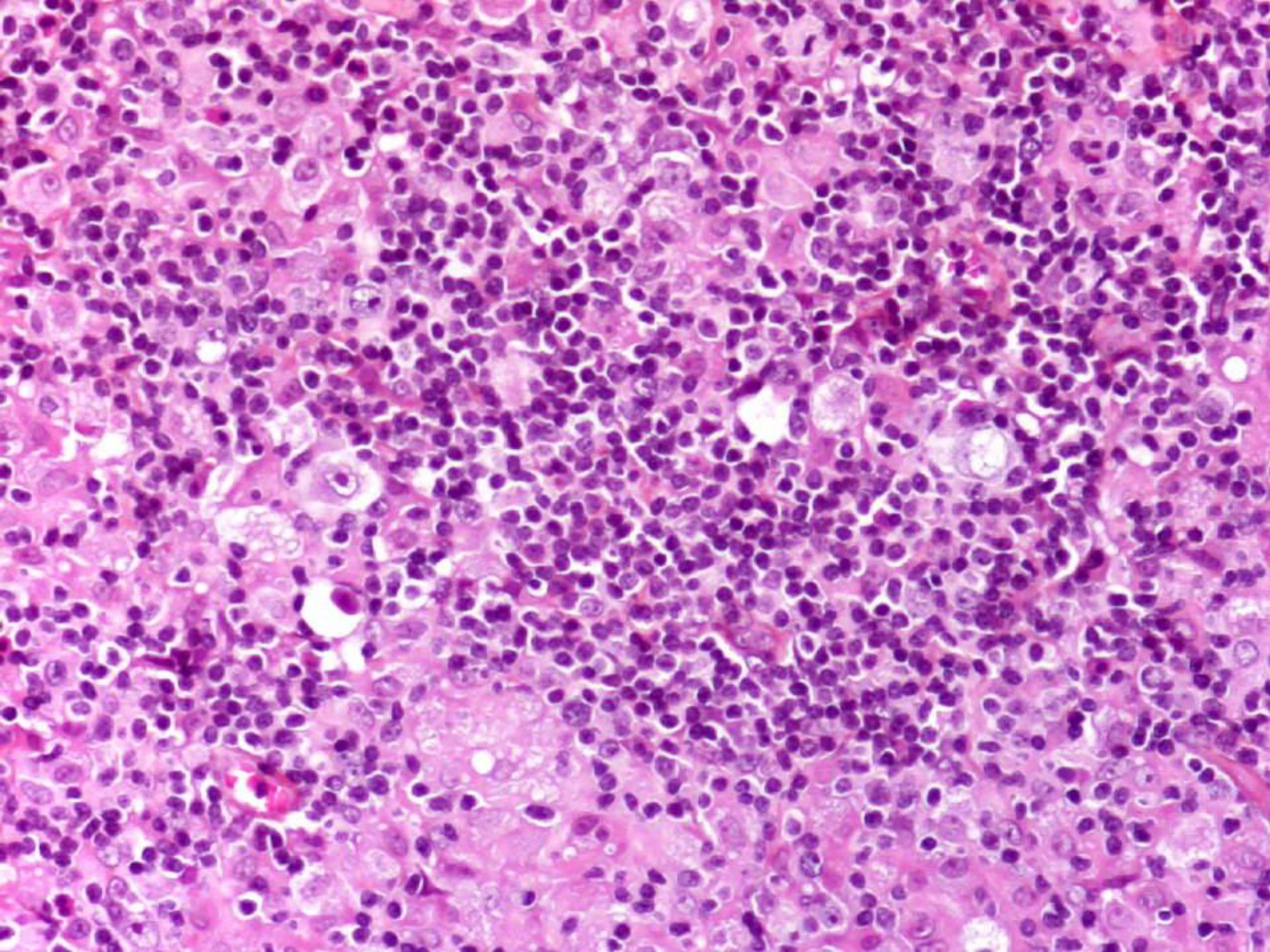
Bcl 2

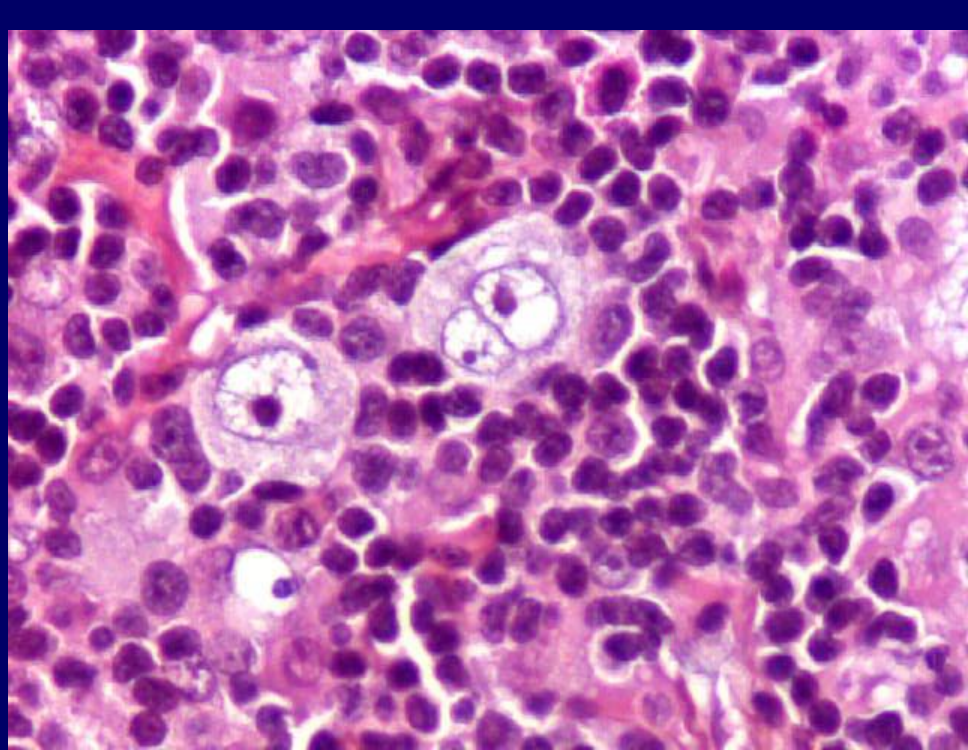
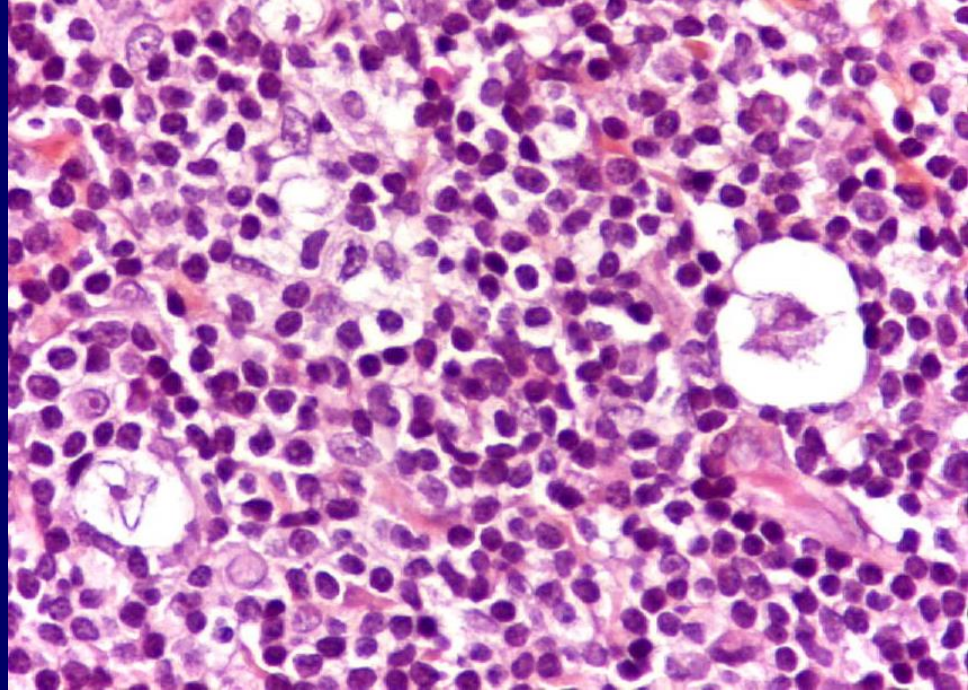
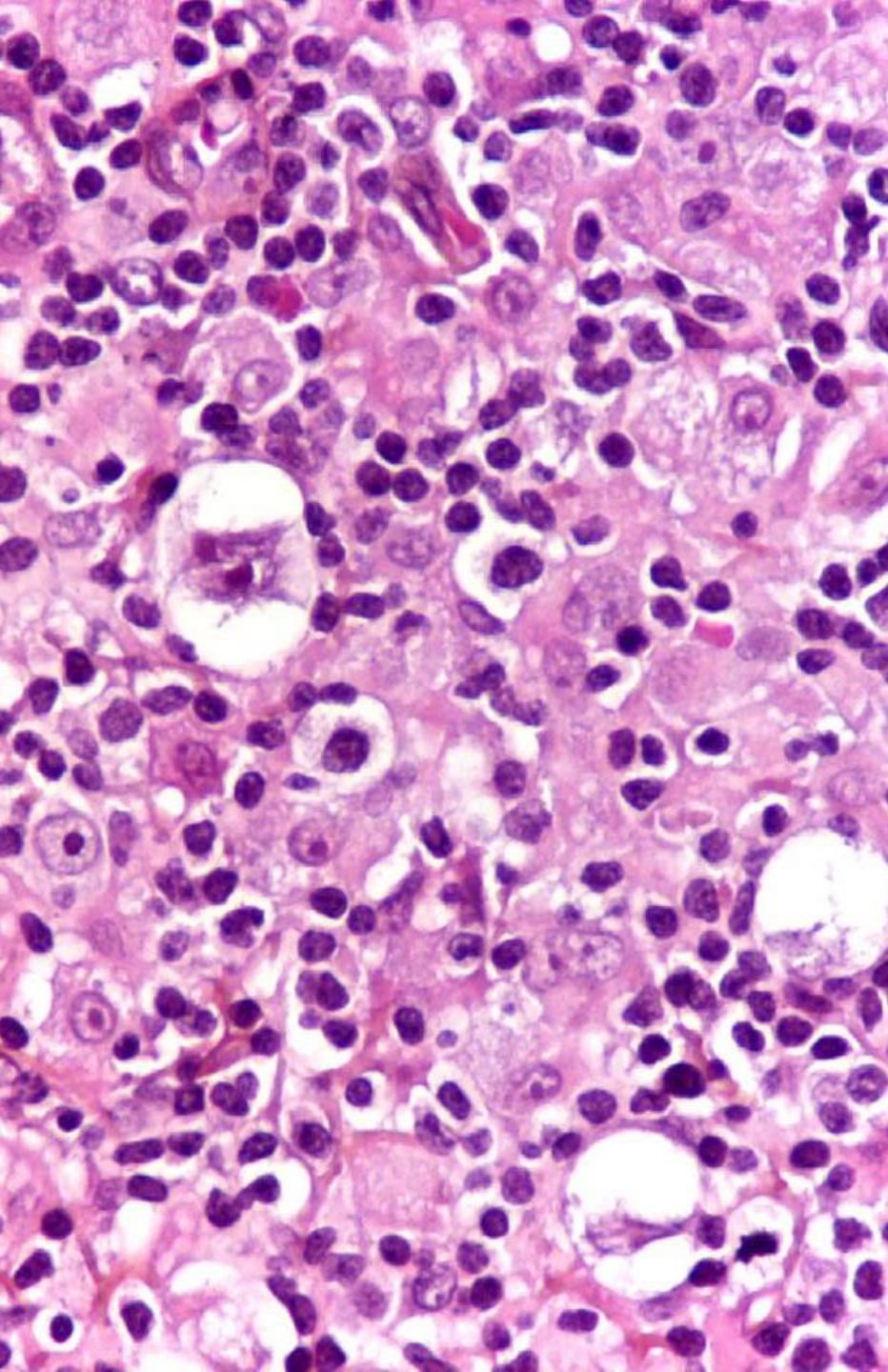
N° 10

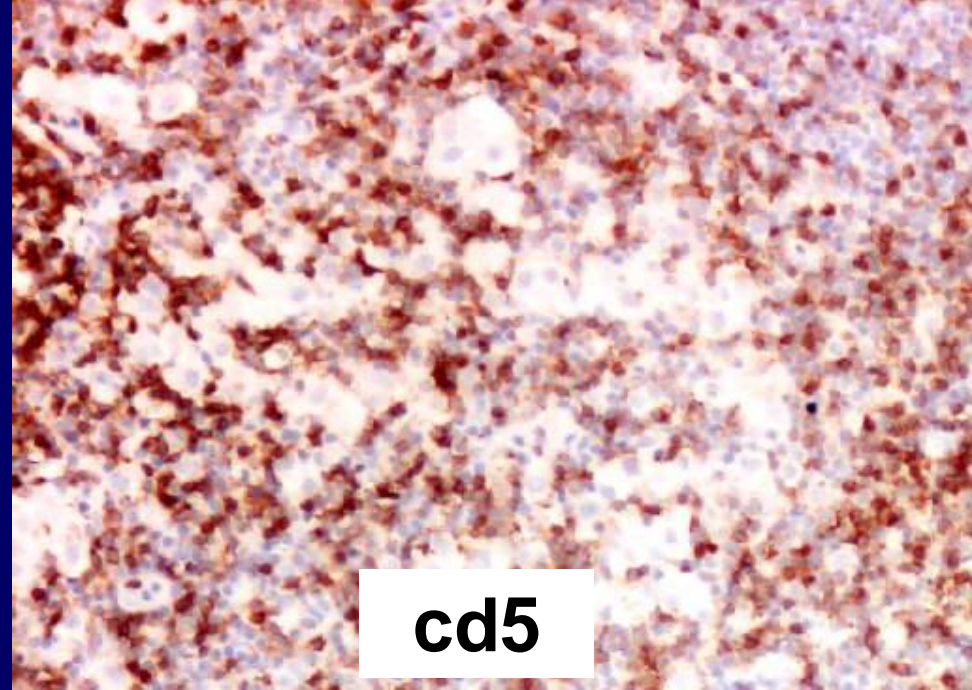
- **Homme de 59 ans**
- **Adénopathie jugulo-carotidienne droite de 6 cm + adénopathie cervicale et axillaire latéral**

- **Biopsie ganglionnaire : A34713**
- **Biopsie ganglionnaire : A36722**

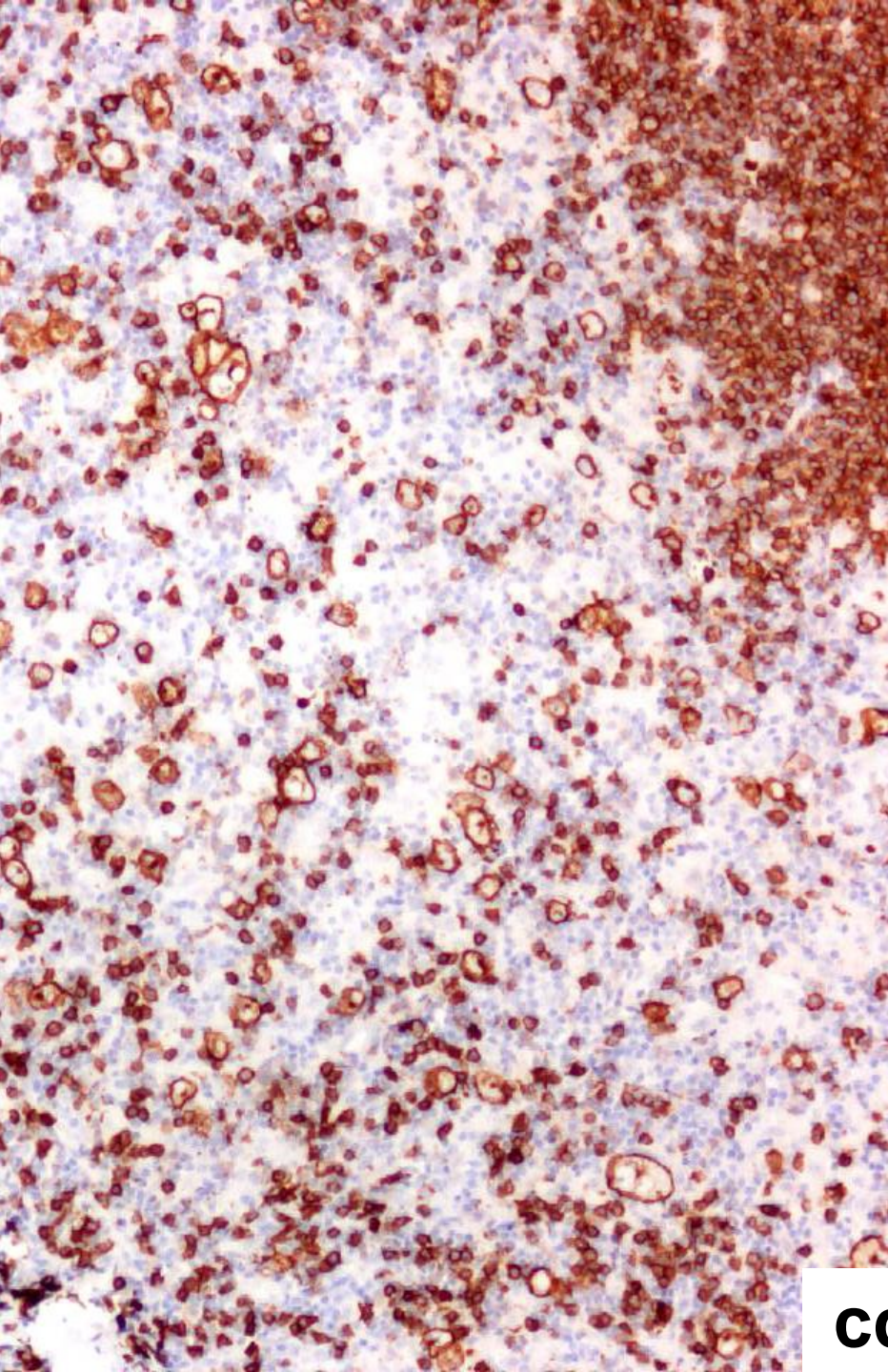




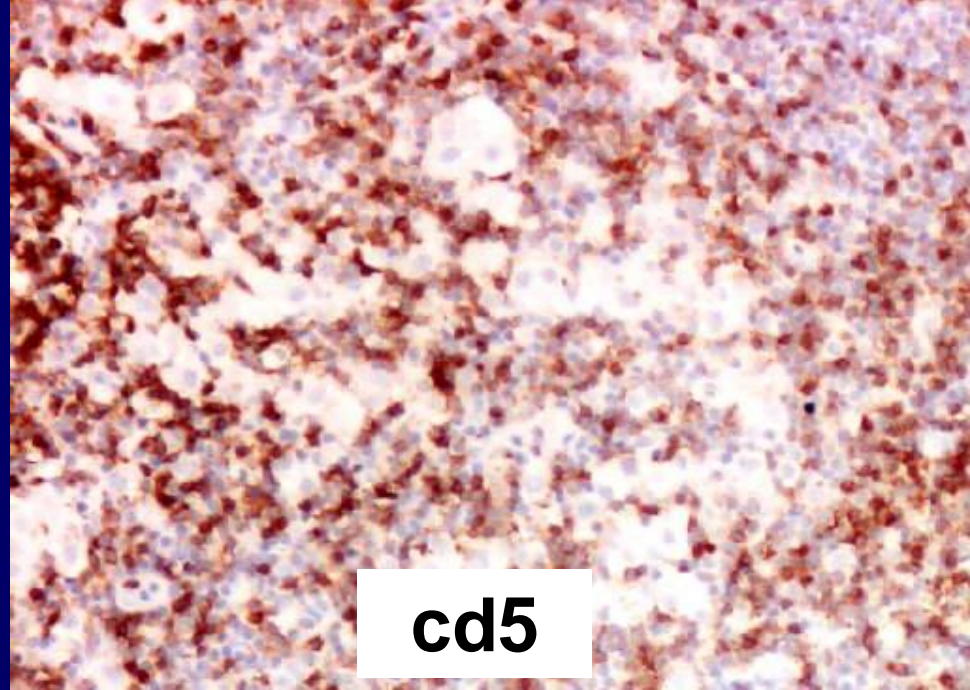




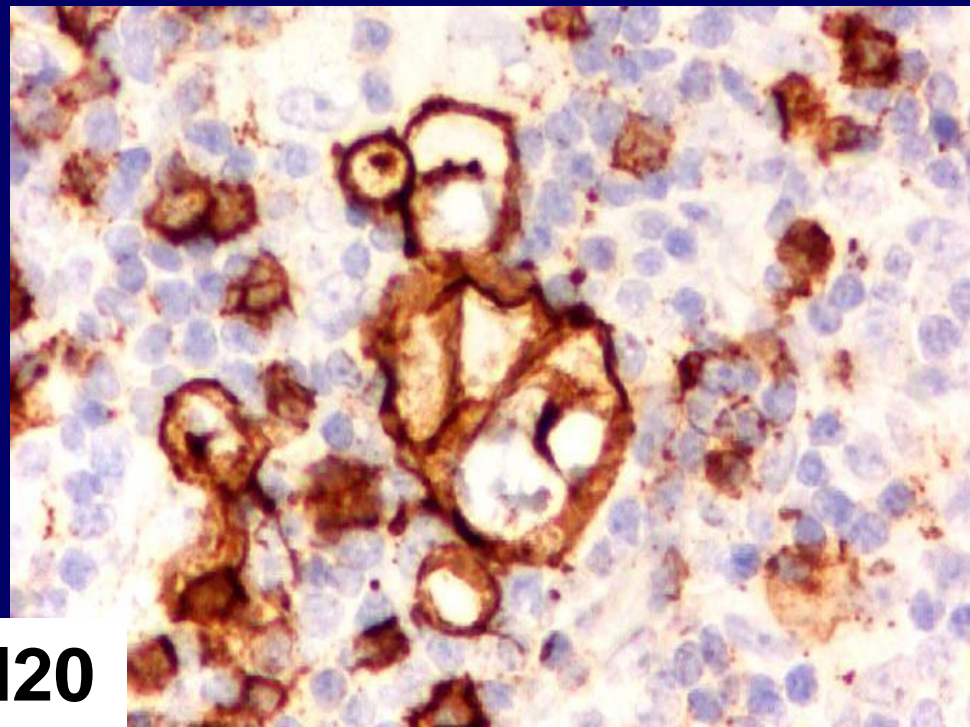
cd5

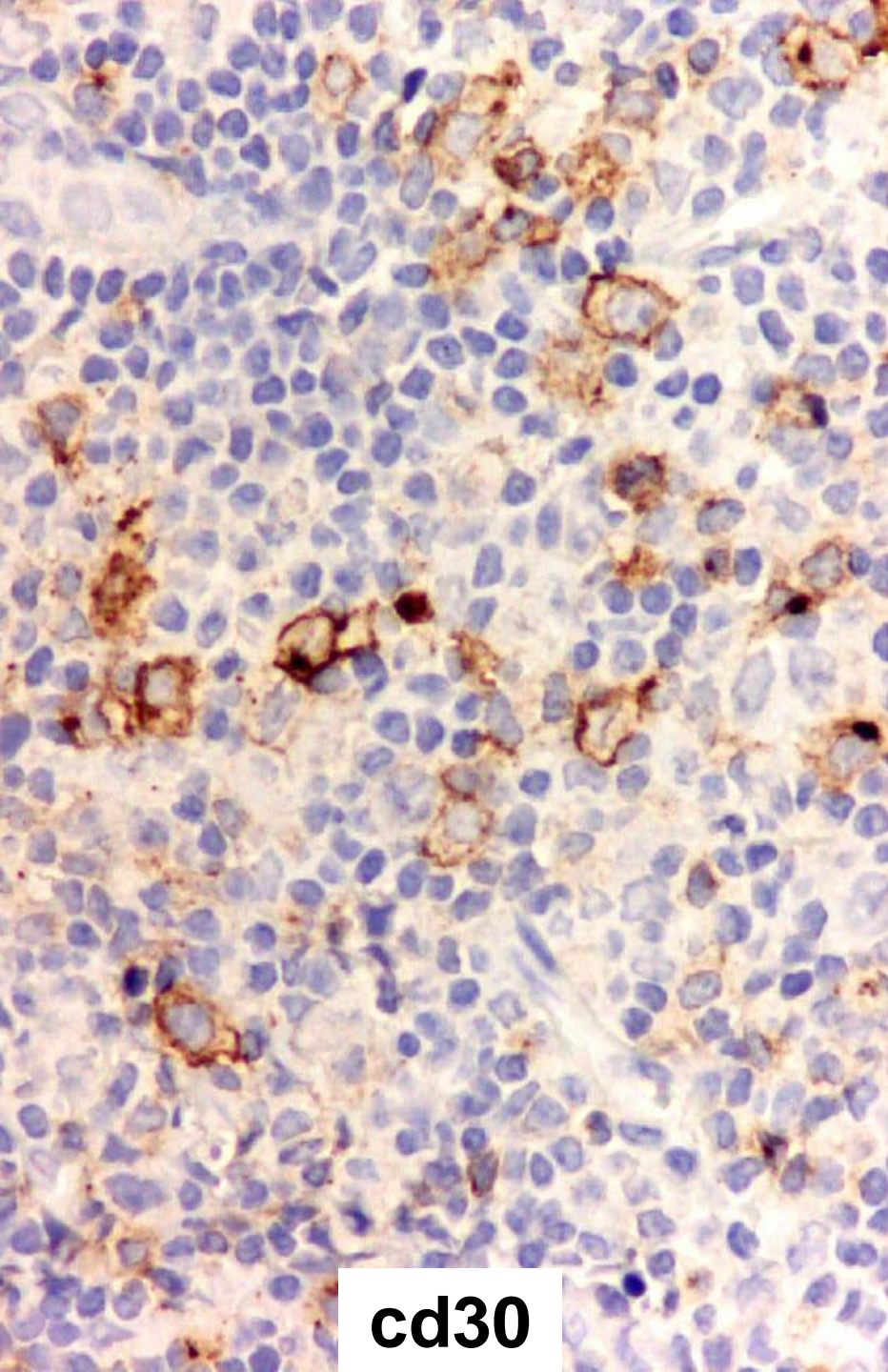


cd20

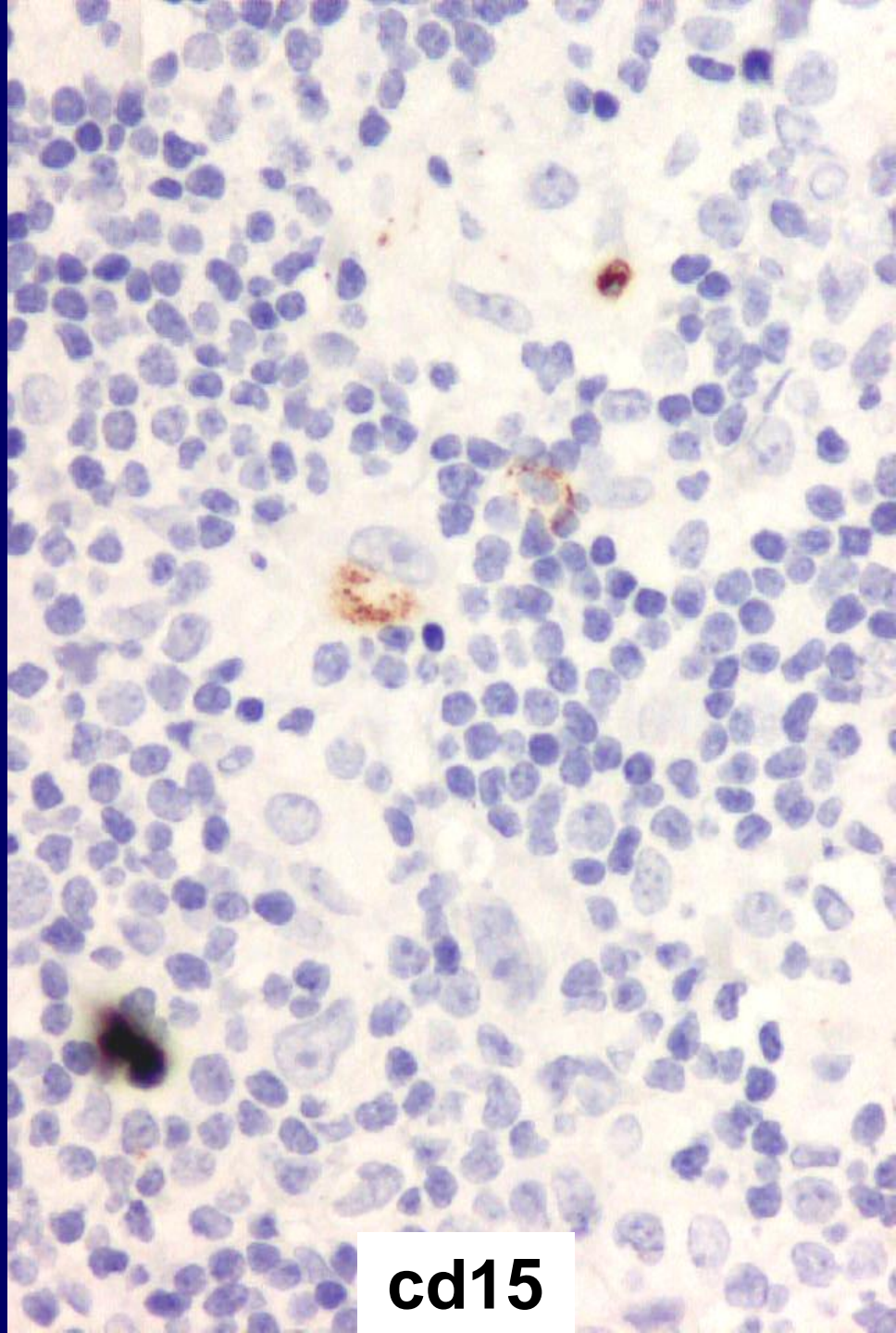


cd5





cd30



cd15

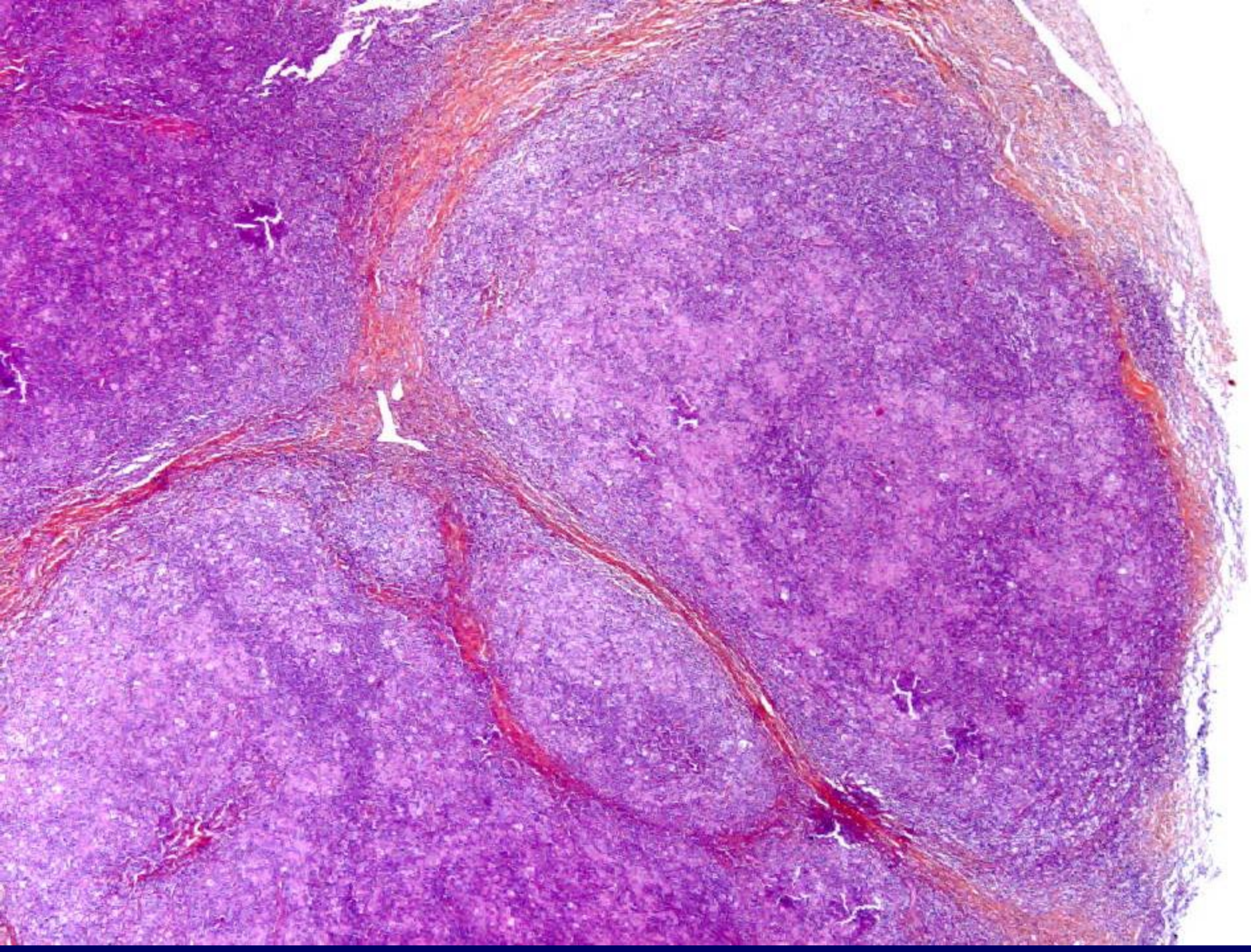
N° 10

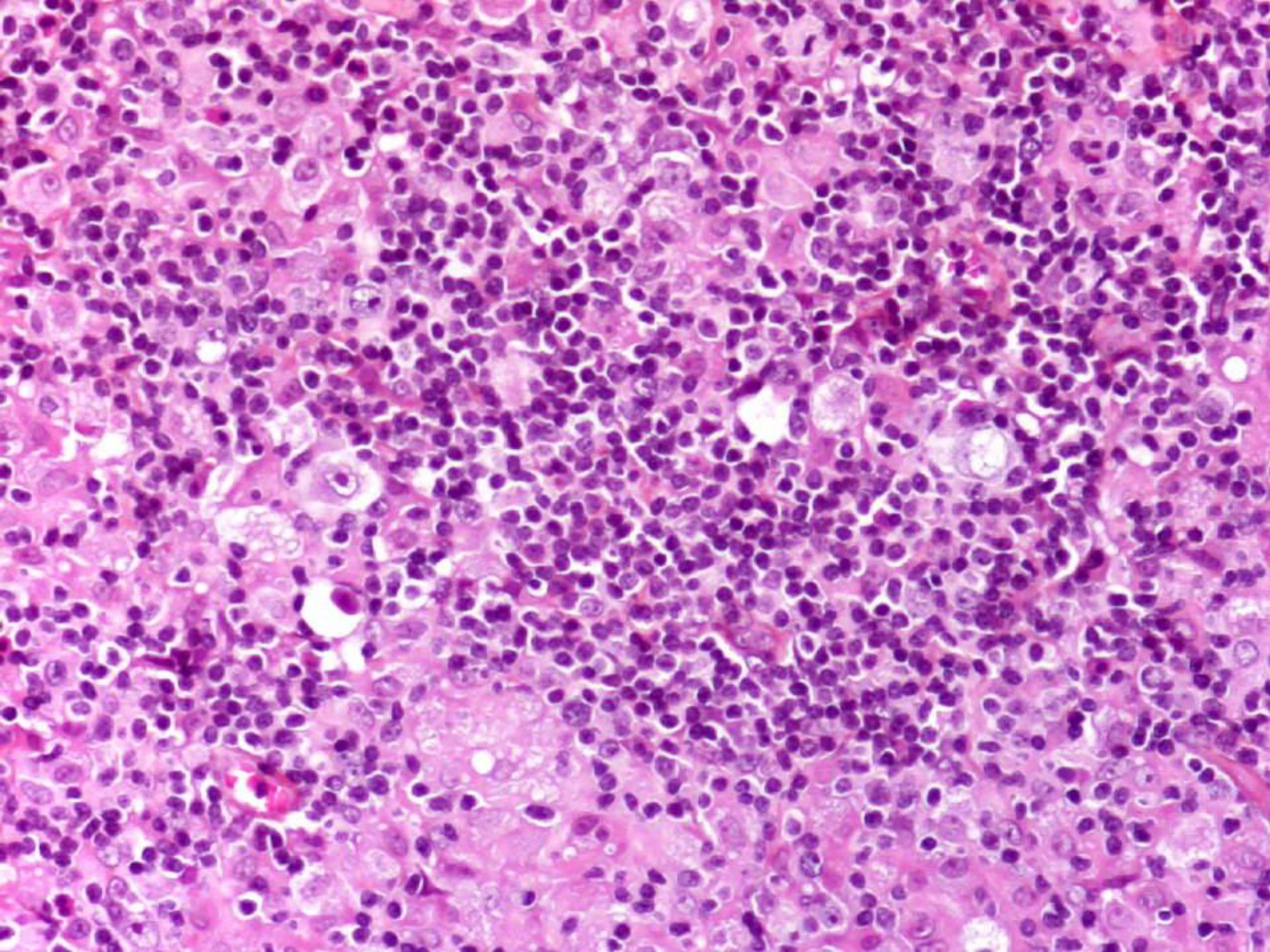
Aspect morphologique de lymphome de Hodgkin classique, type scléronodulaire

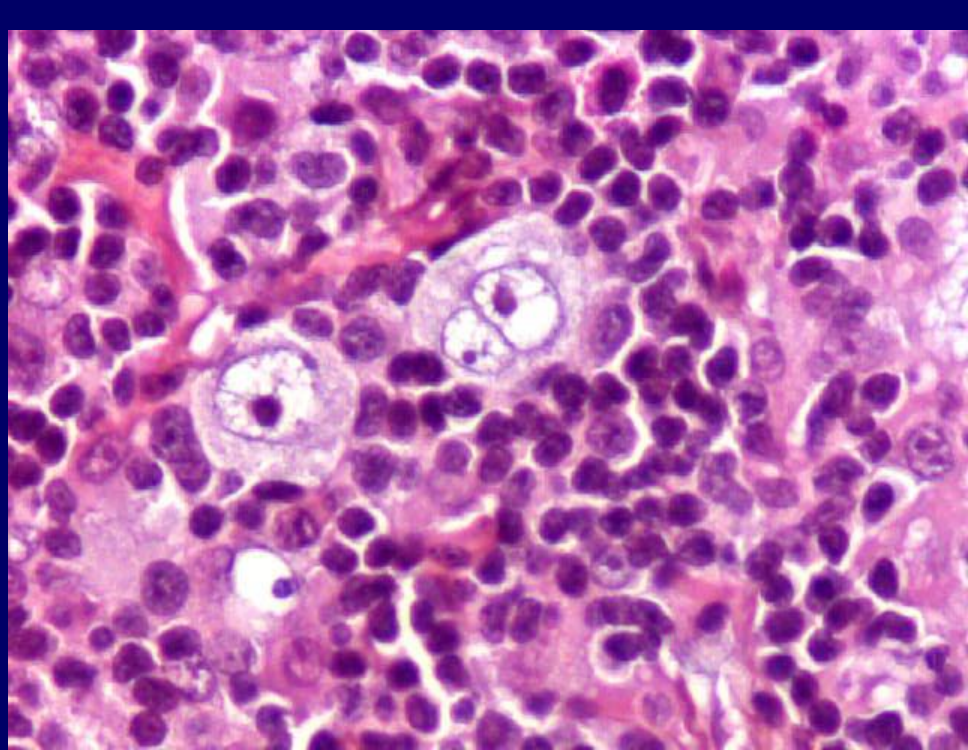
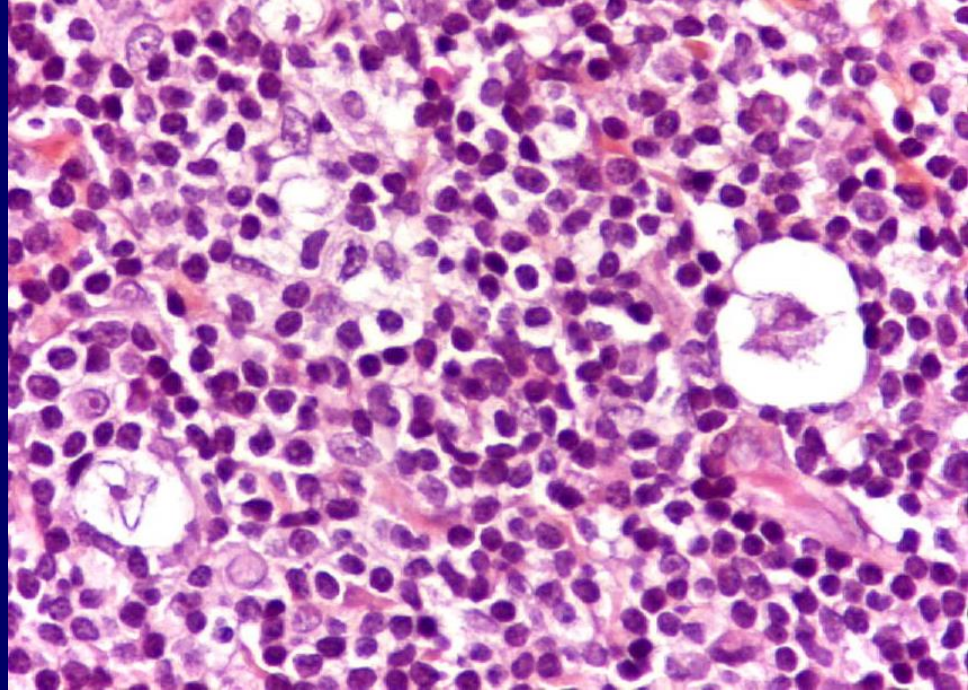
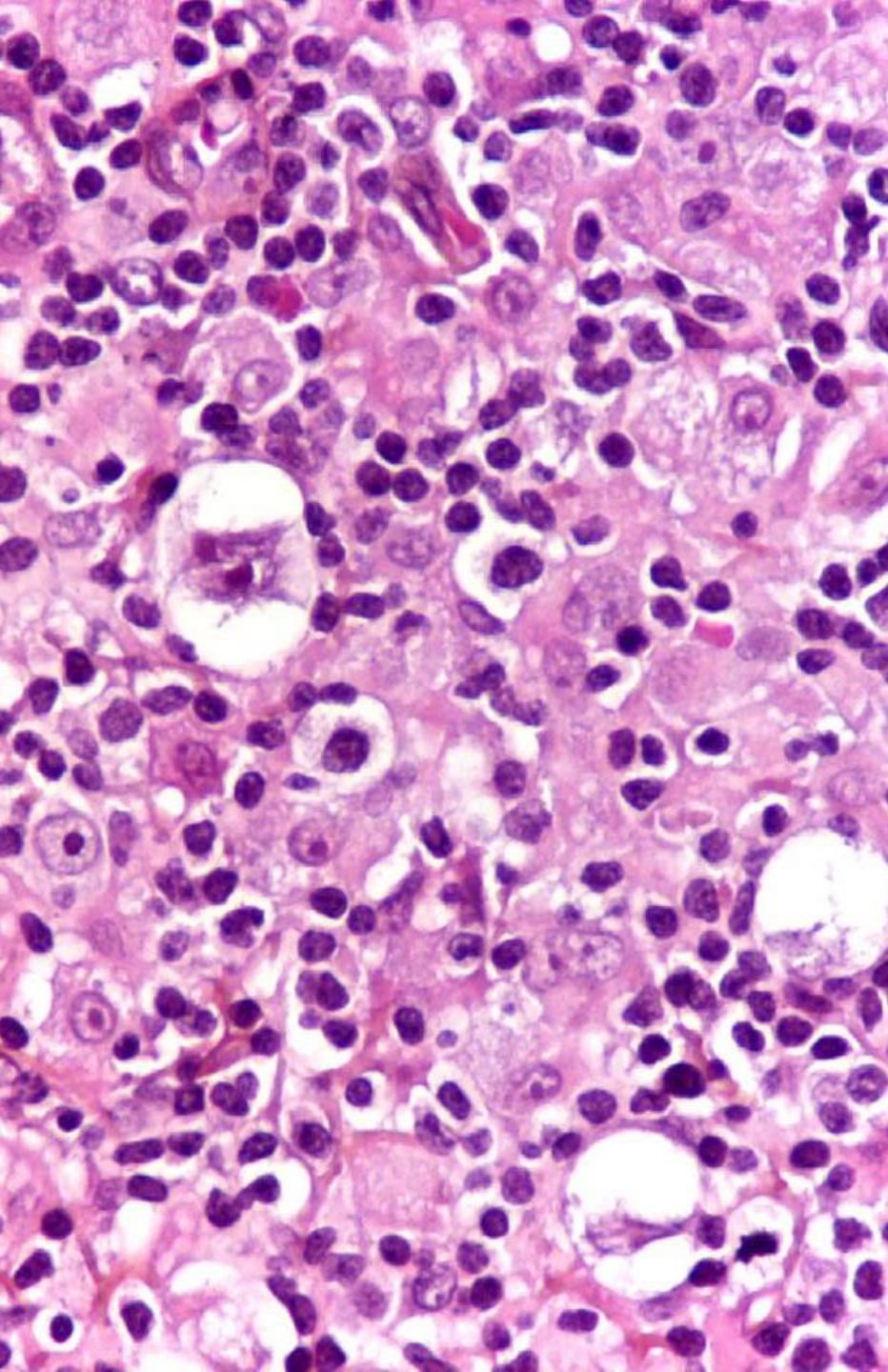
c/ RS : cd30 +, cd15 ?, EBV - , ebna2 - et paraissant toutes cd20 +

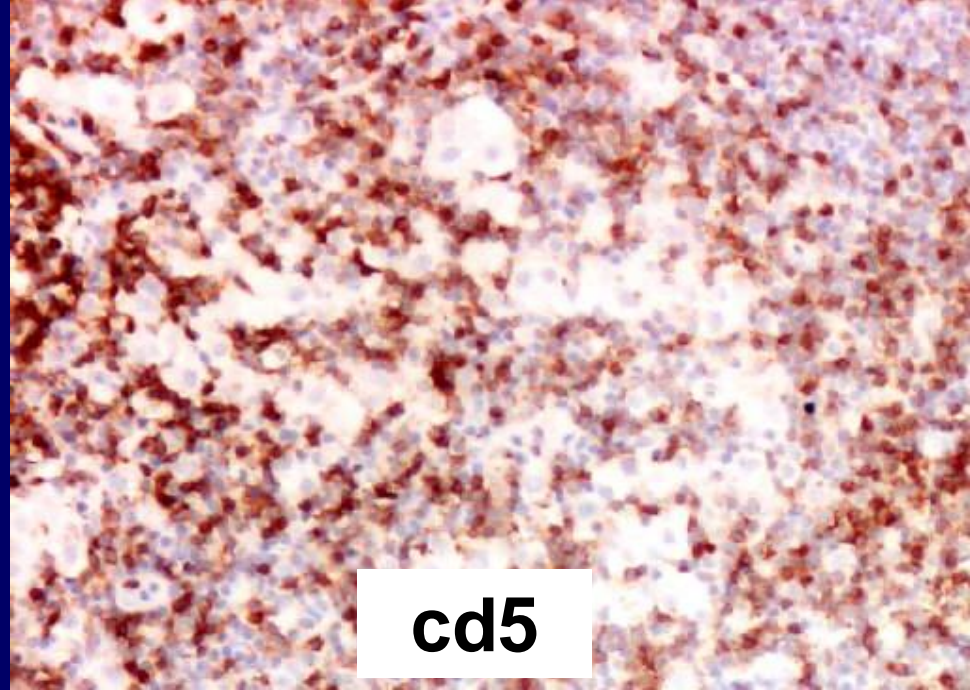
(DLBCL peu probable)

Avis Pr De mascarel

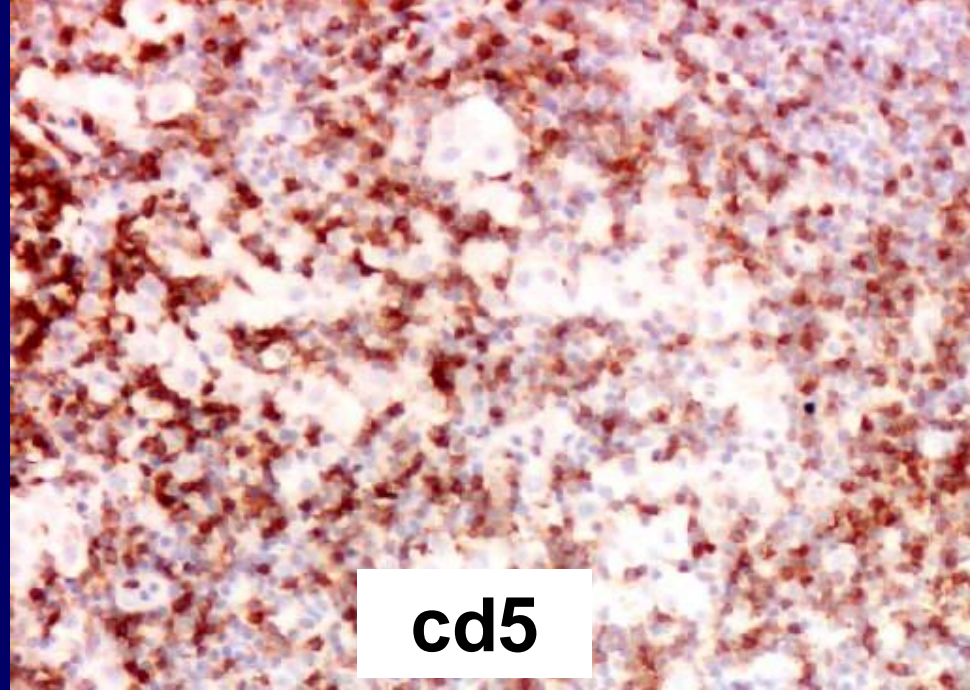
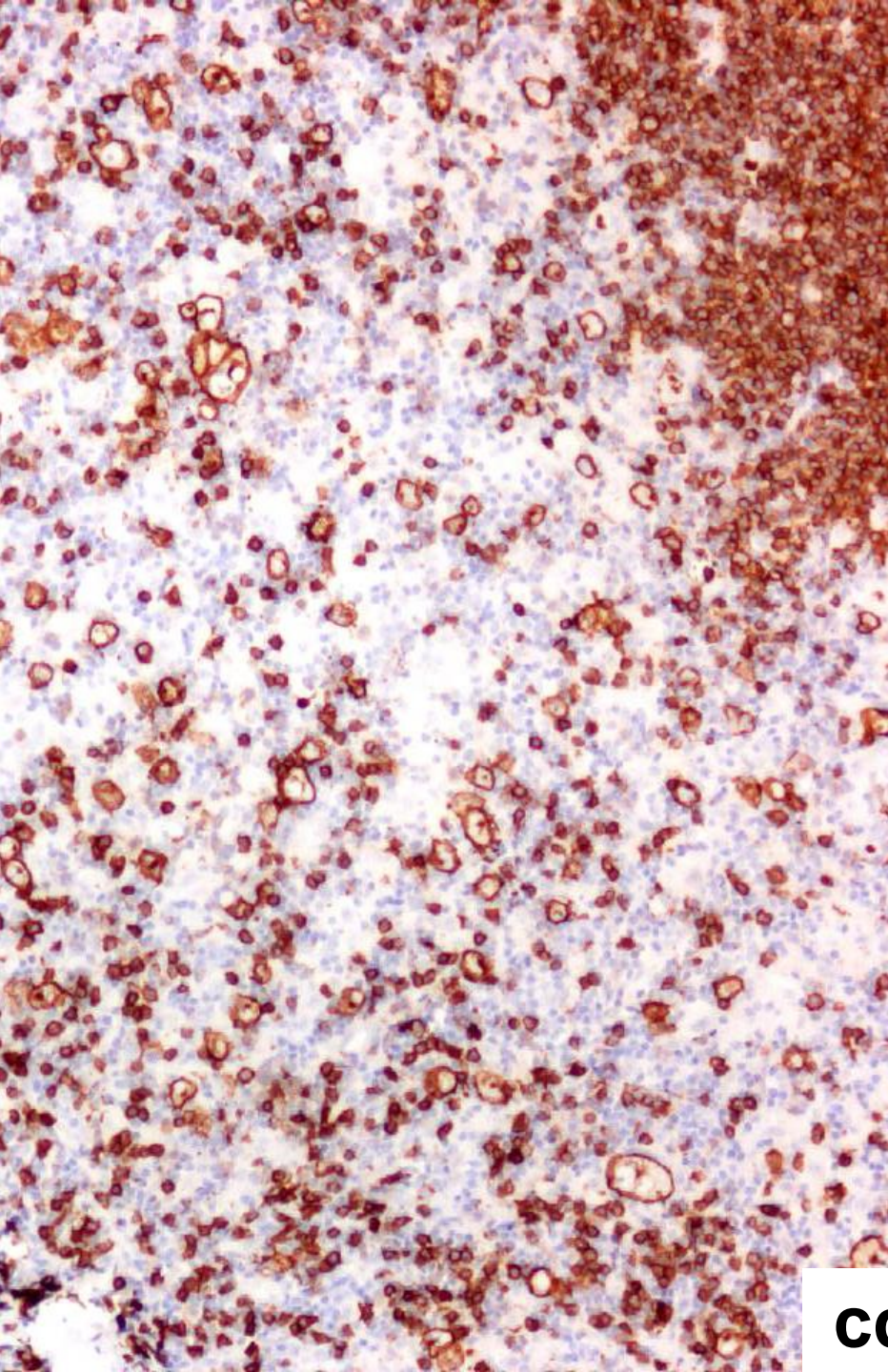




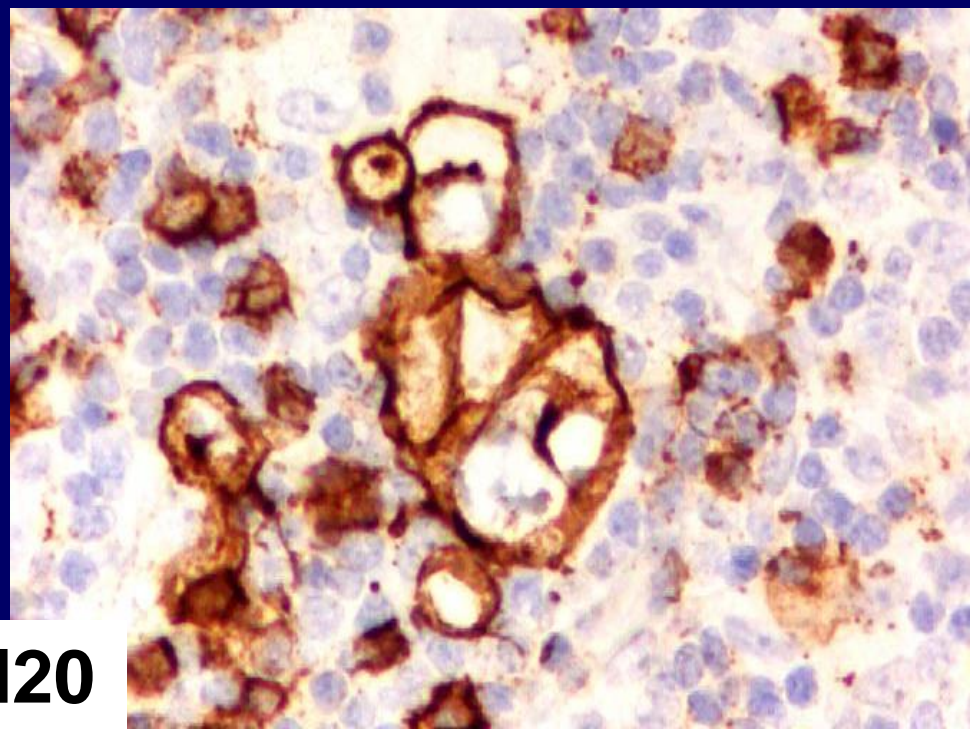




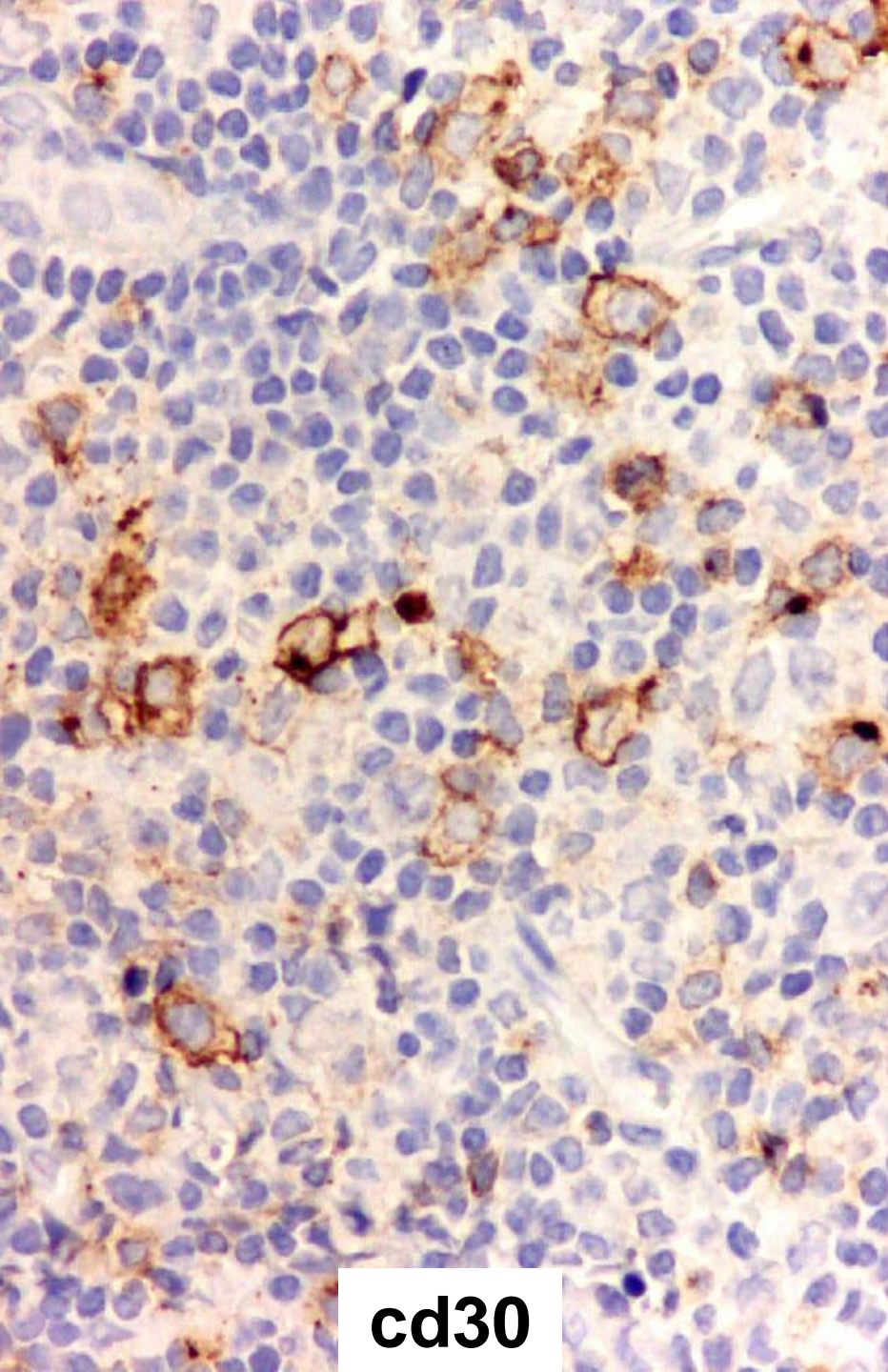
cd5



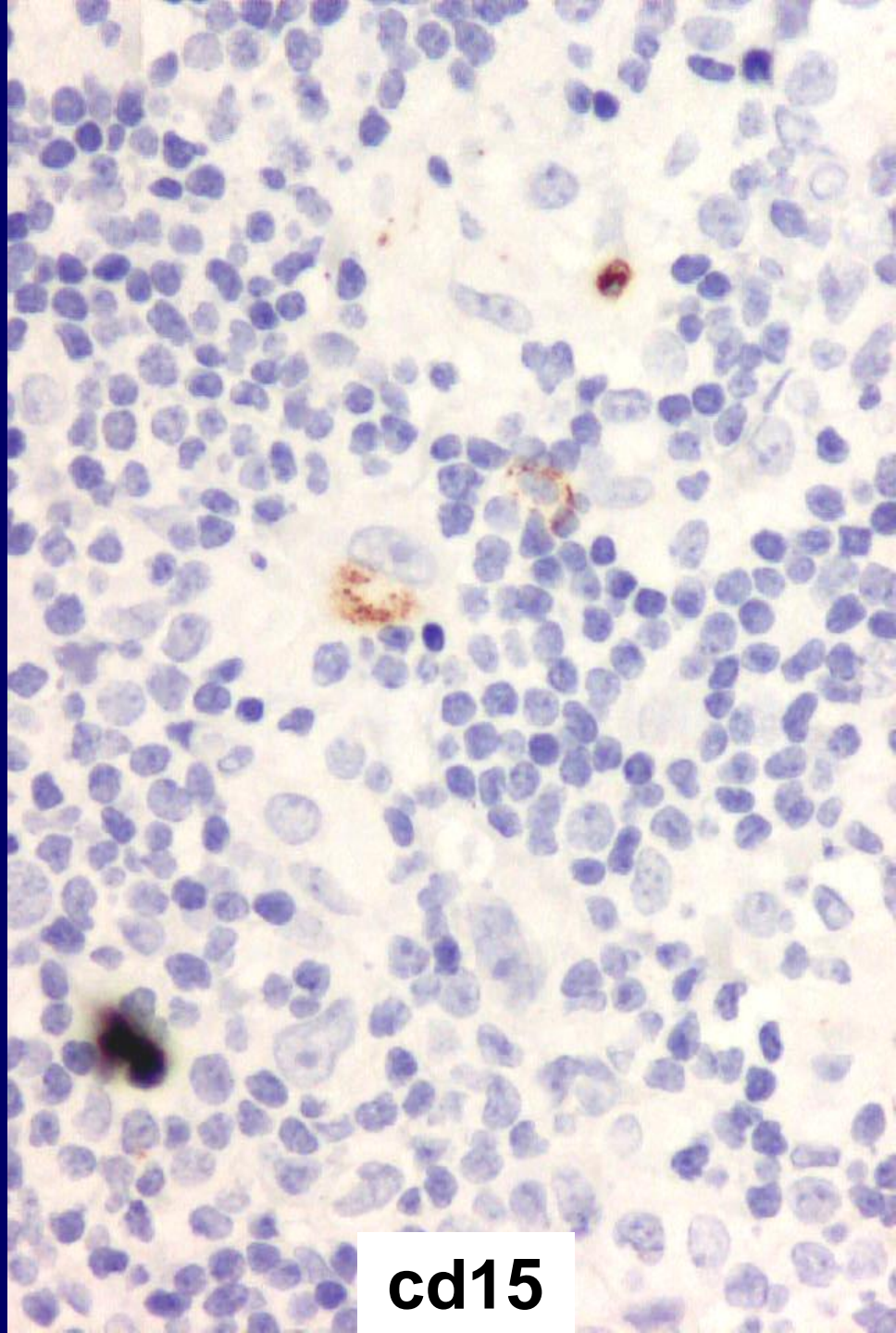
cd5



cd20



cd30



cd15

Diagnostic retenu par Pr De Mascarel

Aspect morphologique de lymphome de
Hodgkin classique, type scléronodulaire
c/ RS : cd30 +, cd15 ?, EBV - , ebna2 - et
paraissant toutes cd20 +

(DLBCL peu probable)

