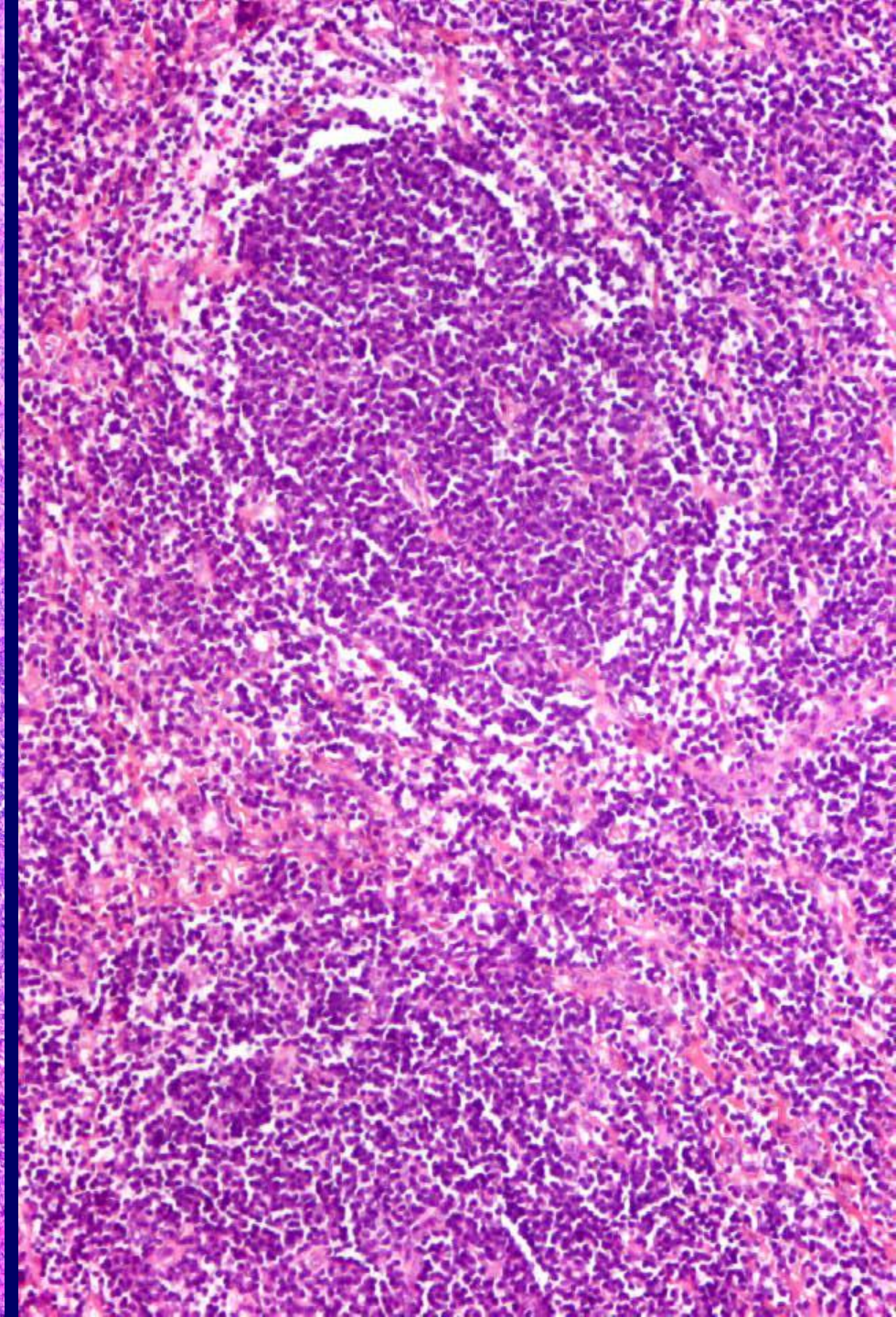
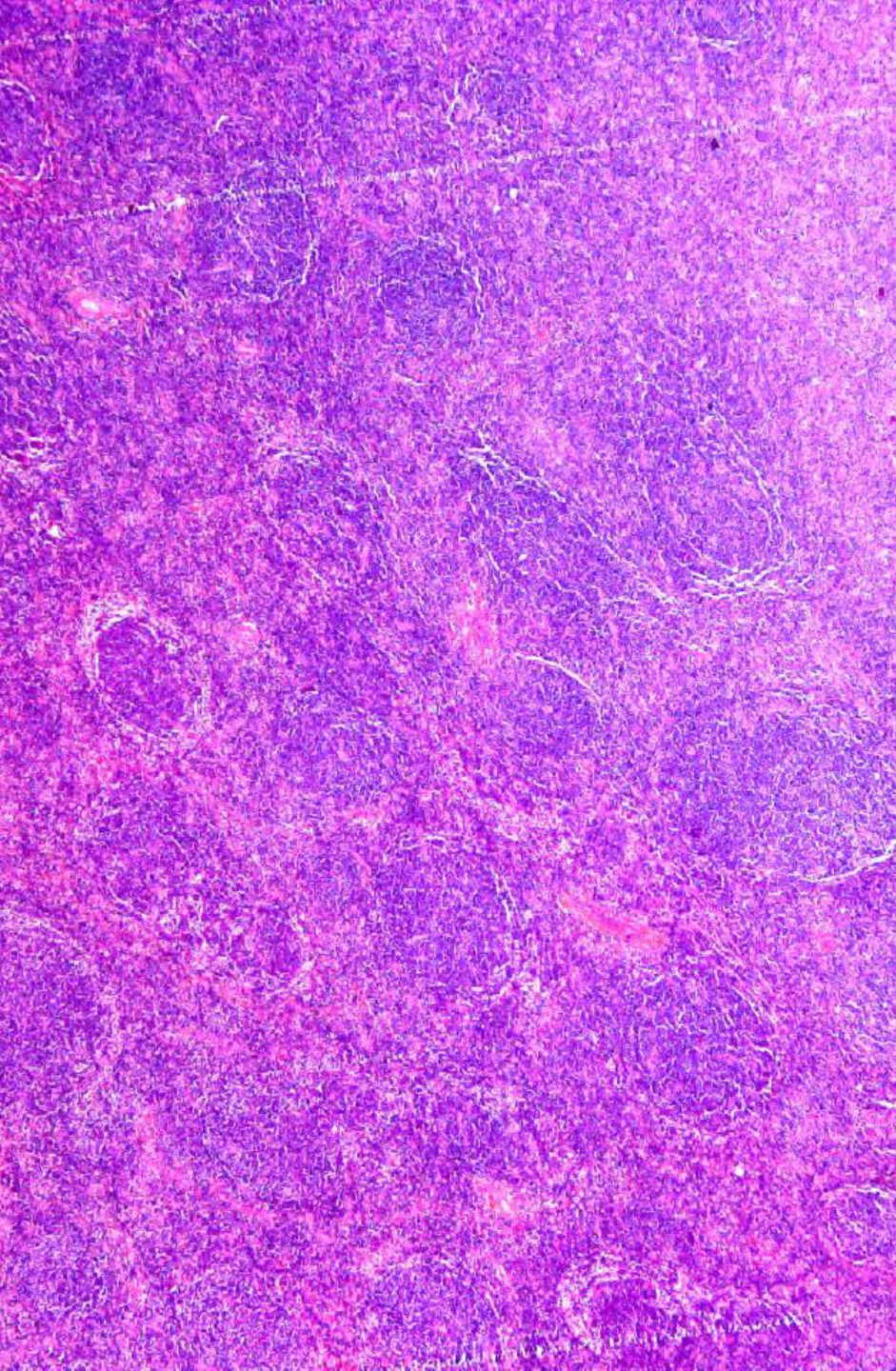


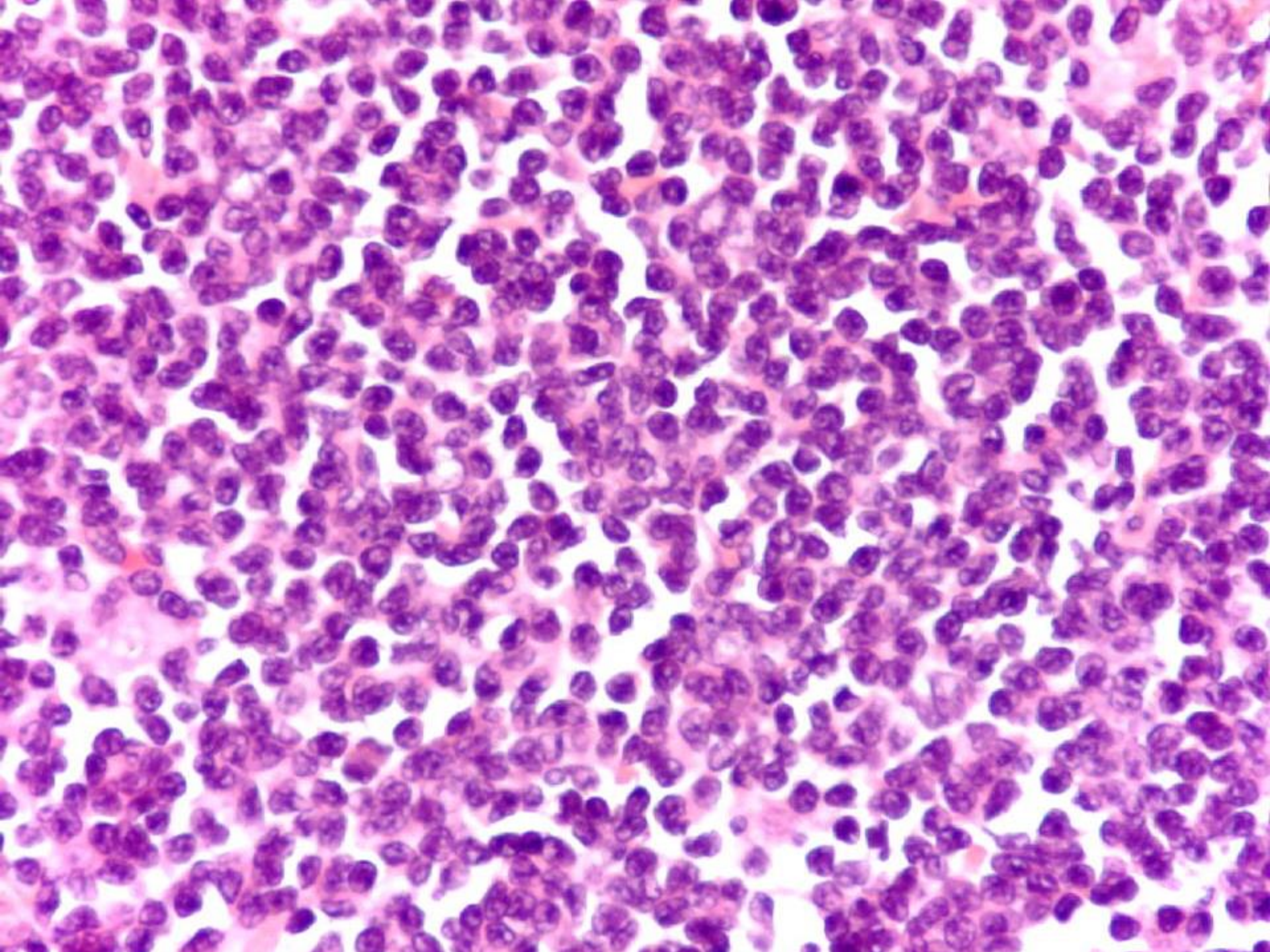
N° 8

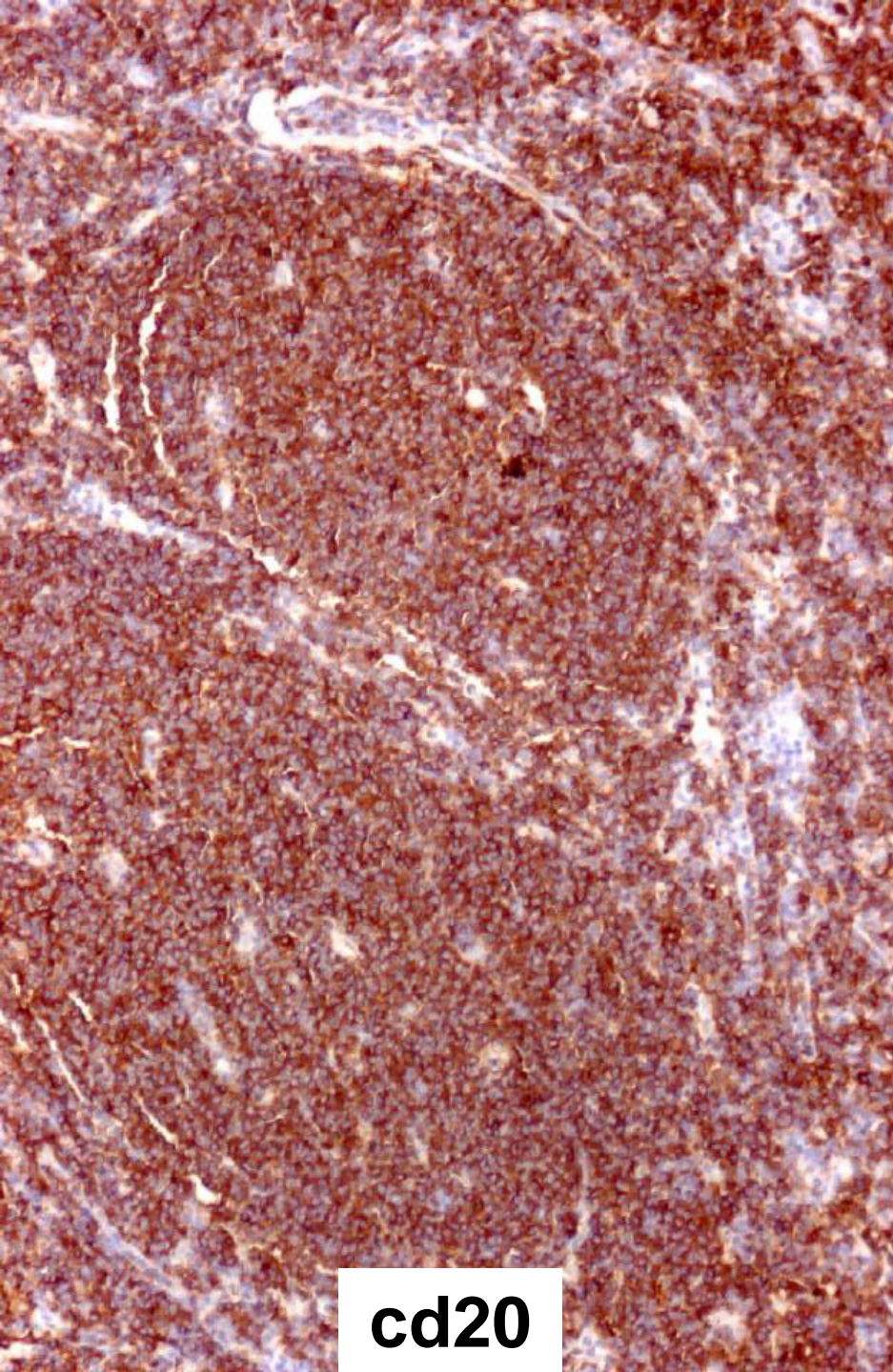
Maroc

- **Homme 51 ans**
- **Polyadénopathies**

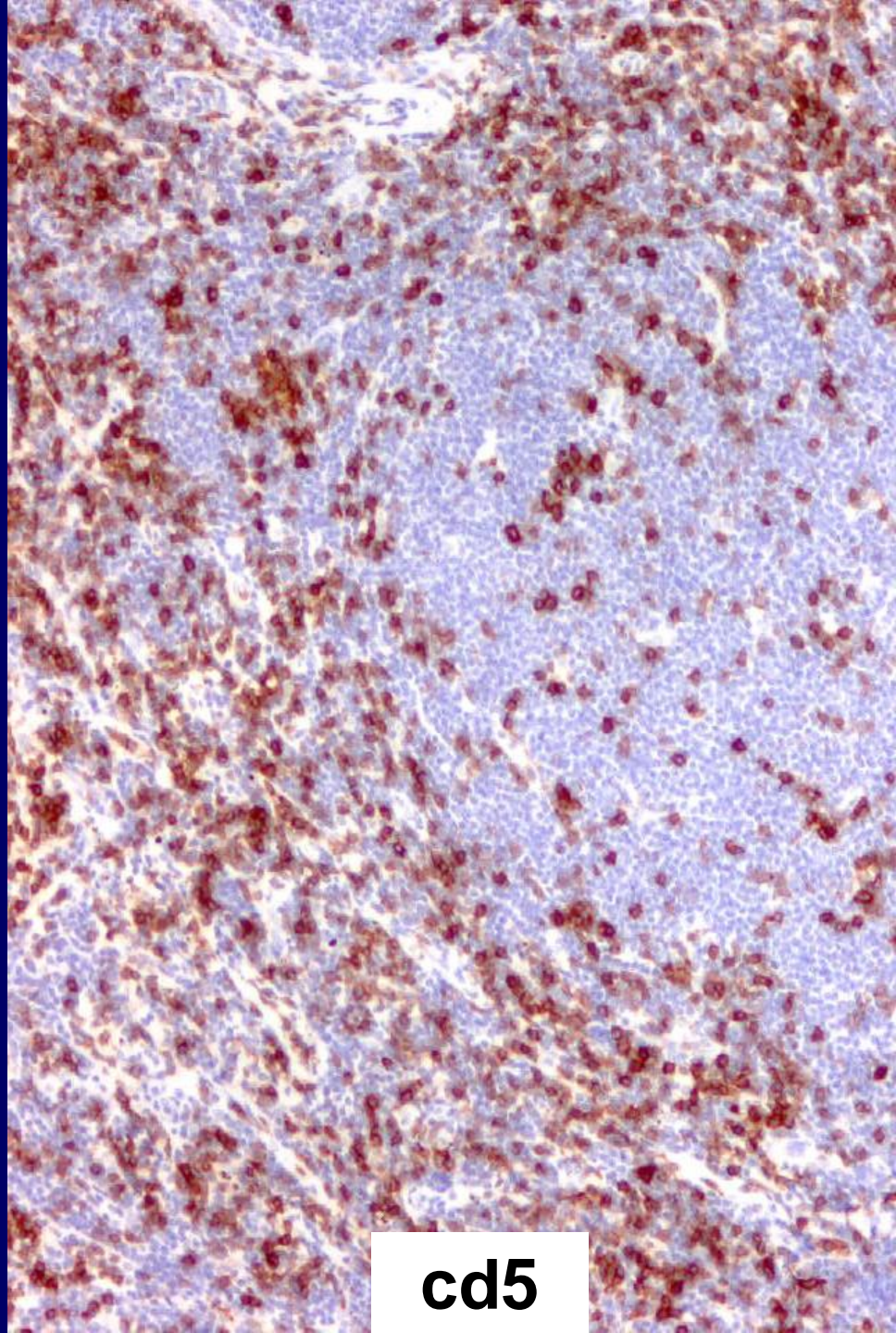
- **Blocs : 10137 /06, 3103/07**



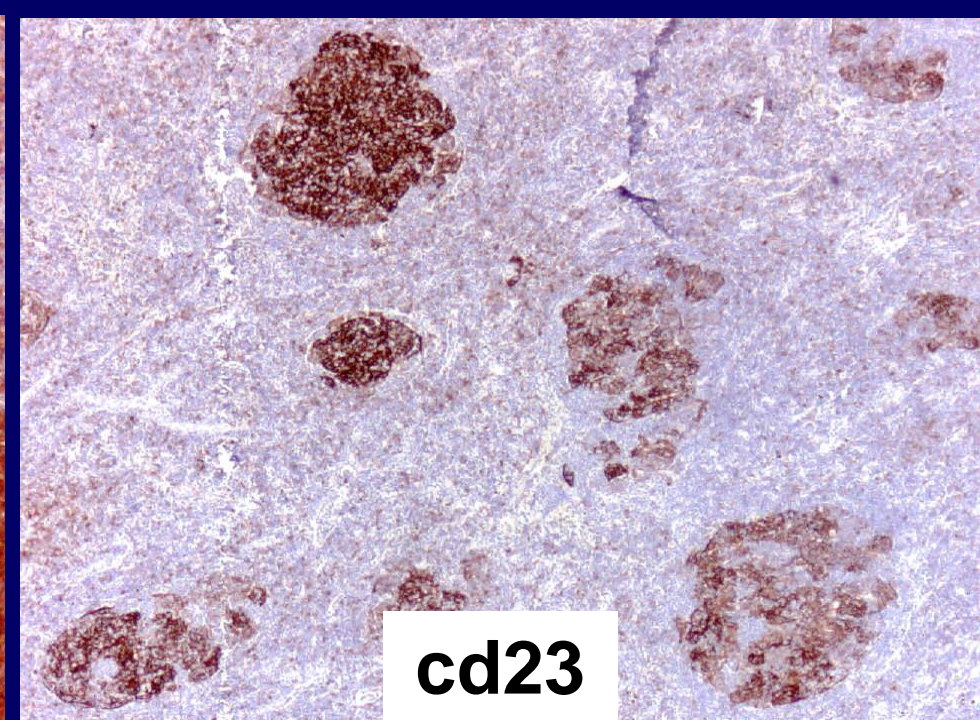
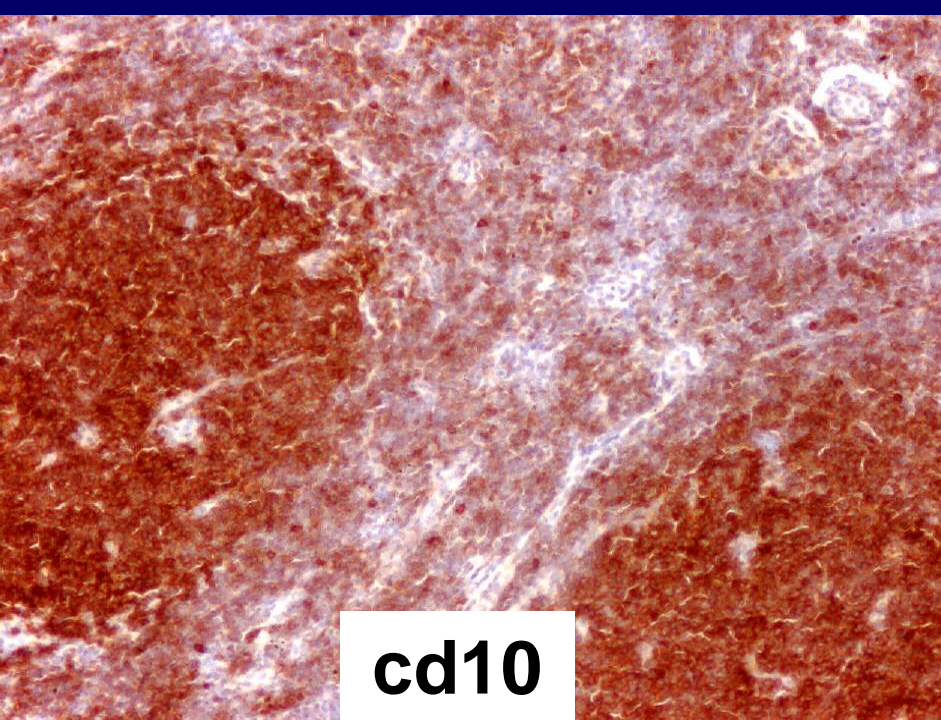
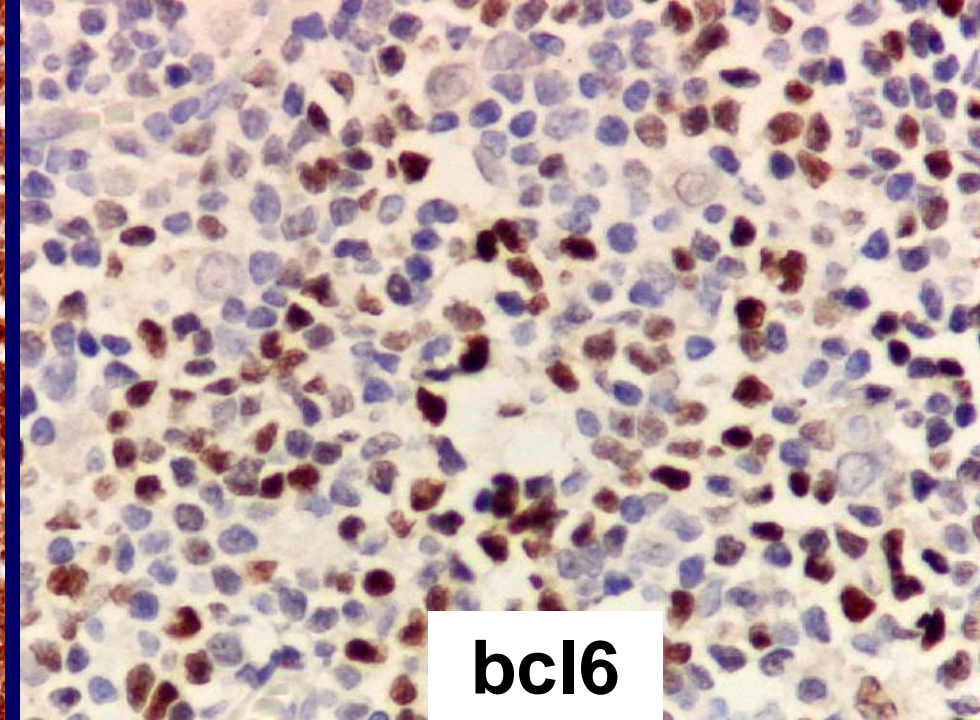
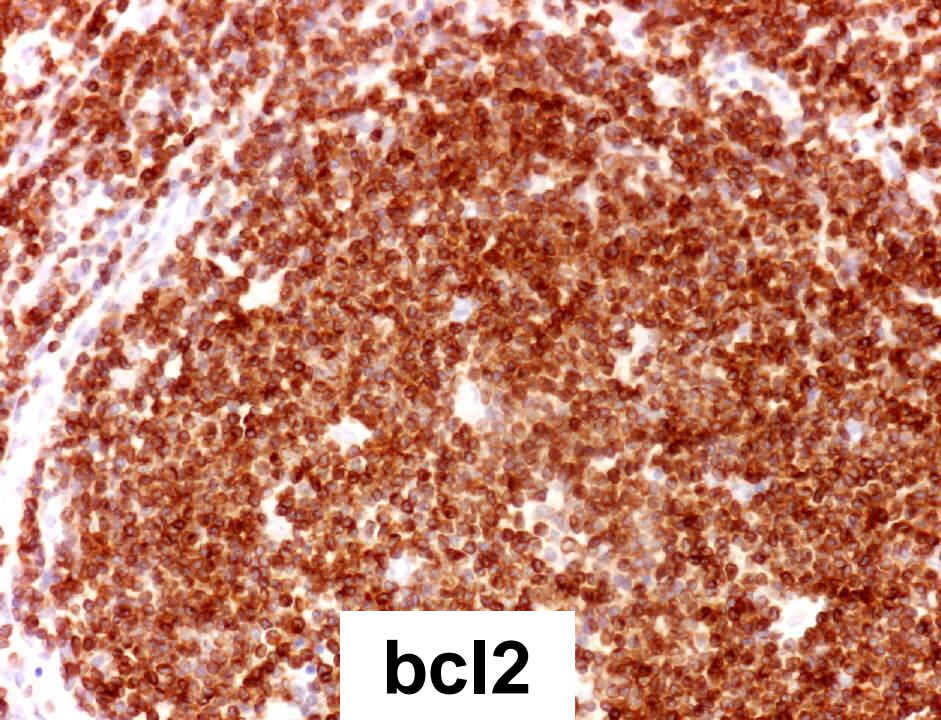




cd20



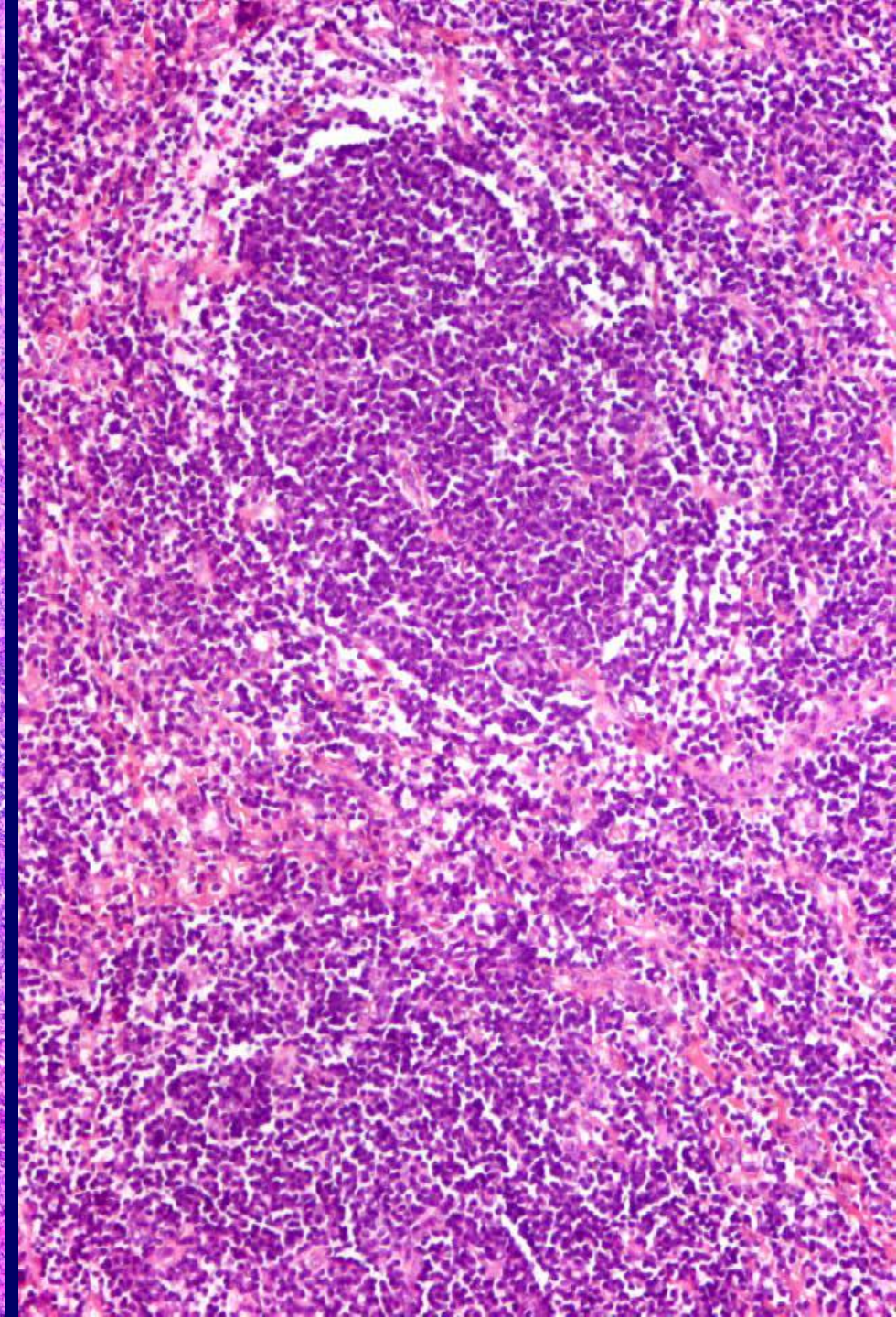
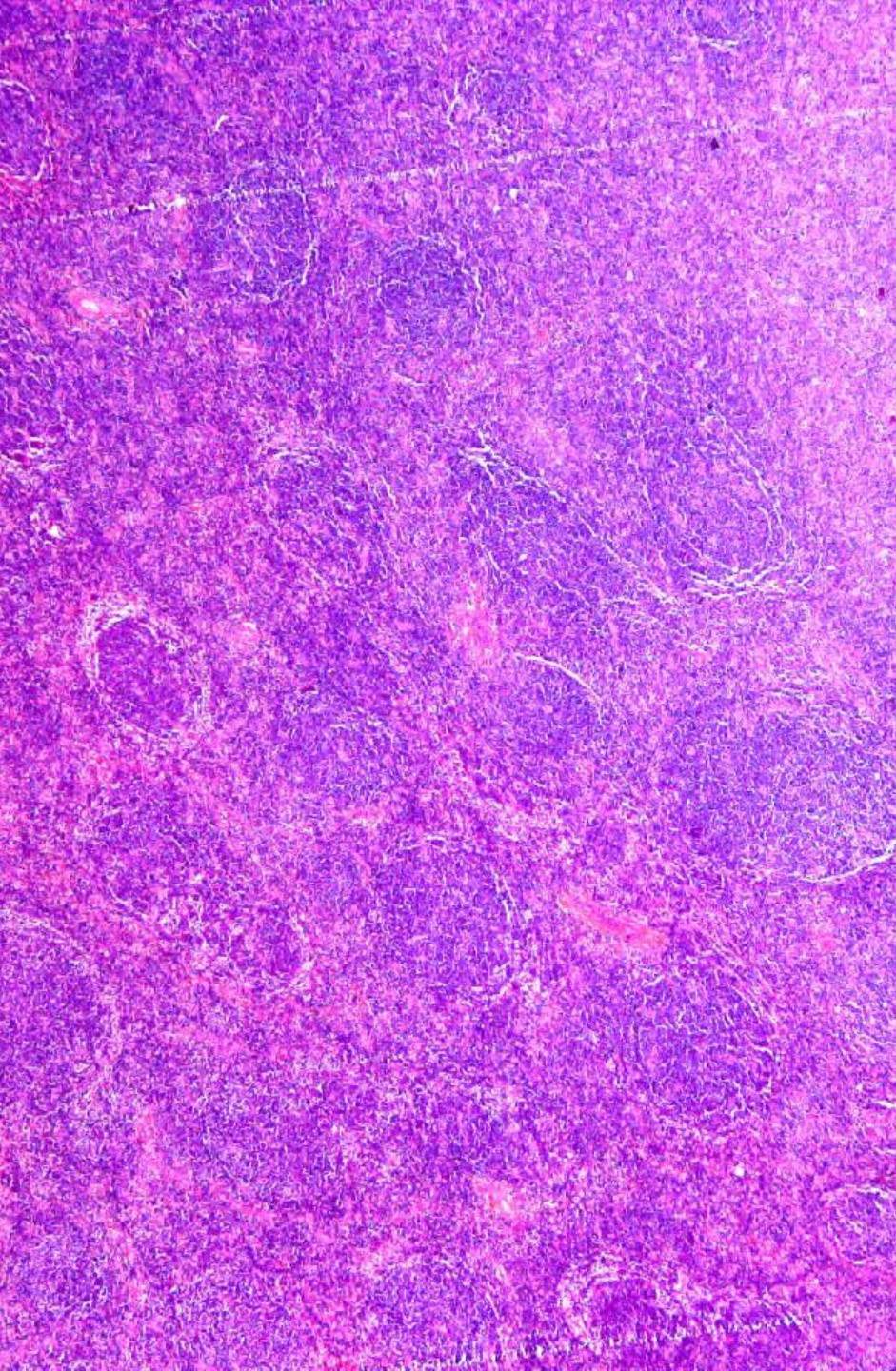
cd5

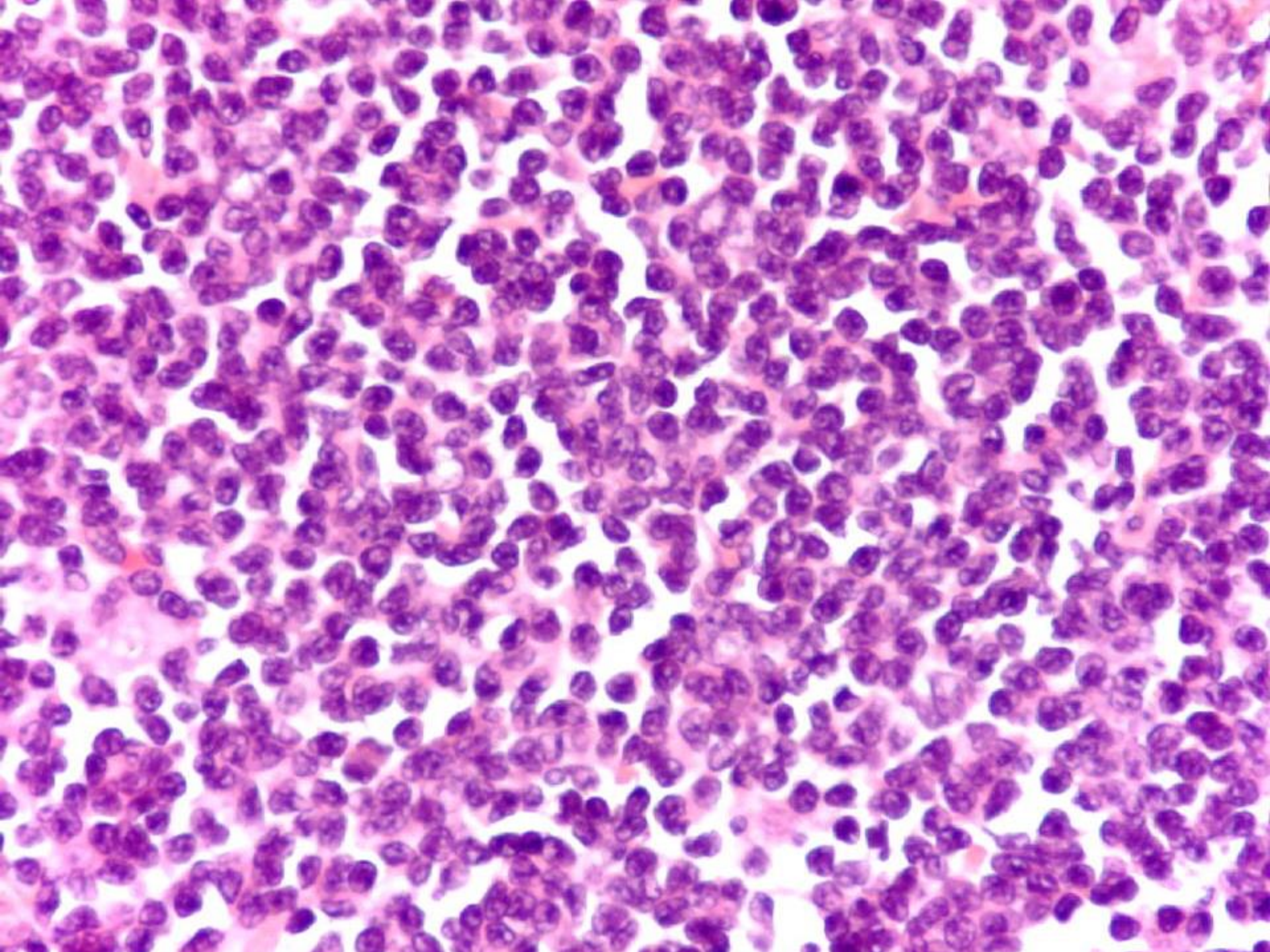


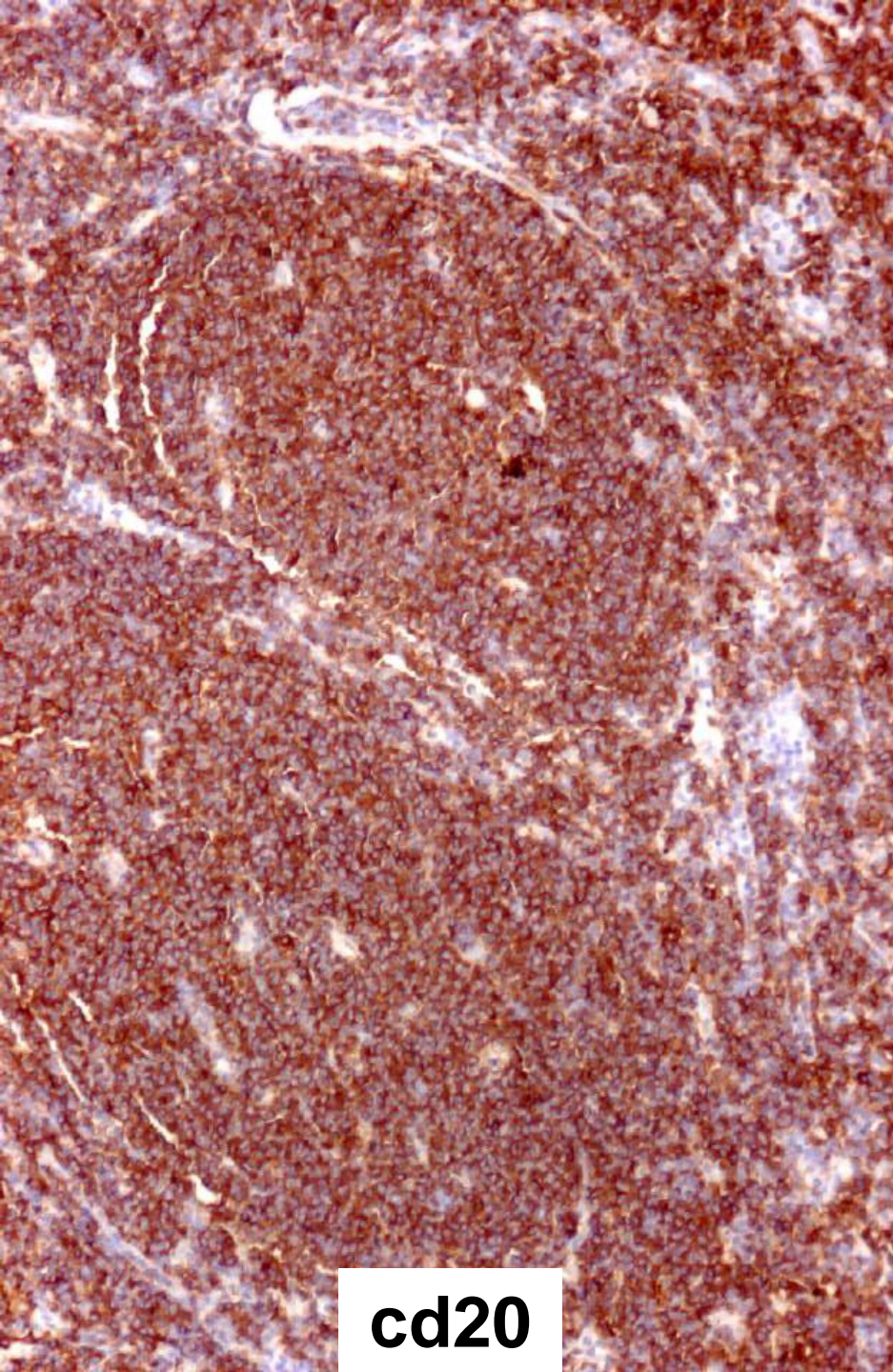
N° 8

Lymphome folliculaire grade 1 (OMS)

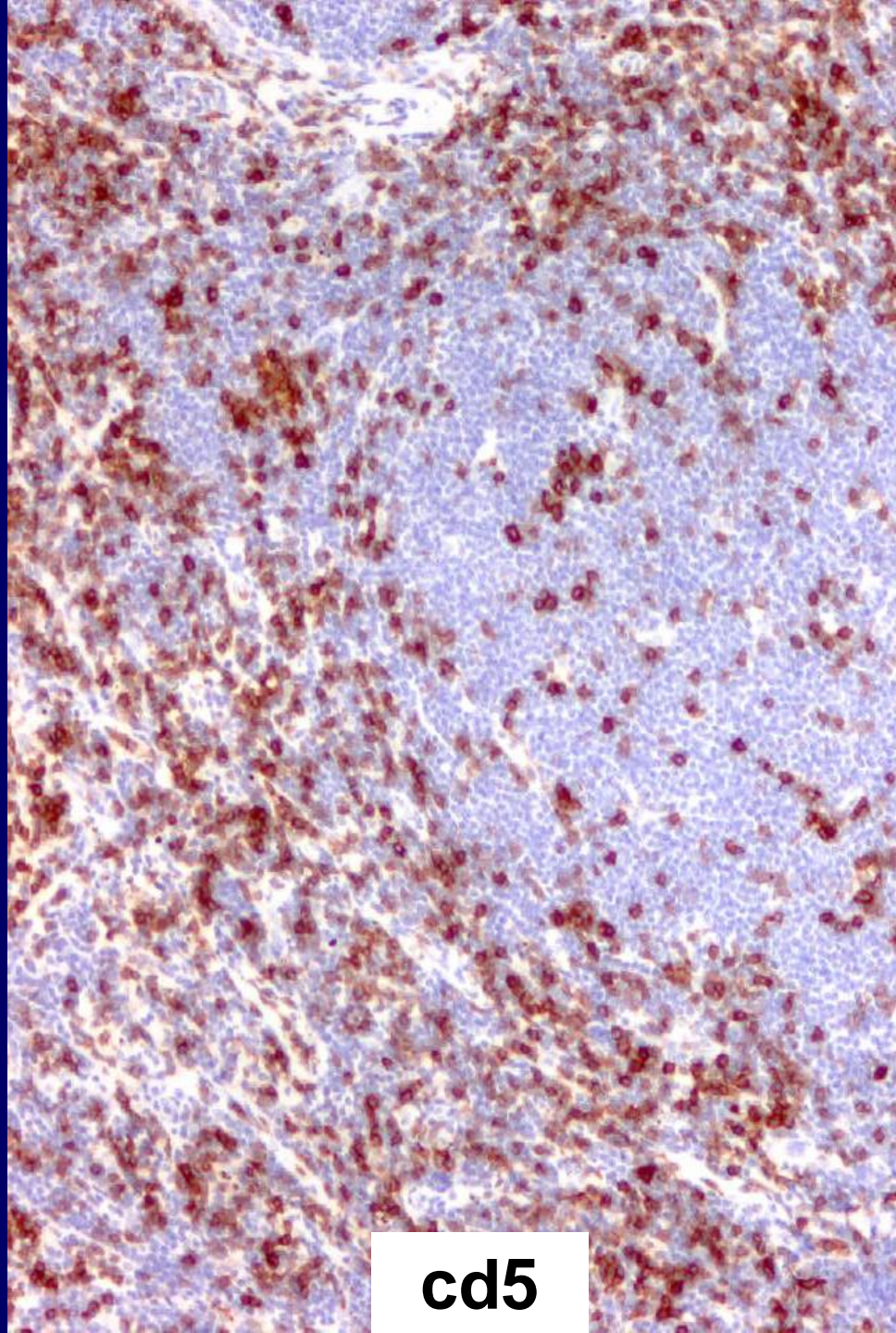
Avis Pr De mascarel



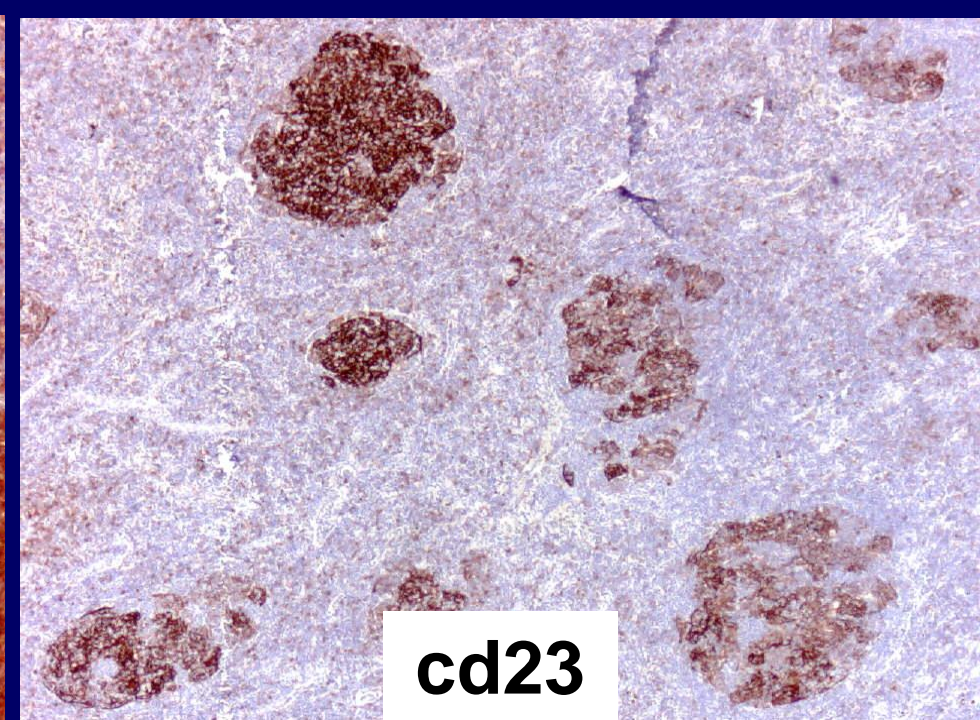
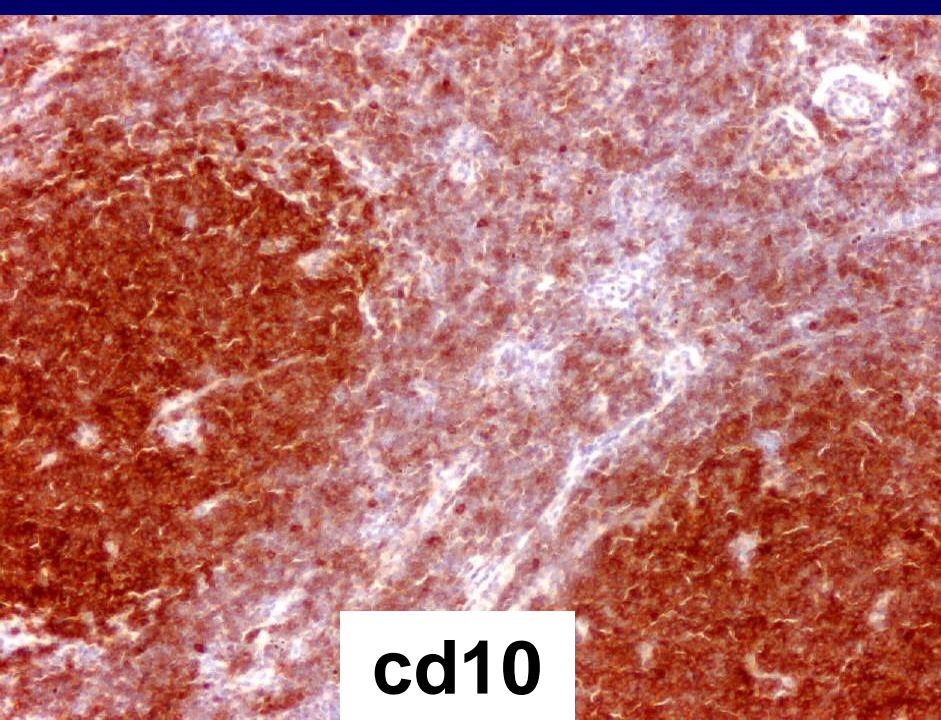
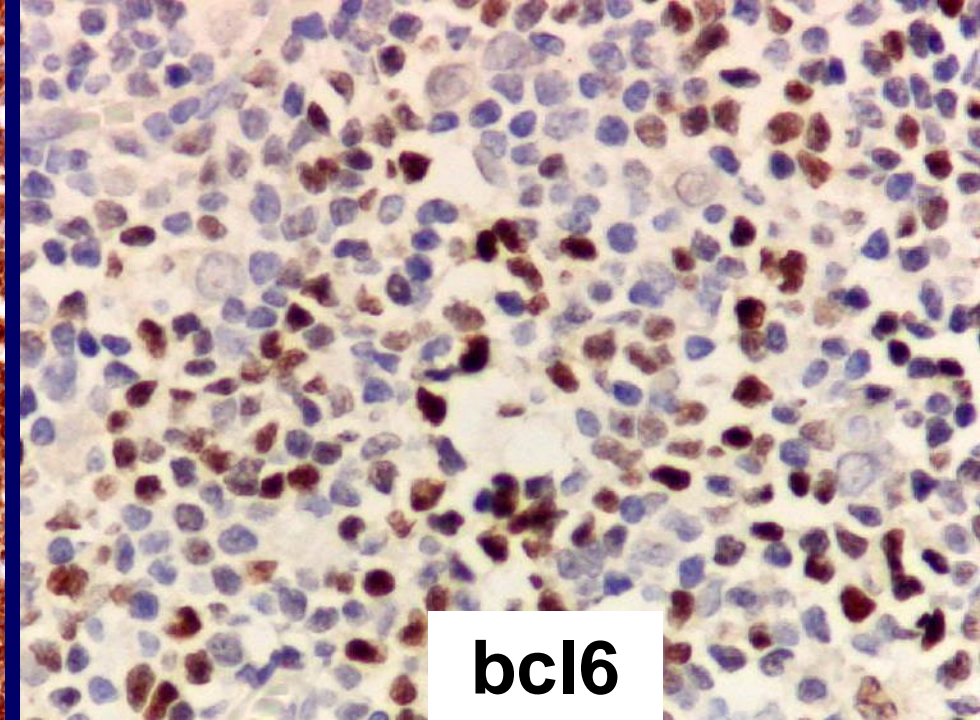
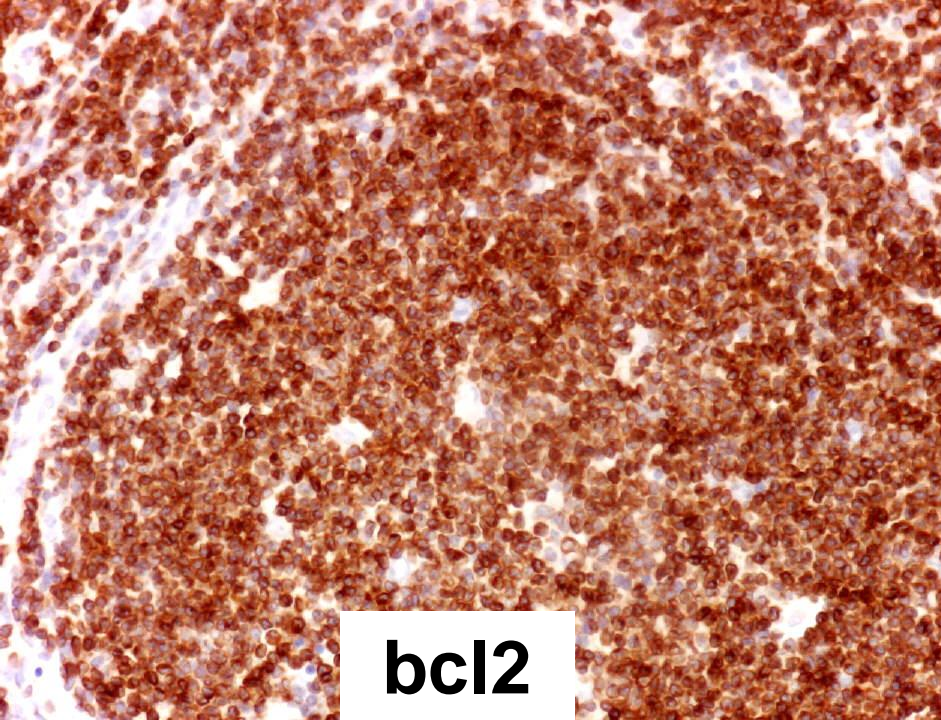




cd20



cd5



Diagnostic retenu par Pr De Mascarel

Lymphome folliculaire grade 1 (OMS)